
SYMPTOMATIC BILATERAL CHOROIDAL METASTASIS FROM BREAST CANCER AS FIRST CLINICAL SIGN OF ADVANCED METASTATIC TUMOR DISEASE 31 YEARS AFTER DIAGNOSIS

KESTELYN PA*, LIBBRECHT L**, DUPREZ F***, COCQUYT V****, VAN AKEN E*

ABSTRACT

We report a 62-year-old caucasian woman with bilateral choroidal metastases as only clinical presenting sign of advanced metastatic tumour disease. She presented with decreased vision in the left eye since 5 days. She was treated for breast cancer 31 years before. Fundoscopy and ultrasound analysis showed a large choroidal metastasis in the left eye and one asymptomatic lesion in the right eye. Systemic screening revealed multiple lung and bone metastases. Health practitioners should be aware that choroidal metastasis from breast carcinoma can present throughout life. Small asymptomatic lesions may be detected that still can be treated effectively.

KEYWORDS

Choroidal metastasis; breast cancer; ultrasound analysis; radiotherapy; asymptomatic lesion

.....

* *Department of Ophthalmology;*
** *Department of Pathology,*
*** *Department of Radiotherapy;*
**** *Department of Oncology, Ghent University Hospital, De Pintelaan 185, B-9000 Ghent, Belgium*

Submitted: Sep 10, 2011
Accepted: Jan 27, 2012

INTRODUCTION

The most common sites of metastasis of breast cancer include lung (71%), bone (71%), brain, lymph nodes (67%), liver (62%) and pleura (50%). The incidence of ocular metastasis from breast cancer changes from 9%-37% depending on the source of the study (1-2). Choroidal metastasis represents the smallest detectable lesion of systemic dissemination of breast cancer and is detected at a median of 3 years after diagnosis of the primary tumor.

Breast carcinoma metastasises to the eye more frequently than is clinically recognised. The incidence is perhaps not appreciated, either because of the more common involvement and consequences of spread to major organs (lung, liver, bone) or because a number of eye lesions are small and asymptomatic. Breast and lung cancers represent more than two thirds of the primary tumor sites in patients with choroidal metastases (3).

Intraocular metastasis is the most common intraocular malignant tumor of the eye. Only in a minority of patients symptomatic choroidal metastasis are the first sign of advanced systemic metastatic disease. Median interval from diagnosis to symptomatic choroidal metastasis in large series of women with a former history of breast cancer is reported as 42 or 48 months (3-4). We present a case with unilateral symptoms of blurred vision but bilateral choroidal

metastasis 31 years after the initial diagnosis of breast cancer. Blurred vision was the patients' only presenting sign of systemic widespread metastatic disease.

CASE PRESENTATION

A 62-year-old caucasian woman presented in our department with decreased vision in the left eye since 5 days. Visual acuity in that eye was reduced to 20/400 and was still 20/20 in the right eye. She was treated for breast cancer 31 years before with Halsted mastectomy and axillary lymph node dissection. The primary tumor was defined as stage IIA. Pathology of the primary tumor showed a moderately differentiated ductal adenocarcinoma with a diameter of 1.5 cm. No lymph nodes were removed. A locoregional relapse 12 years later was treated successfully with adjuvant radiotherapy and Tamoxifen® for 5 years. Follow-up for the next 14 years was uneventful. Fundoscopy and ultrasound analysis showed a large choroidal metastasis (5.9 mm height) with exudative retinal detachment in the posterior pole of the left eye and one yellow asymptomatic lesion in the right eye (fig. 1). CT-scan confirmed metastatic involvement of both eyes (fig. 2). External beam radiotherapy was initiated within 24 hours with a thermoplastic 3-points mask for patient immobilization using 2 opposing latero-lateral fields of 5 MV photon beams. The patient was treated on a linear accelerator (Elekta SL75, Crawley, UK). Lens sparing was not possible

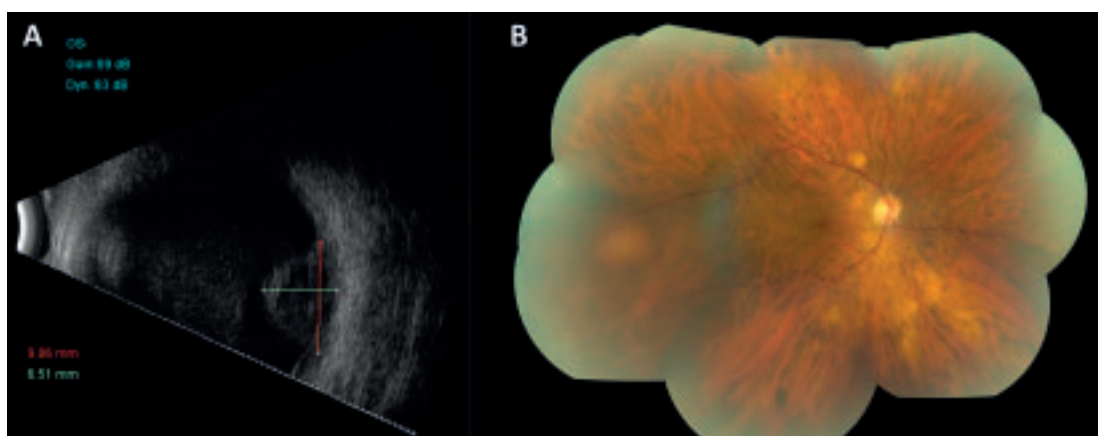


Fig. 1: (a) B-scan ultrasound of a metastatic lesion with irregular internal structure in the posterior pole in the left eye. (b) Fundus photography of one yellow asymptomatic lesion in the right eye at the 9 o'clock position.

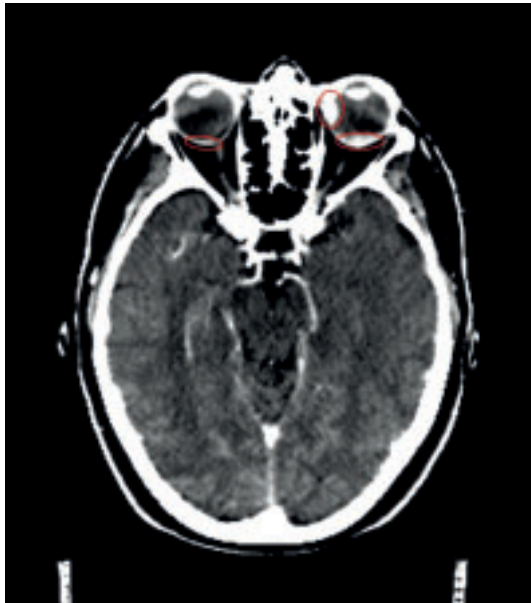


Fig. 2: Computed tomography scan before external beam radiotherapy showing large choroidal involvement of the left eye and also the asymptomatic lesion in the right eye.

due to location of the metastases. In order not to overdose the lacrimal glands, dose prescription was 30 Gy in 15 fractions of 2 Gy, delivered over a period of 3 weeks. Manual dose calculation was done for the first fraction, in order to be able to start treatment as soon as possible. From the second fraction, treatment was based on planning computed tomography (CT). The patients' position was verified after the first and second fraction using portal films. Meanwhile systemic screening revealed multiple lung and bone metastases. Ultrasound of the patients' abdomen did not show any malignancy.

Oral treatment with Letrozole (Femara®) was initiated as the receptor status was still unknown during radiotherapy. A transthoracic lung biopsy of lung metastasis revealed an adenocarcinoma (fig. 3). Biopsy of the lung metastasis showed small fragments of lung parenchyma with infiltration by a group of atypical cells. Tumor cells contained a moderate amount of cytoplasm and moderately pleomorphic nuclei. Immunohistochemical results of the lung metastasis fit with an adenocarcinoma of the breast: estrogen receptor (ER) was negative, progesteron receptor (PR) was weakly positive, cyto-

keratin 7 (CK7) was strong positive, thyroid transcription factor 1 (TTF1) was negative. The section that was immunostained for human epidermal growth factor receptor 2 (HER2) only contained 1 group of 10 tumoral cells. Immunohistochemical HER2 score was 1+. There was not enough material to perform FISH.

For the receptor status of the original tumor, we re-examined the original tumor and performed immunohistochemistry for ER, PR and HER2, as such immunohistochemical investigations had not been performed 31 years ago. Unfortunately, the original tumor was kept in Bouin fixation and not in formol. Immunohistochemical results for HER2 were negative; FISH was not possible due to Bouin fixation. HER2-negativity on immunohistochemistry might however also be due to Bouin fixation. Immunohistochemical score for ER: Allred/Quick score 8 = 3 for intensity and 5 for proportion. Immunohistochemical score for PR: Allred/Quick score 3 = 2 for proportion and 1 for intensity. Two weeks after radiotherapy had stopped, the patient experienced again deterioration of her vision in the left eye because of a vitreal haemorrhage.

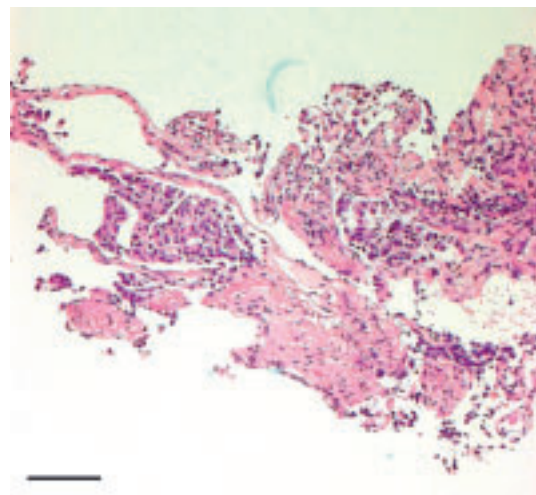


Fig. 3: Hematoxylin and eosin staining of a transthoracic lung biopsy of lung metastasis fitting with adenocarcinoma of the breast (scale bar 100 microns).

DISCUSSION

The choroid is the most common site for metastases related to the eye (81%) and occurs via the haematogenous route. Another common site for breast cancer metastasis is the brain. Visual symptoms associated with cerebral metastases include visual field defects, seizures and mental and focal motor syndromes (5). Metastases have also been reported in the orbit. Paraneoplastic effects (due to immunological responses against tumour antigens) of breast cancer on the eye are rare. Cancer-associated retinopathy is a rare retinitis pigmentosa-like retinal degeneration that may occur with breast cancer (5).

The only complaint in this patient was unilateral blurred vision since several days. In patients with uveal metastasis, the most common symptoms are indeed blurred vision (88%), floaters in 5%, photopsia in 5% and 7% are asymptomatic. Although uveal metastases are unilateral in the majority of patients (62% of patients), this patient showed lesions in both eyes (6). Ophthalmic manifestations of metastatic breast carcinoma occurs in 5.8% of asymptomatic patients. Because of this small proportion, there is no need for routinely screening for choroidal metastases in asymptomatic patients (7). When however, as in this case, there are symptoms, the patient should have a bilateral thorough ocular examination. Choroidal metastasis occurs in advanced metastatic breast cancer, indicating a grave vital prognosis (4). Using Kaplan-Meier estimates, survival rates of all patients with uveal metastasis from breast cancer was 65% at 1-year, 34% at 3-year and 24% at 5-year follow-up (6).

Radiotherapy is quite effective for control of most uveal metastases. Wiegel et al. are, to our knowledge, the only ones reporting a prospectively followed patient cohort of 50 patients treated with external beam radiotherapy for 65 eyes with choroidal metastases. Recovery, stability of complaints and deterioration were seen in 36%, 50% and 14%, respectively (8). Other published series are mostly retrospective. Rudoler et al. treated 188 patients for 233 eyes in total doses from 30-40 Gy in 2-3 Gy daily fractions and saw 57% increase of visual acuity and 93% of patients without further deteri-

oration (9). Demirci et al. evaluated 129 patients treated with doses ranging from 20-64 Gy in 1.5 to 36 Gy daily fractions with 64% regression, 18% stable ocular disease (6).

The technique of external beam radiotherapy is most often used and is delivered over a 3- to 4-week period in an outpatient setting. The management of uveal metastasis depends on both the patient's systemic condition and the ocular condition (10). If there is evidence of systemic metastatic disease, then treatment of the nonocular and ocular metastatic tumors consists of chemotherapy, hormone therapy, immunotherapy, multiple-site radiotherapy, or observation. If there is no evidence of systemic involvement, then whole-eye treatment with chemotherapy, hormone therapy, immunotherapy, radiotherapy, or enucleation is considered. Inactive uveal metastases are managed by periodic observation, but active uveal metastases often produce visual loss, secondary glaucoma, and pain, therefore, treatment is usually indicated. Known side effects of radiotherapy are cataract, retinopathy and papillopathy, but these are uncommon because many patients do not survive long enough to experience these long-term problems.

In this patient, there was a discordance in ER status between the primary tumor (positive) and the metastasis (negative). Accordingly, she was given Tamoxifen in 1991, when treating the local relapse. The HER2 status of the primary tumor could be falsely negative due to Bouin fixation. Discordance in expression measurements for ER, PR, and HER2 between primary and recurrent tumors in patients with recurrent breast cancer have a negative effect on prognosis. Concordance of quantitative hormone receptor measurements between primary and recurrent tumors is modestly consistent with suboptimal reproducibility of measurement methods, particularly for immunohistochemistry. Discordant cases have poor survival probably due to inappropriate use of targeted therapies (11). However, biological change in clinical phenotype cannot be completely excluded

CONCLUSION

It is very rare that metastatic disease presents as bilateral choroidal metastasis as long as 31 years after the initial diagnosis of breast cancer was made. Health practitioners should be aware that blurred vision due to choroidal metastasis from breast carcinoma can present throughout life. Although asymptomatic patients require no routinely ophthalmic screening, careful examination of both eyes in symptomatic patients is mandatory. Small asymptomatic lesions may be revealed that still can be treated effectively by external beam radiotherapy and ensure patients of a good visual acuity.

CONSENT

Written informed consent was obtained from the patient for publication of this case report and accompanying images. A copy of the written consent is available for review by the Editor-in-Chief of this journal.

REFERENCES

- (1) Bloch RS, Gartner S – The incidence of ocular metastatic carcinoma. *Arch Ophthalmol* 1971, 85:673-675.
- (2) Mewis L, young SE – Breast carcinoma metastatic to the eye: Analysis of 67 patients. *Ophthalmology* 1982, 89:147-151.
- (3) Shields CL, Shields JA, Gross NE, Schwartz GP, Lally SE – Survey of 520 eyes with uveal metastases. *Ophthalmology* 1997, 104:1265-76.
- (4) Kreusel KM, Bechrakis NE, Krause L, Wiegel T, Foerster MH – Incidence and clinical characteristics of symptomatic choroidal metastasis from breast cancer. *Acta Ophthalmologica* 2007, 85:298-302.
- (5) Wickremasinghe, S, Cansingani KK, Tranos P, Liyanage S, Jones A, Davey C – Ocular presentations of breast cancer. *Acta Ophthalmologica Scandinavica* 2007, 85: 133-142.
- (6) Demirci H, Shields CL, Chao A, Shields J – Uveal metastasis from breast cancer in 264 patients. *Am J Ophthalmol* 2003, 136:264-271.
- (7) Fenton S, Kemp EG, Harnett AN – Screening for ophthalmic involvement in asymptomatic patients with metastatic breast carcinoma. *Eye* 2004, 18:38-40.
- (8) Wiegel T, Bottke D, Kreusel KM, Schmidt S, Bornfeld N, Foerster MH, Hinkelbein W – German Cancer Society – External beam radiotherapy of choroidal metastases-final results of a prospective study of the German Cancer Society (ARO 95-08). *Radiother Oncol* 2002, 64:13-8.
- (9) Rudoler SB, Shields CL, Corn BW, De Potter P, Hyslop T, Curran WJ, Shields JA – Functional vision is improved in the majority of patients treated with external-beam radiotherapy for choroid metastases: a multivariate analysis of 188 patients. *J Clin Oncol* 1997, 15(3): 1244-1251.
- (10) Shields C – Plaque radiotherapy for the management of uveal metastasis. *Curr Opin Ophthalmology* 1998, 9:31-37.
- (11) Liedtke C, Broglio K, Moulder S, Hsu L, Kau SW, Symmans WF, Albarracin C, Meric-Bernstam F, Woodward W, Theriault RL, Kiesel L, Hortobagyi GN, Pusztai L, Gonzalez-Angulo AM – Prognostic impact of discordance between triple-receptor measurements in primary and recurrent breast cancer. *Annals of Oncology* 2009, 20: 1953-1958.

.....

Adress for correspondence:
E. VAN AKEN
Ghent University Hospital
Ghent, BELGIUM