
AN UNUSUAL LOCALIZATION OF RHABDOMYOSARCOMA: ABOUT A CASE REPORT

HAJJI I¹, JELLAB B¹, BENHADDOU R¹,
BAKI S¹

ABSTRACT

Rhabdomyosarcoma is a malignant mesenchymal tumor of childhood. The eyelid localization is unusual. We report the case of a 7-year-old child with upper palpebral rhabdomyosarcoma revealed by an isolated blepharoptosis. The CT-scan revealed a well delimited enhancing soft tissue mass involving the upper eyelid. The tumor was excised totally by an upper eyelid incision under general anesthesia. It was limited in preseptal eyelid without extension to the orbit. Histopathologic examination confirmed the diagnosis of embryonic rhabdomyosarcoma. Postoperatively, the upper eyelid regained its motility. The visual axis was cleared. After surgery, three cures of chemotherapy including ifosfamide, vincristine, and actinomycin were administered. After a 4 months follow up period, there was no sign of tumor recurrence.

KEYWORDS

Chemotherapy, Histopathology,
Rhabdomyosarcoma, Surgery

.....

¹ *Department of Ophthalmology, Mohammed VI
university hospital center, Marrakesh, Morocco*

Submitted: Mar 25, 2011

Accepted: Nov 09, 2011

INTRODUCTION

Rhabdomyosarcoma is the most common primary orbital tumor that affects children (1), accounting for about 4% of all orbital biopsies (2). The average age is seven years (3). Most of the time, the tumor is retrobulbar, but it may affect any part of the ocular region (4). The eyelid localization is unusual (5). An improvement in the mortality rate caused by Rhabdomyosarcoma has been associated with the recent use of radiotherapy and chemotherapy. The authors report the case of an unusual localization of rhabdomyosarcoma and discuss the therapeutic modalities.

CASE REPORT

A 7 year old girl was admitted in our ophthalmology department. She had unilateral right upper eyelid mass inducing a mechanical ptosis (fig.1). It was not causing any pain or discharge. There was no history of trauma or infection. According to her mother, the mass had

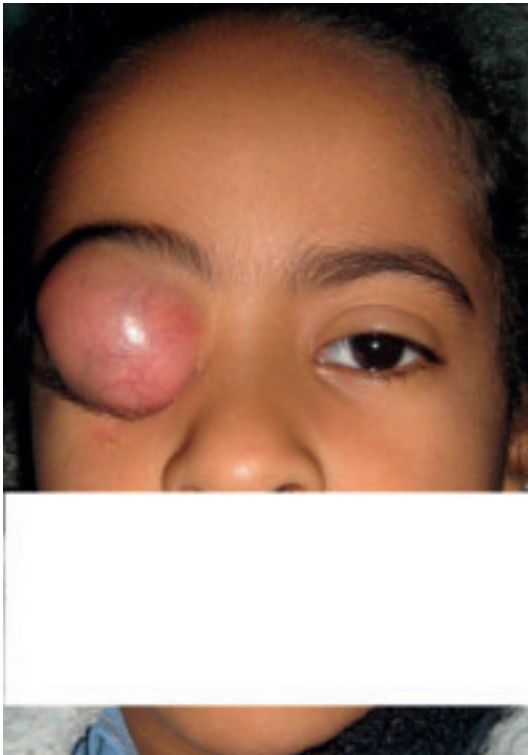

Fig. 1: Clinical presentation

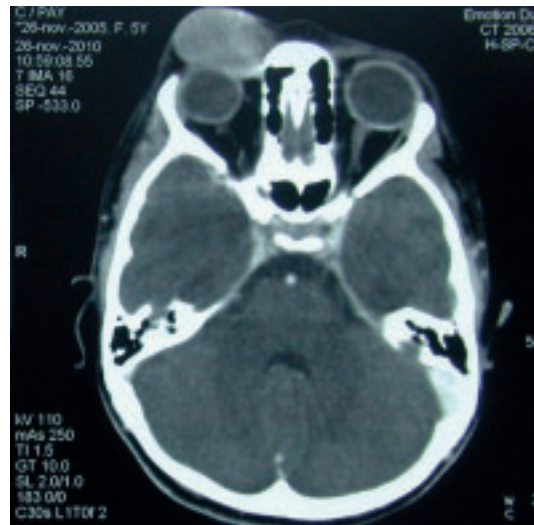


Fig. 2: CT scan

first appeared in the internal angle of the right eye 5 months before and rapidly expanded to the whole upper eyelid. Besides this eye disease, the girl was otherwise healthy. The mass was subcutaneous, indurated and erythematous. The visual acuity was 20/20 in both eyes. The eyelid margin was normal. The eyelid motility was restricted by the tumor. Cornea, anterior chamber, iris and pupillary light reflex were normal. Fundus examination revealed no negative aspects. The left eye was normal. A computed tomography (CT) scan revealed a well defined area of delimited enhanced soft tissue mass involving the upper eyelid measuring 37 mm × 27,5 mm. There was no extension to the eye (fig. 2). The tumor was removed totally by an upper eyelid incision under general anesthesia (fig. 3a). It was limited to the pre-septal eyelid without extension to the orbit and measured 6 cm × 4 cm (fig. 3b). Postoperatively, the upper eyelid regained its motility. The visual axis was cleared. (fig. 8). Histopathologic examination disclosed mitotically active, poorly differentiated malignant cells. Various elongated spindle-shaped cells with highly eosinophilic cytoplasmic and nuclear pleomorphies were discovered (fig. 4). A palpebral rhabdomyosarcoma was suspected and immunohistochemical studies were conducted. The tumor cells had positive immunoreactivity to myogenin, desmine and actine smooth muscle (fig. 5, 6, 7). Results of the metastatic workup were

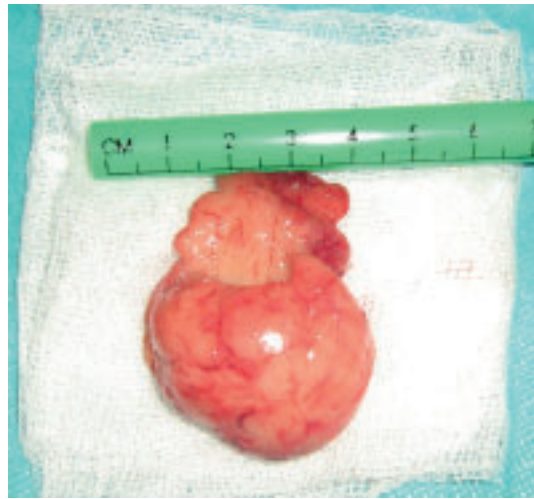
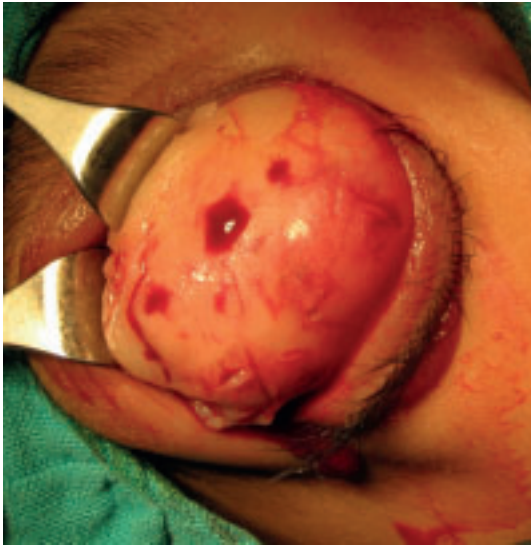
Fig. 3 a-b: Macroscopic view of the neoplasm

negative. The diagnosis of embryonal rhabdomyosarcoma was confirmed.

According to study MMT95, we classified the tumor into the group 95-3 and beyond the treatment involves three cures of IVA:

I = Ifosfamide: 3 g/m² on day 1 and day 2 associated with a concomitant injection of Mesna at the same dose and alkaline hyperhydration.

V = Vincristine: 1.5 mg/m² on day 1, 8 and day 15

A = Actinomycin was not administered because it is not available in our country.

On day 22, we started the second round of IVA. The evolution was marked by the absence of tumor recurrence with a good static and dynamic result of the upper eyelid (fig.8).

DISCUSSION

Rhabdomyosarcoma (RMS) is a malignant mesenchymal tumor. It originates from pluripotential mesenchymal cells that have the capacity to differentiate into skeletal muscle (6). Orbital rhabdomyosarcoma represents 9% of all rhabdomyosarcomas and usually occurs at a median age of six to eight years (6-8). RMS can involve any parts of the ocular tissue. A recent review of clinical spectrum of 33 pediatric patients by Shields and al showed that the orbit

is the most commonly affected area (76%) followed by the conjunctiva (12%), uveal tract (9%), within the globe (9%) and eyelid (3%) (5). Pure eyelid localization such as the case of our patient is rare. Most cases of reported eyelid RMS represent subcutaneous extension of the anterior orbital RMS. In 1995, the international rhabdomyosarcoma study group tried to homogenize the various histological classifications (10). Two main histological types were found: Embryonal rhabdomyosarcoma and alveolar rhabdomyosarcoma. Undifferentiated rhabdomyosarcoma which are less frequent are classified separately.

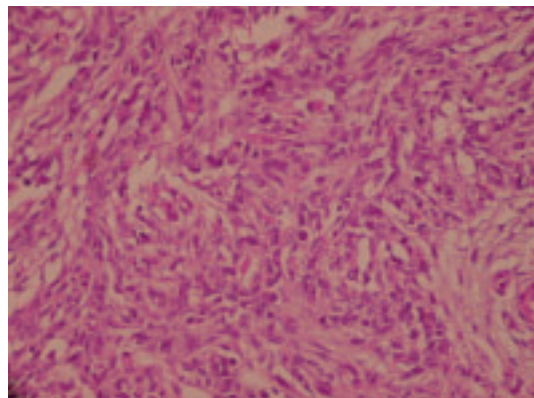


Fig. 4: Photomicrograph demonstrating an infiltrated of poorly differentiated tumor cells spindle shaped

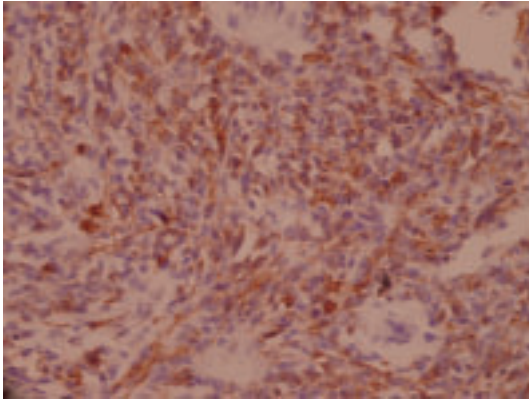


Fig. 5: Photomicrograph revealing that tumor cells shows positive intracytoplasmic immunoreactivity for muscle marker desmin.

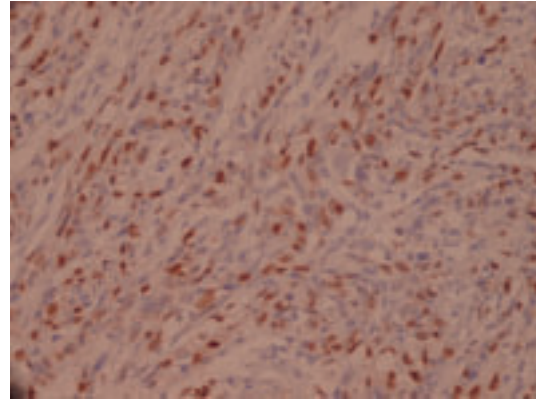


Fig. 6: Photomicrograph revealing that tumor cells shows positive intracytoplasmic immunoreactivity for muscle marker actin

The typical picture of RMS is a painless proptosis that evolves rapidly in few weeks. In our case, the eyelid mass was the main chief complaint. The differential diagnosis usually includes infantile hemangioma, leukemia and neuroblastoma. The diagnosis of RMS must be considered in the case of recent onset of exophthalmos in a child or in cases of rapid development. The other symptoms are diplopia, decreased visual acuity, ptosis...

The reference investigation techniques are computerized tomography and magnetic resonance imaging. Imaging must be performed before biopsy. Rhabdomyosarcoma has no specific appearance on imaging. The objective is to determine the preoperative stage of the tumor. Although the clinical and radiological features are sometimes suggestive of RMS, the diagnosis can be confined only by histological findings. The immunochemistry confirms the striated muscle origin of the tumor; rhabdomyosarcoma cells usually express vimentin, actin and desmin. However, none of these markers are specific (11).

Management of orbital rhabdomyosarcoma must be multidisciplinary. It is composed of chemotherapy, radiotherapy and conservative surgery. Current SIOP (international society of pediatric oncology) recommends simple biopsy at the time of diagnosis (12). But the amount of tissue removed during biopsy is still controversial. Most ophthalmologists believe that only a

small biopsy is needed as chemotherapy will be administered regardless of the amount of tissue removed (13). Otherwise, after a large surgery, the chemosensitivity cannot be assessed. However, some prefer complete or near complete surgical resection without mutilation in the absence of lymph node invasion or metastasis. In 1950 and 1960, radical primary surgery performed before chemotherapy and radiotherapy confirmed the efficiency of surgery (14). It is no longer performed as a first line therapy. It is only used in cases of failure of chemotherapy and radiotherapy, particularly in recurrence cases. Surgery can also be used to perform a second look to consider a residual tumor persisting after chemotherapy (13).

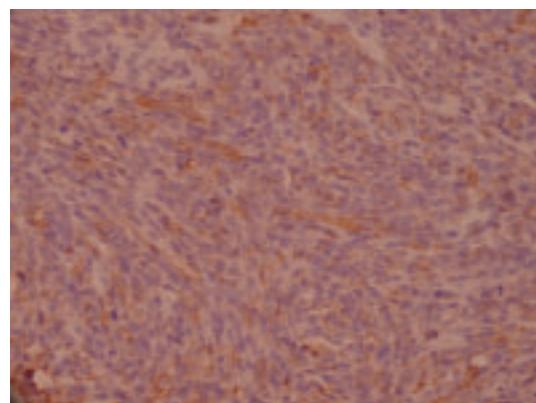


Fig. 7: Photomicrograph revealing that tumor cells shows positive nuclear immunoreactivity for muscle marker myogenin.

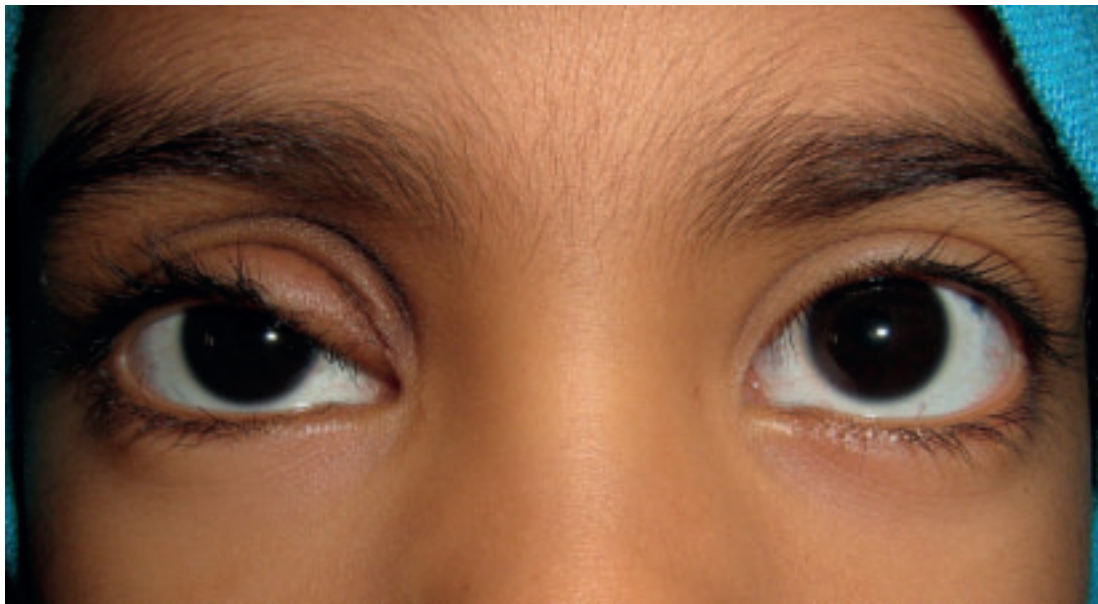

Fig. 8: Postoperative photograph of patient 15 days after surgery

A complete removal was performed in our case without mutilation (fig. 8) and in the context of metastatic negative results.

Rhabdomyosarcoma is a chemosensitive tumour. A combined use of several antimetabolic agents improves the remission rate. The efficiency of chemotherapy has not been specifically evaluated in orbital rhabdomyosarcoma. The duration of treatment and the type of chemotherapy are based on risk factors such as the stage, the histological findings, the age... The basic regimen for rhabdomyosarcoma in children is IVA. The efficiency of this combination has been demonstrated (15). Although actinomycin is not available in our country, the use of IV has shown good results, but we cannot evaluate in this stage of treatment, the exact rate of remission. Multidrug chemotherapy and early external beam radiotherapy (EBRT) is used in advanced stage diseases. Other protocols were proposed for non orbital rhabdomyosarcoma. The AMORE protocol is applied in advanced stage and non orbital, non metastatic head and neck RMS, mainly at the parameningeal sites. This strategy consists of consecutive ablative surgery, moulage technique afterloading brachytherapy, and surgical reconstruction (16).

CONCLUSION

Rhabdomyosarcoma is the most common primary orbital tumor in childhood. The eyelid localization is unusual. The clinical and radiological features are sometimes suggestive of RMS. The diagnosis can be confirmed only by histological findings. Management of palpebral rhabdomyosarcoma must be multidisciplinary. An improvement in the mortality and the morbidity rates of rhabdomyosarcoma has been associated with early diagnosis and the early use of radiotherapy and chemotherapy.

REFERENCES

- (1) Abramson DH, Servodidio CA – Ophthalmic pathology and intraocular tumors. In: basic and clinical science course 1995-1996. San Francisco: American Academy of Ophthalmology; 1995. p. 230-82.
- (2) Shields JA, Bakewell B, Augsburger J, et al. – Space-occupying orbital masses in children. A review of 250 consecutive biopsies. *Ophthalmology* 1986; 93:379-84.
- (3) Wharam M, Beltangady M, Hays D, et al. – Localized rhabdomyosarcoma. An interim report of the Intergroup Rhabdomyosarcoma Study

- Committee. Ophthalmology. 1987; 94: 251-254.
- (4) Le Gall F, Edan C, Toulemont PJ, Jouan H, Urvoy M, Ramee MP – Rhabdomyosarcome orbitaire de l'enfant. J Fr Ophtalmol 1994; 17:67-73.
- (5) Shields C, Shields A, Santosh G, Hakan D – Clinical spectrum of primary ophthalmic rhabdomyosarcoma. Ophthalmology 2001; 108:2284-92.
- (6) Shields JA – Diagnosis and Management of Orbital Tumors. First edition. Philadelphia: WB Saunders Company, 1989: 243-58.
- (7) Maurer H, Gehan EA, Betangady M, et al. – The Intergroup Rhabdomyosarcoma Study-II. Cancer 1993; 71:1904- 22.
- (8) Shields JA, Shields CL, Eagle RC, et al. – Orbital rhabdomyosarcoma. Arch Ophthalmol 1987; 105:700-1.
- (9) Wharam M, Betangady M, Hays D, et al. – Localized orbital rhabdomyosarcoma. An interim report of the Intergroup Rhabdomyosarcoma Study. Ophthalmology 1987; 94:251-3.
- (10) Rodary C, Gehan EA, Flamant F, Trevner J, Carli M, Auquier, et al. – Prognostic factors in 951 nonmetastatic rhabdomyosarcoma in children: a report from the International Rhabdomyosarcoma Workshop. Med Pediatr Oncol 1991; 19:89-95
- (11) Ralph C, Eagle Jr. – Immunohistochemistry in diagnostic ophthalmic pathology. Clinical and Experimental Ophthalmology 2008; 36: 675-688
- (12) Lawrence Jr W, Hays DM – Surgical lessons from the Intergroup Rhabdomyosarcoma Study. Natl Cancer Inst Monogr 1981; 4: 159-163.
- (13) Orbach D, Brisse H, Helfre S, Frenaux P, Hussein K, Aerts I, Desjardin L, Fattet S – Effectiveness of chemotherapy in rhabdomyosarcoma: example of orbital Primary. Expert Opin. Pharmacother 2003; 4(12): 2165-2174
- (14) Orbelin O, Rey A, Anderson J. treatment of orbital rhabdomyosarcoma: Survival and late effects of treatment results of an international workshop. J. Clin. Oncol 2001; 19: 197-204.
- (15) Miser JS, Lensella TJ, Triche TJ – Ifosfamid with mesna uroprotection and etoposid. An effective regimen in the treatment of recurrent sarcomas and other tumors of children and young adult. J. Clin.Oncol.(1987): 1191- 1198
- (16) Schouwenburg PF, Kupperman D, Bakker FP, Blank LE, de Boer HB, Voûte TA – New combined treatment of surgery, radiotherapy, and reconstruction in head and neck rhabdomyosarcoma in children: the AMORE protocol. Head Neck 1998, 20, 283-292.
-
- Adress for correspondence:*
Boite postale 20303 ALLAL FASSI
40055 Marrakech, Maroc
Phone: 0021270286323
Email: jellab_badr@yahoo.fr