

---

# ANTERIOR SEGMENT ISCHEMIA WITH RUBEOSIS IRIDIS AFTER A CIRCULAR BUCKLING OPERATION TREATED SUCCESSFULLY WITH AN INTRAVITREAL BEVACIZUMAB INJECTION: A CASE REPORT AND REVIEW OF THE LITERATURE

*JANSSENS K, ZEYEN T, VAN CALSTER J*

---

## ABSTRACT

*Purpose:* To report a case of anterior segment ischemia (ASI) with rubeosis iridis after circular buckling surgery in a highly-myopic patient which was successfully treated with a second intravitreal bevacizumab injection.

*Methods:* Case report and review of the literature.

*Discussion:* ASI is a rare but potentially serious complication of posterior segment surgery. Finally it leads to neovascular glaucoma as a result of rubeosis iridis. An encircling band can compromise anterior segment circulation in different ways: by manipulation or disinsertion of the recti muscles, by occlusion of the vortex veins through compression or by changes in the blood supply of iris and ciliary body. This patient developed rubeosis iridis secondary to ASI. There was a remarkable regression of rubeosis iridis one month after a second intravitreal bevacizumab injection. Other case reports of bevacizumab use in neovascular glaucoma have shown clinical improvements of these patients, with intraocular pressure control and reduction of the neovascularization process.

*Conclusion:* We describe a highly-myopic patient who developed ASI with rubeosis iridis after a circular buckling operation. Slit-lamp examination and gonioscopy can show very little rubeosis iridis and can be misleading. Iris fluorescein angiography is the most sensitive technique for evaluation of iris vessel abnormalities and is of considerable value in the ear-

ly detection of rubeosis iridis. This report demonstrates the rapid resolution of rubeosis iridis on iris fluorescein angiography after a second intravitreal injection of bevacizumab. How long this regression will persist is unknown and repeated injections of bevacizumab may be necessary if rubeosis reappears.

## KEYWORDS

Anterior segment ischemia (ASI); rubeosis iridis; neovascular glaucoma (NVG); circular buckling surgery; intravitreal bevacizumab (IVB); iris fluorescein angiography.

.....

*Submitted: July 04, 2011*

*Accepted: Aug 08, 2011*

## INTRODUCTION

Anterior segment ischemia (ASI) is a rare but potentially serious complication of posterior segment surgery. Finally it leads to neovascular glaucoma (NVG) as a result of rubeosis iridis. The studies of Tanaka et al. (1) and Tawara et al. (2) concluded that ASI, even without retinal ischemia, can cause neovascularization of the iris in rabbits. Tanaka et al. also reported that ASI causes an elevated aqueous vascular endothelial growth factor (VEGF) in accordance with the ischemic severity (1).

ASI after posterior segment surgery is not usually found in young, healthy patients (3-6). Predisposing factors are detachment of the recti muscles, arterial and venous compression by the explant or encircling band and the use of diathermy (7). Underlying systemic conditions such as generalized atherosclerosis, dysthyroid ophthalmopathy and hematologic disorders including anemia, increased hypercoagulability or sickle cell disease/trait can increase the risk for ASI (8).

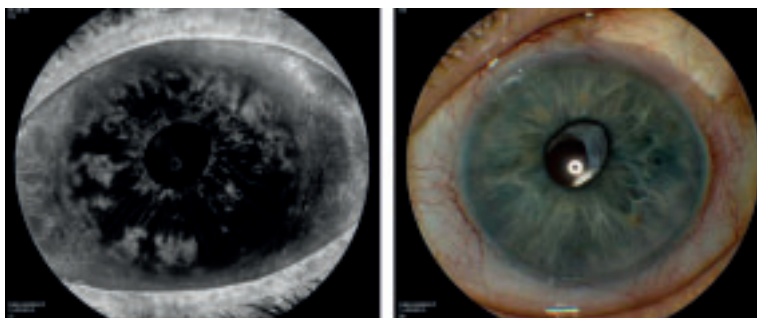
Inhibiting the angiogenesis process by blocking VEGF is a promising strategy for the treatment of anterior segment neovascularization and NVG (9). Bevacizumab is a full-length humanized monoclonal antibody against vascular endothelial growth factor type A. Case reports of bevacizumab use in NVG or anterior segment neovascularization have shown clinical improvements of these patients, with intraocular pressure (IOP) control (10-13) and reduction of the neovascularization process (14-15).

We describe a highly-myopic patient who developed rubeosis iridis and NVG after a circular buckling operation and strabismus surgery. This case demonstrates a remarkable and rapid regression of rubeosis iridis after a second intravitreal bevacizumab injection, confirmed by an iris fluorescein angiography.

## CASE HISTORY

This 57-year-old myopic woman had a retinal detachment of the left eye in 1997. She underwent a vitrectomy with encircling band, silicone oil tamponade and endolaser photocoagulation in the left eye. The silicone oil (tamponade) was removed 5 months later but she developed a secondary glaucoma in 1998 due to residual oil emulsification. The IOP was under control with topical therapy. In 1998 she underwent cataract surgery of the left eye with a postoperative visual acuity of 20/100. In 2003 a bilateral recession (4.5 mm) of the external rectus muscle was performed for a decompensated exophoria. In 2009 the IOP was not any more under control medically and a Baerveldt tube was implanted in the anterior chamber of the left eye. Six months later there was a good IOP control, but rubeosis iridis was observed at gonioscopy. Fundus fluorescein angiography was performed and did not reveal retinal ischemia. A carotid echography was done, but showed no significant stenosis.

In December 2009 she presented at our clinic with a red and painful left eye. On examination the visual acuity was counting fingers and the IOP was 45 mmHg. Slit-lamp biomicroscopy showed a hyphema, rubeosis iridis and a well-formed anterior chamber. Indirect funduscopy was not possible, but echography showed no retinal detachment. The diagnosis of neovascular glaucoma was set and she was treated with oral and topical IOP lowering drugs. One day later the IOP was reduced to 12 mmHg. Transscleral retinal cryocoagulation of the 4 retinal quadrants was per-



*Fig. 1:* Iris fluorescein angiography showed pathologic vessels in all quadrants of the iris showing leakage within seconds. Biomicroscopy showed very little rubeosis iridis. The angiographic picture was taken after 28 seconds.

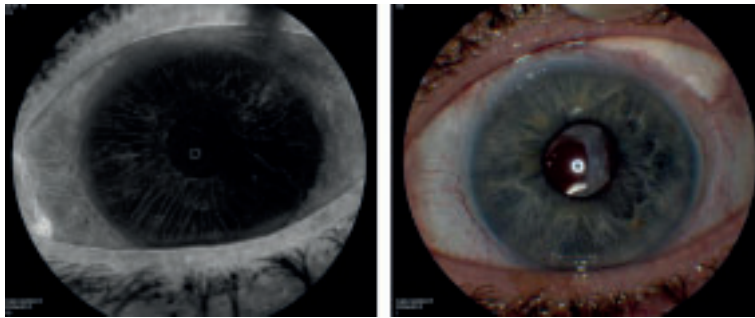


Fig. 2: These pictures were taken one month after a second IVB injection. Iris fluorescein angiography revealed only regular radial iris vessels and minimal leakage in the superotemporal quadrant. Biomicroscopy showed no rubeosis iridis. The angiographic picture was taken after 37 seconds.

formed three days later and an intravitreal bevacizumab (IVB) injection was also given. On examination two months later the visual acuity was 25/100 and the IOP 14 mmHg. Slit-lamp biomicroscopy showed very little rubeosis iridis (Figure 1, right). Iris fluorescein angiography at that time revealed pathologic vessels in all quadrants of the iris showing leakage within seconds (Figure 1, left). One month after a second IVB injection, only regular radial iris vessels and minimal leakage in the superotemporal quadrant were seen (Figure 2, left).

## DISCUSSION

We present a patient with anterior segment ischemia (ASI) after a circular buckling operation and strabismus surgery. The anterior segment is vascularized by the long posterior ciliary arteries and short anterior ciliary arteries. Two long posterior ciliary arteries arise from the ophthalmic artery and course toward the anterior segment within the sclera along the horizontal meridians. The vessels supply approximately 30% of the blood flow to the anterior segment (8). The anterior ciliary arteries, which arise from the muscular branches of the ophthalmic artery, lie within the recti muscles. There are two anterior ciliary arteries per muscle, the sole exception being the lateral rectus, which carries only one. The one anterior ciliary artery to the lateral muscle is also unique in that it often arises from the lacrimal artery. These arteries supply the remainder of the arterial flow to the anterior segment. Primate studies sug-

gest that the anterior ciliary arterial system supplies 70% to 80% of the anterior segment blood supply (16). Just posterior to the muscle insertions, the anterior ciliary arteries deviate from the muscle belly and penetrate the sclera to anastomose with the long posterior ciliary arteries. The venous drainage of the anterior segment takes place through the 4-6 vortex veins. Damage to the vortex veins, the anterior ciliary ar-

teries and the long posterior ciliary arteries are the most important factors in the development of ASI. There are various ways in which the vascularization can be endangered.

After *strabismus surgery*, the incidence of anterior segment ischemia is approximately 1 case per 13,000 procedures (8). It is sometimes necessary to detach one or more of the recti muscles and this will cause the anterior ciliary arteries to drop out. The vertical recti muscles are most dangerous in this connection because there are no compensating long posterior ciliary arteries there. Patients who have undergone two-muscle vertical rectus manipulation, operations involving three or more extraocular muscles or strabismus surgery following encircling buckling surgery are more likely to experience significant anterior segment ischemia.

An *encircling band or explant* can compromise anterior segment circulation in various ways (8). First by manipulation or disinsertion of the recti muscles. In the past, scleral buckle application often included disinsertion of one or more recti muscles. Even with contemporary surgical techniques, ischemia can also arise from occlusion of the vortex veins through compression. Finally, scleral buckling can cause changes in the arterial circulation. In an experimental model using albino rabbits, an encircling band decreased perfusion of the iris and ciliary body (17).

*Panretinal photocoagulation (PRP)* can cause closure of the choriocapillaris (18). The long

posterior ciliary arteries are larger choroidal vessels and usually remain patent after PRP, however, an additional insult, such as intraoperative hypotension, may precipitate ASI. Relatively low systemic blood pressure combined with increased intraocular pressure during scleral depression, may facilitate closure of the long posterior ciliary arteries in patients treated with the indirect laser ophthalmoscope. PRP may be more likely to cause ASI if orbital pressure is high, because it may cause compression of the vortex veins.

There are also *underlying systemic medical conditions* that can predispose a patient to ASI. Older age, generalized atherosclerosis, blood dyscrasias, hematologic disorders that increase serum viscosity, dysthyroid ophthalmopathy, carotid artery disease and carotid cavernous sinus fistula can place patients at risk for ASI (8). The clinical presentation of ASI is diverse, can be subtle and difficult to detect. Patients usually present with mild pain and reduced visual acuity beginning 1 or 2 days after posterior segment- or strabismus surgery. Early signs include a poorly reactive pupil, episcleral vessel dilatation, conjunctival chemosis, corneal oedema, mild iritis, a fibrinoid reaction, hypopyon, rubeosis iridis and neovascularization of the anterior chamber angle. Late findings include posterior synechiae and iris atrophy, chronic iridocyclitis, keratopathy, anterior cortical cataract, hypotony and finally phthisis.

Our patient developed rubeosis iridis and NVG secondary to ASI. There was no retinal ischemia, nor did the carotid echography showed a carotid artery stenosis. The history of encircling band- and strabismus surgery were contributing factors. As only one horizontal muscle, the lateral rectus, was recessed with 4.5 mm in both the eyes, we conclude that the circular buckling procedure was the major cause of the ASI.

Our patient had remarkable regression of rubeosis iridis on iris fluorescein angiography one month after the second IVB injection. Avery reported a single case of rapid resolution of iris and retinal neovascularization with the administration of IVB (19). Davidorf et al. reported similar results in a single patient with regressed rubeosis iridis after a single injection of bevacizumab (15). Iliev et al. described the use of

IVB for six patients with rubeosis iridis and refractory NVG (10). This treatment resulted in marked regression of anterior segment neovascularization and relief of symptoms in the first 2 days. The study of Sugimoto et al. concluded that a single IVB to eyes with rubeotic glaucoma reduced the neovascularization in the human iris surface, but could not eliminate completely neovascularization in iris stroma (20). This finding implies that the prevention of hyphema and fibrin formation based on slit-lamp examination can't be predicted, even if neovascularization in iris surface seems to be eliminated by a single dose of IVB (20).

With the use of iris fluorescein angiography, Grisanti et al. studied the effects of IVB on neovascularization of the iris (21). They presented a case series of six eyes in three patients who had NVG and rubeosis iridis due to central retinal vein occlusion or proliferative diabetic retinopathy and received 1.0 mg of IVB. They noted a decrease in iris fluorescein leakage as early as 1 day after injection. Of the six eyes, there was no regression at 1-month follow-up. The role of bevacizumab and length of therapeutic benefit was explored by Gheith et al (22). They presented a case series of six patients with an average of 9.7 months of follow-up. Each patient received IVB followed by PRP one week later. All patients had a complete regression of iris and angle neovascularization. However two patients had recurrence of rubeosis iridis after 3 and 5 months, respectively. They received another injection of bevacizumab that eradicated the recurrent neovascularization. The pharmacokinetics of bevacizumab was further investigated by Bakri et al. They found that the vitreous half-life of 1.25 mg IVB is 4.32 days in a rabbit eye (23).

## CONCLUSION

We describe a highly-myopic patient who developed ASI with rubeosis iridis and NVG after a circular buckling operation and strabismus surgery. Slit-lamp examination and gonioscopy can show very little rubeosis iridis and can be misleading. Iris fluorescein angiography is the most sensitive technique for the evaluation of iris vessel abnormalities and is of considerable value in the early detection of rubeosis iridis. Our patient had remarkable regression of

rubeosis iridis on iris angiography one month after a second IVB injection. How long this regression will persist is unknown and repeated injections of bevacizumab may be necessary if rubeosis iridis reappears.

#### REFERENCES

- (1) Tanaka T, Matsuo T, Ohtsuki H – Aqueous vascular endothelial growth factor increases in anterior segment ischemia in rabbits. *Jpn J Ophthalmol* 1998; 42:85-89.
- (2) Tawara A, Kubota T, Hata Y, et al. – Neovascularization in the anterior segment of the rabbit eye by experimental anterior ischemia. *Graefes Arch Clin Exp Ophthalmol* 2002; 240:144-153.
- (3) Boniuk M, Zimmerman LE – Necrosis of the iris, ciliary body lens and retina following scleral buckling operations with circling polyethylene tubes. *Trans Am Acad Ophthalmol Otolaryngol* 1961; 65:671-693.
- (4) Freeman HM, Hawkins WR, Schepens CL – Anterior segment necrosis. An experimental study. *Arch Ophthalmol* 1966; 75:644-650.
- (5) Ryan SJ, Goldberg MF. Anterior segment ischemia following scleral buckling in sickle cell hemoglobinopathy. *Am J Ophthalmol* 1971; 72:35-50
- (6) Girard LJ, Beltranena F – Early and late complications of extensive muscle surgery. *Arch Ophthalmol* 1960; 64:576-584.
- (7) Ansem RP, Bastiaensen LA – Glaucoma following retinal detachment operations. *Doc Ophthalmol* 1987; 67:19-24.
- (8) Bronner G, Zarbin MA, Bhagat N – Anterior ischemia after posterior segment surgery. *Ophthalmol Clin North Am* 2004; 17:539-43
- (9) Bhisitkul RB – Vascular endothelial growth factor biology: clinical implications for ocular treatments. *Br J Ophthalmol* 2006; 90:1542-1547
- (10) Iliev ME, Domig D, Wolf-Schnurrbusch U, Wolf S, Sarra GM – Intravitreal bevacizumab (Avastin) in the treatment of neovascular glaucoma. *Am J Ophthalmol* 2006; 142:1054-1056.
- (11) Kelkar AS, Kelkar SB, Kelkar JA, Nagpal M, Patil SP – The use of intravitreal bevacizumab in neovascular glaucoma: a case report. *Bull Soc Belge Ophthalmol* 2007; 303:43-45.
- (12) Kahook MY, Schuman JS, Noecker RJ – Intravitreal bevacizumab in a patient with neovascular glaucoma. *Ophthalmic Surg Lasers Imaging* 2006; 37:144-146.
- (13) Chilov MN, Grigg JR, Playfair TJ – Bevacizumab (Avastin) for the treatment of neovascular glaucoma. *Clin Experiment Ophthalmol* 2007; 35:494-496.
- (14) Batioglu F, Astam N, Ozmert E – Rapid improvement of retinal and iris neovascularization after a single intravitreal bevacizumab injection in a patient with central retinal vein occlusion and neovascular glaucoma. *Int Ophthalmol* 2008; 28:59-61.
- (15) Davidorf FH, Mouser JG, Derick RJ – Rapid improvement of rubeosis iridis from a single bevacizumab (Avastin) injection. *Retina* 2006; 26:354-356.
- (16) Wilcox LM, Keough EM, Connolly RJ, Hotte CE – The contribution of blood flow by the anterior ciliary arteries to the anterior segment in the primate eye. *Exp Eye Res* 1980; 30:167-174.
- (17) Diddie KR, Ernest T – Uveal blood flow after 360 degree constriction in the rabbit. *Arch Ophthalmol* 1980; 98:729-730.
- (18) Wilson DJ, Green WR – Argon laser panretinal photocoagulation for diabetic retinopathy: scanning electron microscopy of human choroidal vascular casts. *Arch Ophthalmol* 1987; 105:239-242.
- (19) Avery RL – Regression of retinal and iris neovascularization after intravitreal bevacizumab (Avastin) treatment. *Retina* 2006; 26:352-354.
- (20) Sugimoto Y, Mochizuki H, Okumichi H, et al. – Effect of intravitreal bevacizumab on iris vessels in neovascular glaucoma. *Graefes Arch Clin Exp Ophthalmol* 2010; 248:1601-1609.
- (21) Grisanti S, Biester S, Peters S, et al. – Bartz-Schmidt KU, for the Tuebingen Bevacizumab Study Group. Intracameral bevacizumab for iris rubeosis. *Am J Ophthalmol* 2006; 142:158-160.
- (22) Gheith ME, Siam GA, de Barros DS, et al. – Role of intravitreal bevacizumab in neovascular glaucoma. *J Ocul Pharmacol Ther* 2007; 23:487-491.
- (23) Bakri SJ, Snyder MR, Reid JM, et al. – Pharmacokinetics of intravitreal bevacizumab (Avastin). *Ophthalmology* 2007; 114:855-859.

.....

*Adress for Correspondence:*  
 K. JANSSENS  
 UZ Leuven  
 email: janssens\_katrien@hotmail.com