

DIPLOPIA FROM SKEW DEVIATION IN RAMSEY-HUNT SYNDROME. A CASE REPORT.

VERHULST E. *, VAN LAMMEREN M. *,
DRALANDS L. *

ABSTRACT

Object: Presentation of a 34-year-old pregnant woman with skew deviation due to peripheral vestibular dysfunction caused by herpes zoster oticus.

Methods: A multidisciplinary approach (neuroophthalmology, otorhinolaryngology, neuroradiology) revealed the diagnosis of Ramsey-Hunt syndrome.

Case report: The patient presented with painful herpes zoster vesicles of the left ear, associated with a rotatory vertigo and hearing loss. Otorhinolaryngological examination showed a unilateral peripheral vestibular loss, a nystagmus towards the unaffected right side, no facial nerve dysfunction and a left perception hearing loss, mainly in the frequencies between 2 - 6 KHz. The patient was treated with Zovirax® IV. Neuroradiological examination (MRI without contrast) revealed no abnormalities. Vertical diplopia from skew deviation was noted \pm 10 days after onset of herpes zoster oticus. Neuroophthalmological and orthoptic examination showed a comitant right hypertropia of 6 diopters and a spontaneous nystagmus to the right.

Conclusion: Skew deviation can be caused by a sudden unilateral cochleo-vestibular loss as described by A.B. Safran. (4,6,7,8)

RÉSUMÉ

Objet: Présentation d'une patiente de 34 ans, enceinte et atteinte d'une déviation oblique suite à une atteinte vestibulaire périphérique d'origine zostérienne.

.....

*Department of Ophthalmology UZ Leuven
Kapucijnenvoer 33, 3000 Leuven Belgium

received: 08.07.00

accepted: 03.09.00

Méthodes: Une investigation pluridisciplinaire (neuro-ophtalmologique, otorhino-laryngologique, neuroradiologique) a permis le diagnostic de syndrome de Ramsey-Hunt.

Cas clinique: La patiente présentait des vésicules douloureuses d'herpes zostérien à l'oreille gauche, associées à des vertiges rotatoires et une perte d'ouïe. L'examen otorhinolaryngologique révélait un déficit vestibulaire unilatéral périphérique, un nystagmus dans la direction de l'oreille droite non-atteinte et une perte d'ouïe perceptive, surtout pour les fréquences entre 2 - 6 KHz. La fonction du nerf facial était normale. La patiente a été traitée par Zovirax® IV.

L'examen neuroradiologique (RMN sans contraste) ne montrait pas d'anomalies. Une diplopie verticale causée par "skew deviation" est apparue \pm 10 jours après le début de l'herpes zostérien à l'oreille. L'examen neuro-ophtalmologique et orthoptique montrait une hypertropie droite concomitante de 6 dioptries prismatiques et un nystagmus spontané vers la droite.

Conclusion: Un déficit cochléo-vestibulaire unilatéral peut être à l'origine d'une déviation oblique ("skew deviation") comme décrit par A.B. Safran. (4,6,7,8)

SAMENVATTING

Onderwerp: Bespreking van een 34 jaar oude zwangere patiënte met schuine deviatie (skew deviation) ten gevolge van perifere vestibulaire disfunctie in het kader van herpes zoster oticus.

Methode: Multidisciplinaire benadering (neuro-ophtalmologie, otorhinolaryngologie, neuroradiologie) leidde tot de diagnose van Ramsey-Hunt syndroom.

Casus: Deze patiënte vertoonde pijnlijke herpes zoster vesikeltjes ter hoogte van het linker oor, rotatoire vertigo en gehoorsdaling. Otorhinolaryngologisch onderzoek toonde een unilaterale perifere vestibulaire stoornis, een nystagmus naar de niet aangetaste rechter zijde, geen nervus facialis disfunctie en een perceptie gehoorsdaling links, voornamelijk in de frequenties van 2 - 6 KHz. De patiente werd behan-

deld met Zovirax® IV. Neuroradiologisch onderzoek (KST zonder contrast) toonde geen abnormaliteiten. Ongeveer 10 dagen na de aanvang van de herpes zoster oticus werd een verticale diplopie door schuine deviatie vastgesteld. Neuro-oftalmologisch en orthoptisch onderzoek toonden een concomitante rechter hypertropie van 6 dioptrie en een spontane nystagmus naar rechts.

Conclusie: Skew deviatie kan veroorzaakt worden door een plotse unilaterale cochleovestibulaire stoornis zoals beschreven door A.B. Safran. (4,6,7,8)

KEY WORDS

Skew deviation, Ramsey-Hunt syndrome

MOTS CLÉS

Déviation oblique, Syndrome de Ramsey-Hunt

INTRODUCTION

Safran described skew deviation resulting from lesions in the peripheral vestibular system (eg: vestibular neurectomy or labyrinthectomy in Menière disease) (1-3, 7-9). We report a patient with a skew deviation caused by herpes zoster oticus in Ramsey-Hunt syndrome.

CASE REPORT

A 34-year-old female patient, who was 13 weeks pregnant, presented with a history of painful herpes zoster vesicles of the left ear, a left-sided hearing loss, a rotatory vertigo and headache. She was admitted to the university hospital where clinical examination with a 256 Hz tuning fork showed a lateralisation to the side of better hearing in the test of Weber. The test of Rinne was positive. The audiogram showed that the conduction through air and bone was equally impaired. It showed a left perception hearing loss mainly in the frequencies of 2000 to 6000 Hz. The patient had a spontaneous nystagmus to the right. Our patient had no facial nerve dysfunction. She was admitted for intravenous treatment with Acyclovir (5mg/kg/8u) and alizapride.

Ten days after the onset of herpes zoster oticus, the patient complained of vertical diplopia. There was a hyperdeviation of the right eye. The patient closed one eye to overcome diplopia. Bielschowsky's head tilt test showed no difference in vertical deviation on right or left head tilt. Examination with a Hess screen after one week showed a comitant right hypertropia of six prism diopters. (Fig. 1) The ocular motility was not restricted in any direction.

On routine ophthalmological examination, the patient had bilaterally a visual acuity of 10/10, Snellen 1 at 30 cm. The pupillary reflexes were normal. Slitlamp and fundus examination revealed no abnormalities.

Additional investigations were performed: EEG recordings showed a normal tracé, MRI without contrast (to exclude herpes encephalitis) revealed no abnormalities.

Our diagnosis was a skew deviation due to vestibular disturbance. We prescribed a Fresnel of six prism diopters with base down in front of the right eye to correct the diplopia.

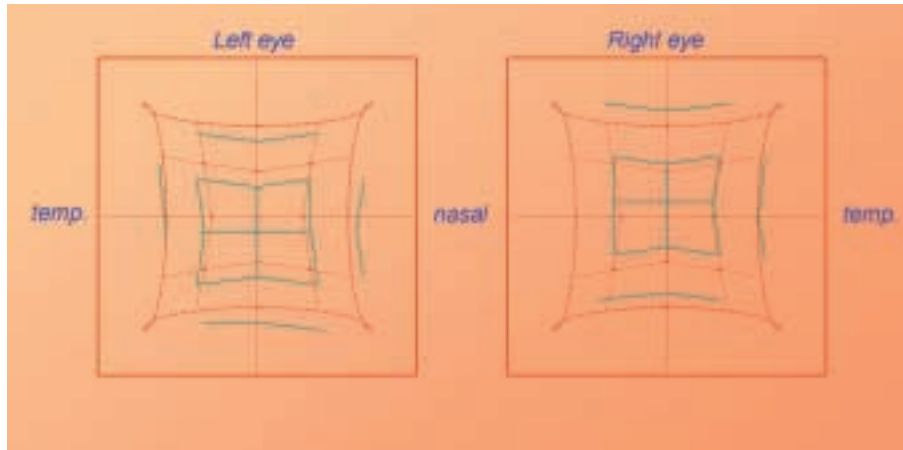


Fig. 1. Representation of skew deviation with the Hess screen one week after the onset of diplopia. The vertical strabismus consists of a comitant right hypertropia of 6 prism diopters.

Six weeks later, diplopia had disappeared and the Hess screen showed no residual vertical deviation. (Fig. 2)

DISCUSSION

In the above presented case, the diagnosis of Ramsey-Hunt syndrome was made. This syndrome consists of a herpes zoster of the ear, associated with facial paresis in 75% of cases, and associated with vestibular deficit in 40% of cases. Our patient had no deficit of the facial nerve.

The vestibular function plays an essential and often under-estimated role in the quality of vision. (6)

The vestibular system has a *dynamic* function in maintaining the stability of an image on the retina: if there is a head movement, the vestibular system causes an eye movement in the opposite direction. As a result, the eyes and the projection of an image on the retina are relatively stable. In case of alterations of the vestibular system, pathological nystagmus can occur and this causes oscillopsia, which means a destabilisation of the image.

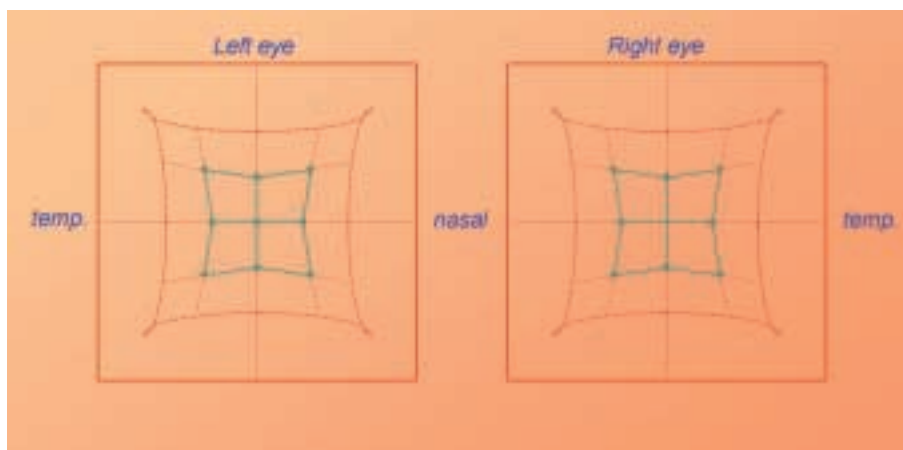


Fig. 2. Representation of skew deviation with the Hess screen after six weeks showed no residual strabismus.




Fig. 3. Ocular tilt reaction: the eye-head postural reaction, consisting of head tilt, conjugated eye cyclotorsion, skew deviation, and alteration of vertical perception directed towards the side of lesion, is illustrated.

The second function is a *static* function: when the head is tilted there is a postural adaptation reaction with cyclotorsion of the eyes to ensure a horizontal plane of gaze. When the vestibular system is impaired, an inappropriate ocular vertical divergence with diplopia can occur. This is what we call *skew deviation*.

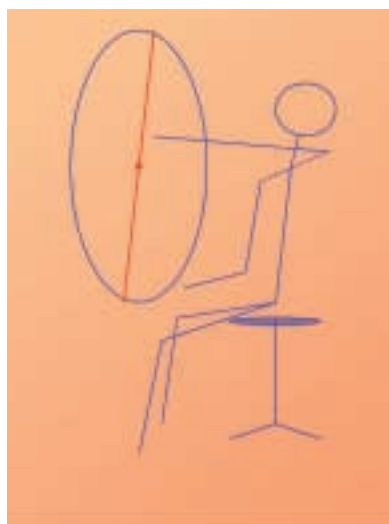

Fig. 4. Measurement of the static visual vertical using the binocular vertical frame technique. The patient has to adjust the ruler along the axis of his subjective vertical perception.

Skew deviation is sometimes part of an inappropriate postural adaptation reaction. There is a false visual impression of inclination of the environment towards the side of the lesion. This causes vertical divergence of the eyes, head tilt and cyclotorsion of the eyes to overcome the disturbance of verticality. We call this an *ocular tilt reaction*. (Fig. 3) Not every patient shows all components of this ocular tilt reaction.

The spontaneous *nystagmus* to the right in our patient can be explained by the functional deficit of the left vestibular system. This causes a reduced stimulus of the right lateral rectus muscle and the left medial rectus muscle. The relatively higher muscular tonus of the right medial rectus muscle and the left lateral rectus muscle causes the slow vestibular component to the left. This is followed by a fast and compensatory component to the right.

In our *differential diagnosis*, we thought of a trochlearis paresis of the right eye, but the Hess screen of a recent trochlearis paresis usually shows a incomitant right hypertropia. A positive Bielschowsky on head tilt to the side of paresis and an excyclotorsion of the hypertropic eye is expected.

Safran introduced some new ophthalmological evaluation techniques to deal with this kind of patients. (4,10) The inclination of verticality can be investigated with a *vertical frame*. (Fig. 4) The patient is seated in front of a large ver-

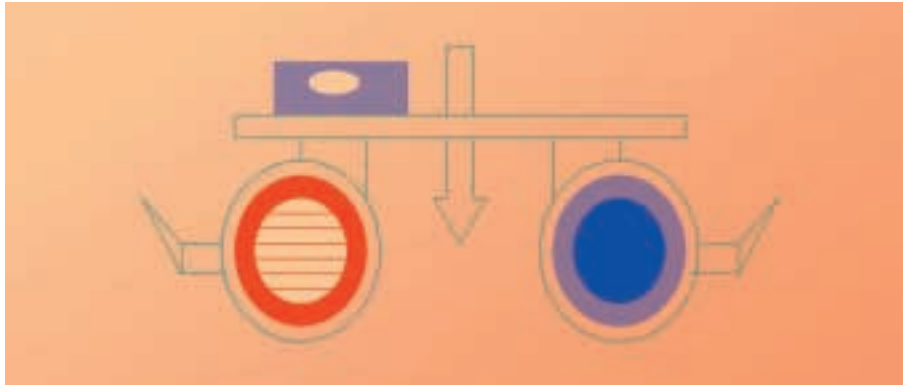


Fig. 5. Measurement of the static visual vertical using the modified Maddox rod monocular technique. The patient has to adjust the illuminated line along the axis of perceived verticality.

tical screen with a central ruler. A dental bite is used to ensure an upright head position. The patient's visual field is restricted to the screen by an appropriate frame. He is asked to adjust the ruler along the vertical axis of his subjective visual perception. The ruler's tilt is measured in degrees.

The *modified Maddox rod* technique (Fig. 5) is a monocular method. (5) The patient is asked to adjust the illuminated line along the axis of perceived verticality. To ensure that the frame is horizontal, a spirit level was added to the transverse bar of the Maddox rod.

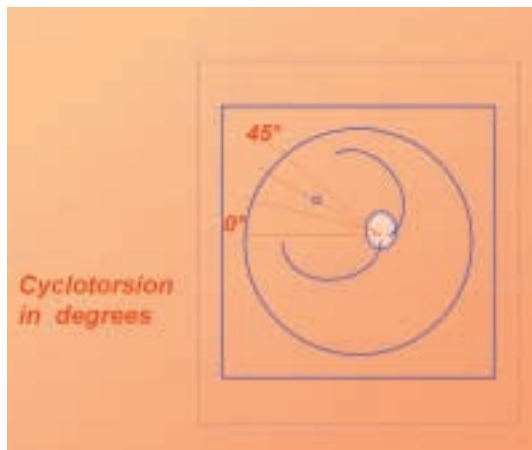


Fig. 6. Measurement of conjugated cyclotorsion of the eyes with ocular fundus photographs. The degree of cyclotorsion is quantified by comparing the papillo-macular axis tilt with the horizontal, using a graduated ruler; left peripheral vestibular deficit shows a leftward conjugated cyclotorsion with incyclotorsion in the right eye and excyclotorsion in the left eye.

Fundus photography (Fig. 6) is helpful in quantifying the degree of cyclotorsion. The photographs are taken with the head in an upright position. The papillo-macular axis tilt is measured.

Our patient fitted in the clinical picture as described by A.B. Safran.

In conclusion, we presented a patient with skew deviation due to unilateral vestibular dysfunction caused by Herpes Zoster Oticus.

This type of strabismus is often misdiagnosed in clinical practice, because symptoms can be masked by spontaneous nystagmus and neurovegetative symptoms such as rotatory vertigo, headache and vomiting.

Full recovery is often the case in herpes zoster.

REFERENCES

- 1) BRANDT T.H., DIETERICH M. - *Different types of skew deviation*. J. Neurol., Neurosurg., and Psychiatry 1991;54:549-550.
- 2) HALMAGYI G.M., CURTHOYS I.S., BRANDT T.H., DIETERICH M. - *Ocular tilt reaction: clinical sign of vestibular lesion*. Acta Otolaryngol. 1991; Suppl. 481:47-50.
- 3) HALMAGYI G.M., GREY M.A., GIBSON W.P.R. - *Ocular tilt reaction with peripheral vestibular lesion*. Ann. Neurol. 1979;6:80-83.
- 4) SAFRAN A.B., HÄUSLER R., ISSOUA D., STEPHANIAN E., CHIARI M., VIBERT D., ROTH A. - *Strabismes induits par des lésions vestibulaires périphériques*. Kl. Mbl. Augenhk. 1992; 200:418-420.

- 5) SAFRAN A.B., MERMOUD A. - *Frame with spirit level for evaluating visual tilt.* J. clin. Neuro-ophthalmol. 1991;11:74-77.
- 6) SAFRAN A.B., VIBERT D., HÄUSLER R. - *La névrite vestibulaire: une cause souvent insoupçonnée de diplopie.* Kl. Mbl. Augenhk. 1995; 206:413-415.
- 7) SAFRAN A.B., VIBERT D., ISSOUA D., HÄUSLER R. - *Skew deviation after vestibular neuritis.* Am. J. Ophthalmol. 1994;118:238-245.
- 8) VIBERT D., HÄUSLER R., SAFRAN A.B., KOERNER F. - *Diplopia from skew deviation in unilateral peripheral vestibular lesions.* Acta Otolaryngol. 1996;116:170-176.
- 9) VIBERT D., HÄUSLER R., SAFRAN A.B., KOERNER F. - *Ocular tilt reaction associated with a sudden idiopathic unilateral peripheral cochleovestibular loss.* J. Otorhinolaryngol. 1995; 57: 310-315.
- 10) VIBERT D., SAFRAN A.B., HÄUSLER R. - *Evaluation clinique de la fonction otolithique par mesure de la cyclotorsion oculaire et de la 'skew deviation'.* Ann. d' Otorhinolaryngologie et de chirurgie cervico-faciale 1993;110: 87-91.

.....

Address for correspondence:
 L. Dralands
 Dept. of Ophthalmology
 UZ Leuven
 Kapucijnenvoer 33
 B-3000 Leuven
 Belgium