
INTRAVITREAL BEVACIZUMAB FOR MYOPIC CHOROIDAL NEOVASCULARIZATION: 1-YEAR AND 2-YEAR RESULTS

COPPENS G.*, ANGULO BOCCO M.I.*,
SPIELBERG L.*, LEYS A.*

ABSTRACT

Methods: A retrospective interventional case series of 29 patients with mCNV was conducted. Charts were reviewed of all patients who received IVB for active mCNV and who had a follow-up of at least 12 months after the first injection. Patients were divided into three groups based on length of follow-up: patients in Group 1 had a follow-up of ≥ 12 months, in Group 2 of ≥ 18 months and in Group 3 of ≥ 24 months. Changes in visual acuity (VA) and CMT were analyzed, as were safety considerations such as intraocular inflammation and endophthalmitis.

Results: Twenty women and nine men with a mean age of 62.2 years (range 31-85) were included. No peri- or post-injection ocular or systemic side effects were noted in either group. Mean logMAR best-corrected visual acuity (BCVA) at baseline for all patients (n=29) was 0.71. Mean visual acuity for all 29 patients had improved significantly at 3 months (p=0.0035) and one year (p=0.0042) after baseline. Although visual acuity gains were maintained at 18 and 24 months, these were not statistically significant (p=0.11 and p=0.19, respectively). The mean CMT decreased significantly at one year after baseline.

Conclusion: This study confirms that administration of intravitreal bevacizumab is a safe and effective treatment modality for mCNV. Statistically significant visual improvement can be obtained.

KEY WORDS

Myopic CNV, Bevacizumab

.....

* Department of Ophthalmology
University Hospitals Leuven
Belgium

Submitted: 23-07-2010

Accepted: 10-09-2010

INTRODUCTION

Degenerative or pathological myopia (PM) is a progressive retinal degeneration seen in high myopia (< -6.00 diopters, axial length > 26.5 mm) and pathologic myopia (< -8 diopters, axial length > 32.5 mm) and is one of the leading causes of blindness in the world (1). Approximately 0.5% of the general population has high or pathological myopia. Progressive anteroposterior elongation of the globe is associated with secondary changes involving the sclera, retina, choroid and optic nerve head. Maculopathy is the most common cause of visual loss in highly myopic patients (2). Choroidal neovascularization due to PM (mCNV) commonly occurs in young patients and bilateral involvement is frequent (12 to 40%) (2). CNV is usually subfoveal or very near the center of the fovea at the time of presentation. The CNV presents as a light grey lesion with overlying serous detachment. A pigmented circle will rapidly outline the lesion. A subgroup of the lesions will become densely pigmented and will remain stable and small. The other part of the lesions will show rapid extension with active leakage. As time passes, a scar develops and often lies within a large area of chorioretinal degeneration with pigmentation, fibrosis and atrophy. These atrophic changes are associated with a poor prognosis.

Different therapeutic approaches have been reported to keep the scar and the chorioretinal degeneration as small as possible. In our department prior to 2008, subfoveal lesions were primarily treated with verteporfin photodynamic therapy (PDT), and laser photocoagulation was used for extrafoveal lesions. Since 2008, intravitreal bevacizumab (IVB) has been used to treat both subfoveal and extrafoveal CNV.

The current study is a retrospective study to determine whether 1.25 mg IVB, administered on an as-needed basis, is efficacious and safe in the treatment of mCNV. The primary endpoints were the best-corrected visual acuity (BCVA) at 3, 12, 18 and 24 months. Secondary endpoints were central macular thickness (CMT) at the same time points, and safety during the entire follow-up period.

METHODS

A retrospective chart review was performed of 29 eyes of 29 patients treated with 1.25 mg IVB for mCNV and followed for at least one year. All eyes had myopia with a minimum refractive error of -8 diopters and had macular CNV, as detected on fluorescein angiography (FA). Of the 29 included eyes, 12 eyes had undergone prior ocular treatment with PDT before inclusion in the study. The included eyes had not undergone any other treatments for mCNV. Ten eyes had a follow-up of at least 12 months but less than 18 months (Group 1; mean 14.5-month follow-up), 11 eyes had at least 18 months of follow-up but less than 24 months (Group 2) and 8 eyes were followed for 24 months or more (Group 3). All patients were informed of the benefits, risks, off-label nature, and alternatives to bevacizumab treatment before treatment was initiated.

EXAMINATIONS

Each patient underwent complete ocular examination, including BCVA using the Early Treatment of Diabetic Retinopathy Study, ETDRS protocol, optical coherence tomography (OCT) (Cirrus HD-OCT, Carl Zeiss Meditec, Jena, Germany) and FA with a conventional digitalized fundus camera (Topcon TRC-50DX Fundus Camera, Itabashi, Tokyo, Japan) at baseline. BCVA, OCT and dilated color fundus photographs were repeated at each follow-up visit. FA was repeated based on a decrease in visual acuity, presence of new hemorrhage, and/or increased CMT or recurrence of macular edema on OCT.

INTRAVITREAL BEVACIZUMAB

Patients received 1.25 mg/0.05ml intravitreal bevacizumab injections (Avastin[®], Roche, Basel, Switzerland) using the standard intraocular injection protocol of the medical retina department of the Department of Ophthalmology at Leuven University Hospital, following the instillation of topical anesthetic drops under sterile conditions. Povidone-iodine 10% solution (Braunol[®], B. Braun Medical, Diegem, Belgium) was applied to the periocular area;

povidone-iodine 5% (IsoBetadine Ophta®, Meda Pharma, Solna, Sweden) solution was applied to the eye. Bevacizumab was injected into the vitreous cavity using a 30-gauge needle inserted through the inferotemporal pars plana 3.5 mm posterior to the limbus. Immediately after the injection, one drop of ofloxacin (Trafloxal®, Dr. Mann Pharma, Berlin, Germany) was administered. Patients were instructed to instill ofloxacin eye drops into the injected eye three times daily for three days after the intravitreal injection.

After the first IVB, the patients were followed up at 4-week intervals. This interval was gradually extended to a maximum of three months between visits, applying an “evaluate-and-extend” regimen. Retreatment was based on any decrease in BCVA, as evaluated by the ETDRS protocol, an increase in CMT of > 100 µm on OCT, the recurrence of macular edema on OCT and/or leakage on FA. Further, patients were advised to return to the clinic in between scheduled appointments for evaluation if they experienced a loss of vision or increased metamorphopsia.

For the purpose of statistical analysis, ETDRS visual acuity data were converted into equivalent logarithms of the minimum angle of resolution (log MAR) values. Data were analyzed using the paired two-sample t-test for means.

A p-value of less than 0.05 was considered to be statistically significant.

RESULTS

Twenty women (69%) and nine men (31%) with a mean age of 62.2 years (range 31-85) were included in this study. Prior ocular treatment included 1 to 3 sessions of PDT in 12 patients (2 in Group 1, 5 in Group 2 and 5 in Group 3). One patient in Group 2 had undergone vitrectomy for an epiretinal membrane 2 years before baseline.

Mean logMAR best-corrected visual acuity (BCVA) at baseline for all patients (n=29) was **0.71** (Snellen equivalent 20/100-; 9 lines). At three months after baseline, the mean logMAR BCVA was **0.56** (20/80+; 10.5 lines). At one year, we found a mean logMAR BCVA of **0.50** (20/63; 11 lines) for all patients. Those patients with 18 months of follow up (Groups 2 and 3; n=19) had a mean logMAR BCVA of **0.59** (20/80+; 10 lines) at 18 months after baseline. At 2 years after baseline, patients out of Group 3 (n=8) had a mean logMAR BCVA of **0.50** (20/63; 11 lines) (Table 1).

An average of 2.1 injections were administered over 12 months, 2.63 injections over 18 months and 4.12 over 24 months. Younger age was associated with a requirement for more frequent

Table 1. Mean visual acuity at baseline and at each of the main time points after initial intravitreal bevacizumab treatment for myopic choroidal neovascularization (Snellen equivalent)

Patient group	Baseline	Three months	One Year	Eighteen months	Two years
Group 1 (n= 10)	20/100-	20/63-	20/50-	/	/
Group 2 (n=11)	20/100	20/63-	20/80	20/80-	/
Group 3 (n= 8)	20/100-	20/80-	20/80+	20/63-	20/63
All patients (n=29)	20/100-	20/80+	20/63	20/80+	20/63

Table 2. Comparing the youngest group of patients (<60 years of age) and the older group of patients (>60 years of age). (BCVA = Best Corrected Visual Acuity in Snellen equivalent).

Patient group	BCVA at baseline	BCVA at 3 months	BCVA at 1 year	BCVA at 18 months	BCVA at 2 years	Number of injections
Younger group (n= 13)	20/118	20/100	20/74	20/118	20/63	3.25
Older group (n=16)	20/95	20/57	20/57	20/61	20/63	2.59

Table 3. The need of bevacizumab during the first 12 months, between 12 and 18 months and after 18 months.

	<i>Number of injections during the first 12 months</i>	<i>Number of injections between 12 and 18 months</i>	<i>Number of injections after the first 18 months</i>
Group 2 (n=11)	24	5	/
Group 3 (n=8)	17	4	12

Table 4. Mean visual acuity at baseline and at each of the main time points after initial intravitreal bevacizumab treatment for myopic choroidal neovascularization (Snellen equivalent). A group of 12 patients had a prior treatment of photodynamic laser treatment (PDT). Another group of 17 patients did not have a PDT before the first intravitreal bevacizumab.

<i>Patient group</i>	<i>Baseline</i>	<i>Three months</i>	<i>One Year</i>	<i>Eighteen months</i>	<i>Two years</i>
Prior PDT (n=12)	20/125	20/100+	20/80	20/100+	20/100
No PDT (n=17)	20/100+	20/63	20/50	20/80+	20/32+
All patients (n=29)	20/100-	20/80+	20/63	20/80+	20/63

injections. Patients younger than 60 years (n=12) required an average of 3.25 injections during the first year, while patients who were older than 60 years of age at baseline (n=17) required an average of 2.58 injections during the first year (Table 2). This difference was however not statistically significant (p=0.46).

In Group 2, 3 out of 11 patients needed injections after the first year of follow-up. Two patients needed 1 additional injection between 12 and 18 months, a third patient needed 3 additional injections in that period. In Group 3, half of the patients (4 out of 8) needed injections after the first year of follow-up: two patients had 3 additional injections, and two patients required 5 additional injections (Table 3). Combining Group 2 with Group 3, there were 37% of the patients who received bevacizumab in the second year and the number of additional injections was between 1 and 5. Seventy one percent of the patients requiring of bevacizumab injection after the first year were 60-year old or older.

Twelve patients (2 in Group 1, 5 in Group 2 and 5 in Group 3) had a prior ocular treatment with 1 to 3 sessions of PDT (Table 4). The mean visual acuity of these patients was worse at baseline and at each of the main time points, compared with the group of patients without a history of PDT.

Mean visual acuity for all 29 patients had improved significantly at 3 months (p=0.0035) and at one year (p=0.0042) after baseline. Although visual acuity gains were maintained at 18 and 24 months, these were not statistically significant (p=0.11 and p=0.19, respectively).

The mean CMT for all patients was 343.9 μm at baseline, 321.7 μm at three months and 292.7 μm at one year. This decrease was statistically significant at one year (p=0.024). For Groups 2 and 3, the mean CMT decreased from 332.3 μm at baseline to 304.1 μm at eighteen months (p=0.17). For Group 3, the mean CMT also decreased, from 316.6 μm at baseline to 275.5 μm at two years (p=0.25) (Table 5).

Table 5. Mean central macular thickness measurements (μm)

<i>Patient group</i>	<i>Baseline</i>	<i>Three months</i>	<i>One Year</i>	<i>Eighteen months</i>	<i>Two years</i>
Group 1 (n= 10)	366	312	276	/	/
Group 2 (n=11)	343	324	320	299	/
Group 3 (n= 8)	316	330	275	311	275
All patients (n=29)	344	322	293	304	275

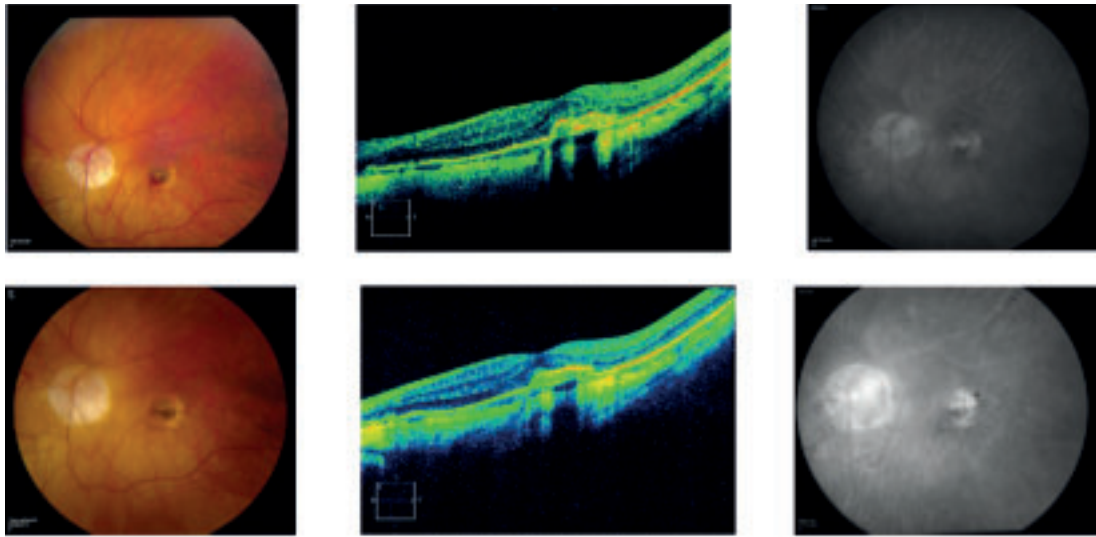


Fig. 1: Patient (male, 54 years) with in his left eye a mCNV. On 2006 and 2007 he received 4 sessions of PDT. On 28/02/2008 he had an active mCNV with blood and edema. The VA was 20/80 (Top). He received a single intravitreal injection with bevacizumab the same day and on the next examination, the CNV was inactive. Two years later, there was still an inactive membrane (VA 20/40) (bottom).

A total of 83 injections were administered. No peri- or post-injection ocular or systemic side effects were noted in either group.

DISCUSSION

Choroidal neovascularization due to pathologic myopia (mCNV) is the most common cause of visual loss in highly myopic patients. If left untreated, 60-73% of the patients with a mCNV, end with a final visual acuity of less than 20/100 (3,4). This loss of vision is mainly caused by the development of chorioretinal atrophy around the regressed mCNV (5). In former years, before the availability of anti-VEGF drugs, these choroidal membranes were treated with lasertherapy (for extrafoveal lesions) or with verteporfin photodynamic therapy (PDT) (for subfoveal lesions). This treatment was based on the results of the Verteporfin in Photodynamic Therapy (VIP) study, a randomized and controlled PDT study in patients with mCNV (6). The VIP study showed a beneficial effect of PDT with verteporfin after 1 year, but failed to prove a statistically significant benefit for mCNV at the end of the second year. At present most patients with mCNV are treated with intravitreal anti-VEGF injections. A retrospective study in

142 eyes compared anti-VEGF monotherapy to PDT monotherapy and combined PDT/anti-VEGF (7). The best visual results were obtained in patients treated with anti-VEGF monotherapy. Another study comparing anti-VEGF and PDT, found a significantly better BCVA in the anti-VEGF group comparing with the PDT group ($p=0.021$) (8). Moreover, the CNV size decreased after treatment with anti-VEGF and remained unchanged or increased after PDT.

The currently used anti-VEGF drugs are either ranibizumab or bevacizumab. Several studies reported on mCNV treated with ranibizumab, showed a statistical significant gain of BCVA at 1 year (9,10). Bevacizumab has also been used in a number of studies, including our study. Gharbiya et al found no statistically significant difference in the BCVA improvement, as well as in the CMT, between bevacizumab and ranibizumab for the treatment of mCNV in a series of 32 patients randomized 1/1 and follow-up for up to 6 months (11).

The short term efficacy of bevacizumab for mCNV is well known (7-8,12-16). At present, long term results become available with evidence that bevacizumab is a valuable treatment op-

tion despite the fact that the drug is used off-label. We used the off label drug Avastin initially in mCNV because ranibizumab was not available and later because the Belgian social security system only reimburses ranibizumab for the AMD indication.

Among the studies with a follow-up of 24 months, several showed a significant gain in BCVA at the end of the second year. Gharbiya et al followed 20 eyes for 2 years and at 24 months after treatment, the mean BCVA improved significantly ($p < 0.05$) (17). Voykov et al found an improvement of BCVA in the bevacizumab monotherapy group of 16 eyes after 2 years ($p < 0.06$) (18). Baba et al equally included 24 patients and found a significant change in the BCVA from the baseline BCVA ($p=0.003$) (19).

In other studies, including our study, the gain in BCVA was initially significant, but was no longer significant by the end of the second year (1). In our study, the mean visual acuity for all 29 patients had improved significantly at 3 months ($p=0.0035$) and at one year ($p=0.0042$). A gain of visual acuity was maintained at 18 and 24 months, but values were not statistically significant ($p=0.11$ and $p=0.19$, respectively). A low number of study patients reached 18 and 24 months follow-up and this could be one of the reasons of non statistical significant gain at the end of the follow-up.

The best guarantee to maintain the gain of vision is by organizing a careful follow-up with examination of BCVA, fundus and OCT. This should be effected initially monthly and in patients with inactive CNV for two repeated examinations, every 2 or 3 months. This scheme has to be followed for at least 2 years. In our study, 7 out of 19 eyes with a follow-up of 18 to 24 months (37%), required retreatment after the first year. Five of these seven patients were older than 60 years of age.

We also measured the central macular thickness during follow-up. The data are comparable with the findings of the BCVA. Also here, the decrease in macular thickness comparing baseline CMT, was significant at one year ($p=0.024$). At 18 and 24 months, the decrease

was maintained, but did not decrease further ($p=0.17$ at 18 months and $p=0.25$ at 24 months).

In our study, we found out that the patients younger than 60 years of age, required on average 3.25 injections of bevacizumab during the first year, while patients who were older than 60 required on average 2.58 injections during the first year (Table 3). This difference was not statistically significant ($p=0.46$). In most previously published studies however, it were the older patients who needed more injections. Younger age was also shown to be associated with a better prognosis (5, 20-22). To our knowledge, this is the first study that found a higher need of treatment in the younger patient group. Presumably, the small study group ($n=29$) is a bias in this conclusion.

Despite the fact that it is not yet known whether anti-VEGF treatment will favorably alter the natural history of the disease after many years, a number of studies are indicative that treatment is better than natural history. So far we can predict to our patients with mCNV that treatment with anti-VEGF injections will probably induce a gain in BCVA in the first year, which is maintained to some level in the next year. To maintain the visual gain, careful follow-up examinations are required and retreatment has to be considered as long as the mCNV is active. Activity of the membrane has to be searched for and requires a combination of biomicroscopic examination of the macula, examination of VA, OCT, and fluorescein angiography.

REFERENCES

- (1) RUIZ-MORENO J.M., MONTERO J.A. – Intra-vitreal bevacizumab to treat myopic choroidal neovascularization: 2-year outcome. *Graefes Arch Clin Exp Ophthalmol* 2010; 248: 937-41
- (2) COSCAS G., SOUBRANE G. – Pathologic Myopia. Chapter 13, *Retinal Imaging* 2006; 165-174.
- (3) AVILA M.P., WEITER J.J., JALKH A.E., TREME C.L., et al. – Natural history of choroidal neovascularization in degenerative myopia. *Ophthalmol* 1984; 91: 1573-81.
- (4) HAYASHI K., OHNO-MATSUI K., SHIMADA N. et al. – Long-term pattern of progression of

- myopic maculopathy: a natural history study. *Ophthalmol* 2010; 117: 1595-1611.
- (5) YOSHIDA T., OHNO-MATSUI K., YASUZUMI K. et al. – Myopic choroidal neovascularization: a 10-year follow-up. *Ophthalmol* 2003; 110: 1297-305.
 - (6) BLINDER K.J., BLUMENKRANZ M.S., BRESSLER N.M. et al. – Verteporfin therapy of subfoveal choroidal neovascularization in pathologic myopia: 2-year results of a randomized clinical trial-VIP report no. 3. *Ophthalmol* 2003; 110: 667-673.
 - (7) YOON J.U., BYUN Y.J., KOH H.J. – Intravitreal anti-VEGF versus photodynamic therapy with verteporfin for treatment of myopic choroidal neovascularization. *Retina* 2010; 30: 418-24.
 - (8) HAYASHI K., OHNO-MATSUI K., TERAMUKAI S. et al. – Comparison of visual outcome and regression pattern of myopic choroidal neovascularization after intravitreal bevacizumab or after photodynamic therapy. *Am J Ophthalmol* 2009; 148: 396-408.
 - (9) LALLOUM F., SOUJED E.H., BASTUJI-GARIN S. et al. – Intravitreal ranibizumab for choroidal neovascularization complicating pathologic myopia. *Retina* 2010; 30: 399-406.
 - (10) SILVA R.M., RUIZ-MORENO J.M., ROSA P. et al. – Intravitreal ranibizumab for myopic choroidal neovascularization. 12-Month results. *Retina* 2010; 30: 407-12.
 - (11) GHARBIYA M., GIUSTOLISI R., ALLIEVI F. et al. – Choroidal neovascularization in pathologic myopia: Intravitreal ranibizumab versus bevacizumab - A randomized controlled trial. *Am J Ophthalmol* 2010; 149: 458-64.
 - (12) SPIELBERG L., LEYS A. – Intravitreal bevacizumab for myopic choroidal neovascularization: short-term and 1-year results. *Bull Soc Belge Ophthalmol* 2009; 312: 17-27.
 - (13) YAMAMOTO I., ROGERS A.H., REICHEL E., YATES P.A., DUKER J.S. – Intravitreal bevacizumab (Avastin) as treatment for subfoveal choroidal neovascularisation secondary to pathological myopia. *Br J Ophthalmol* 2007; 91: 157-160.
 - (14) SAKAGUCHI H., IKUNO Y., GOMI F. et al. – Intravitreal injection of bevacizumab for choroidal neovascularisation associated with pathological myopia. *Br J Ophthalmol* 2007; 91: 161-165.
 - (15) GHARBIYA M., ALLIEVI F., MAZZEO L., GABRIELI C.B. – Intravitreal bevacizumab treatment for choroidal neovascularization in pathologic myopia: 12-month results. *Am J Ophthalmol* 2009; 147: 84-93.
 - (16) IKUNO Y., SAYANAGI K., SOGA K. et al. – Intravitreal bevacizumab for choroidal neovascularization attributable to pathological myopia: one-year results. *Am J Ophthalmol* 2009; 147: 94-100.
 - (17) GHARBIYA M., ALLIEVI F., CONFLITTI S., ESPOSITO M., SCAVELLA V., MORAMARCO A., CRUCIANI F. – Intravitreal bevacizumab for treatment of myopic choroidal neovascularization: the second year of a prospective study. *Clin Ter* 2010; 161: 87-93.
 - (18) VOYKOV B., GELISKEN F., INHOFFEN W. et al. – Bevacizumab for choroidal neovascularization secondary to pathologic myopia: Is there a decline of the treatment efficacy after 2 years? *Graefes Arch Clin Exp Ophthalmol* 2010; 248: 543-50.
 - (19) BABA T., KUBOTA-TANIAI M., KITAHASHI M. et al. – Two-year comparison of photodynamic therapy and intravitreal bevacizumab for treatment of myopic choroidal neovascularisation. *Br J Ophthalmol* 2010; 94: 864-870.
 - (20) HAYASHI K., OHNO-MATSUI K., YOSHIDA T. et al. – Characteristics of patients with a favorable natural course of myopic choroidal neovascularization. *Graefes Arch Clin Exp Ophthalmol* 2005; 243:13-9.
 - (21) KOJIMA A., OHNO-MATSUI K., TERAMUKAI S. et al. – Estimation of visual outcome without treatment in patients with subfoveal choroidal neovascularization in pathologic myopia. *Graefes Arch Clin Exp Ophthalmol* 2006; 244: 1474-9.
 - (22) AXER-SIEGEL R., EHRlich R., WEINBERGER D. – Photodynamic therapy of subfoveal choroidal neovascularization in high myopia in a clinical setting: visual outcome in relation to age at treatment. *Am J Ophthalmol* 2004; 138: 602-7.
-
- Adress for correspondence:
Dr. Greet COPPENS
Greetcoppens@hotmail.com*