
ORBITAL INFLAMMATION AFTER USE OF ZOLEDRONIC ACID FOR METASTASIZED PROSTATE CARCINOMA

MISSOTTEN G.^{1,2}, VERHEEZEN Y.³

ABSTRACT

Report of a case of orbital inflammation after the use of zoledronic acid for metastasized prostate cancer.

KEY WORDS

orbital inflammation, orbit, ocular oncology, zoledronic acid, bisphosphonates

CASE REPORT

A 71-year old male was referred to the ophthalmology department with swelling of upper and lower eyelids and conjunctiva, redness of the right eye and pain. There were no complaints of the left eye.

Twenty two years earlier, a neurofibroma was excised extraconally in the right orbit. Since, there was a limited proptosis of the right eye and diplopia in extreme abduction.

At clinical examination, a mild eyelid swelling, a chemosis of the conjunctiva and a subconjunctival hemorrhage was present. Best Corrected Visual acuity was 0.8 on both sides. There was no anterior uveitis. Fundus examination results were normal OU. Exophthalmometry measured 3 mm proptosis of the right eye. Computed Tomography (CT) showed proptosis, fat stranding, but no identifiable mass in the right orbit (figure 1). Ultrasound did not show signs of scleritis OD. Blood screening showed no abnormalities, except a decreased Thyroid Stimulating Hormone (TSH). The inflammation of the right orbital tissue was just diagnosed at the end of a treatment with intravenous zoledronic acid for metastasized prostate carcinoma (with bone metastases). As such, a bisphosphonate-triggered orbital inflammation was diagnosed. The bisphosphonates were discontinued and oral prednisone 32 mg was started for 3 weeks. Within five days the symptoms disappeared, and did recur with a follow-up of 7 months.

DISCUSSION

Bisphosphonates are considered as the treatment of choice for Paget's disease, malignant

.....

1. Dept Ophthalmology, Virga Jesse Ziekenhuis, Hasselt, Belgium
2. Dept Ophthalmology, Ocular Oncology Unit, Catholic University Leuven, Belgium
3. Dept Oncology, Virga Jesse Ziekenhuis, Hasselt, Belgium

Submitted: 01-04-2010

Accepted: 08-09-2010

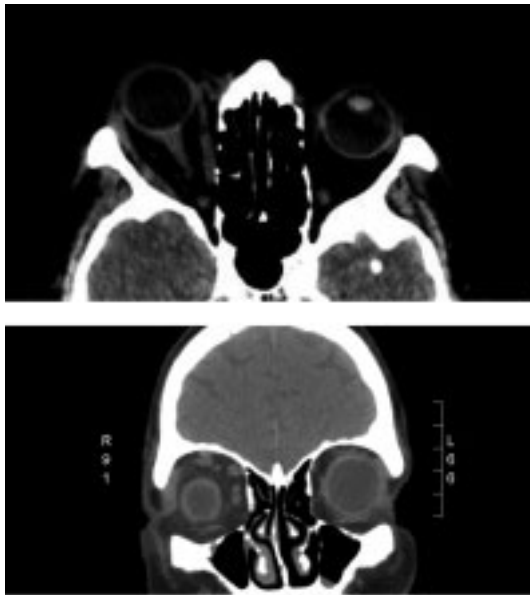


Fig. 1: Computed Tomography of the orbit, showing 3 mm proptosis of the right eye after the use of zoledronic acid. Extraocular muscles were not enlarged and not associated with any signs of myositis. The optic nerve and tear gland appeared normal.

hypercalcemia, bone metastases and osteoporosis. Nitrogen-containing bisphosphonates (zoledronic acid, pamidronate disodium, risedronate sodium, alendronate sodium) have been described to occasionally induce eye symptoms such as anterior uveitis (1), acute retinal pigment epitheliitis and acute retinal epithelial detachment (2), scleritis (3), optic neuropathy (4) and rarely orbital inflammation (3,5). In almost all cases with (peri-) ocular side effects, a monocular involvement was documented. In the reported cases, the orbital inflammation had occurred very quickly following bisphosphonate therapy, with retrobulbar pain and proptosis as main characteristics. Only one case of bilateral orbital inflammation had been reported in the literature (5).

In most cases of scleritis, the scleritis did not resolve until discontinuation of the bisphosphonate. It is probably prudent to switch to non-nitrogen containing bisphosphonates or other alternatives if ocular symptoms are found.

In this case, a decreased TSH was found. The sudden onset and quick (within days) resolution of the proptosis after bisphosphonates were

stopped and steroids were started, and the absence of muscle involvement on CT, did not suggest a role for thyroid-associated orbitopathy. In this case, the inflammation was restricted to the orbital fat and a dilatation of the blood vessels.

In conclusion, in patients receiving bisphosphonates, close attention should be given to ocular signs or symptoms (1).

REFERENCES

- (1) TAN Y.L., SIMS J., CHEE S.P. – Bilateral uveitis secondary to bisphosphonate therapy. *Ophthalmologica* 2009; 223: 215-216.
- (2) DASANU C.A., ALEXANDRESCU D.T. – Acute retinal pigment epithelial detachment secondary to pamidronate administration. *J Oncol Pharm Pract* 2009; 15: 119-121.
- (3) FRAUNFELDER F.W., FRAUNFELDER F.T., JENSVOLD B. – Scleritis and other ocular side effects associated with pamidronate disodium. *Am J Ophthalmol* 2003; 135: 219-222.
- (4) SUBRAMANIAN P.S., KERRISON J.B., CALVERT P.C., MILLER N.R. – Orbital inflammatory disease after pamidronate treatment for metastatic prostate cancer. *Arch Ophthalmol* 2003; 121: 1335-1336.
- (5) SHARMA N.S., OOI J.L., MASSELOS K., HOOPER M.J., FRANCIS I.C. – Zoledronic acid infusion and orbital inflammatory disease. *N Engl J Med* 2008; 359: 1410-1411.

.....

Adresse for correspondence:
 G.S. MISSOTTEN, MD, PhD, FEBO,
 Dept Ophthalmology, Catholic University Leuven
 Dept Ophthalmology, Virga Jesse Ziekenhuis, Hasselt
 Tel. 0032 11 22 34 35
 Fax. 0032 11 22 34 35
 guymissotten@jessazh.be or
 guy.missotten@uzleuven.be