

---

# LENTICONUS

JACOBS K.\*, MEIRE F.M.\*

---

## ABSTRACT

Lenticonus is a bulging of the lens capsule and the underlying cortex. The diagnosis of lenticonus is essentially a clinical diagnosis which is made by biomicroscopic examination. According to the localization of the conus a distinction is made between lenticonus anterior and lenticonus posterior.

Whereas lenticonus anterior is part of the Alport syndrome, lenticonus posterior is not associated with systemic disease. A case report of each of both types is presented and the clinical presentation, the aetiology, the pathogenesis and the treatment are discussed.

## RÉSUMÉ

Un lenticône est caractérisé par une courbure localisée de la capsule lenticulaire et du cortex sous-jacent. Le diagnostic de lenticône est principalement un diagnostic clinique par examen biomicroscopique. Selon la localisation on distingue le lenticône antérieur et le lenticône postérieur. Le lenticône postérieur n'est pas lié à une maladie systémique, mais par contre le lenticône antérieur fait partie du syndrome d'Alport. Nous présentons un cas de chaque forme et nous en discutons la clinique, l'étiologie, la pathogénèse et le traitement.

## SAMENVATTING

Lenticonus is een gelokaliseerde uitbochting van het lenskapsel en de onderliggende lenscortex.

De diagnose van lenticonus is voornamelijk een klinische diagnose die door biomicroscopisch onderzoek wordt gesteld. Naargelang de lokalisatie van de conus wordt een onderscheid gemaakt tussen lenticonus anterior en lenticonus posterior. Lenticonus posterior is niet geassocieerd met systeemlijden; len-

ticonus anterior daarentegen maakt deel uit van het syndroom van Alport. We stellen een casus voor van beide vormen en we bespreken de kliniek, de etiologie, de pathogenese en de behandeling.

## KEY WORDS

Lenticonus anterior, lenticonus posterior, Alport syndrome.

## MOTS CLÉS

Lenticône antérieur, lenticône postérieur, syndrome d'Alport.

.....

\* *Departement of Ophthalmology, Ghent University Hospital*

received: 07.04.00

accepted: 09.06.00



Fig. 1: «Oil droplet» configuration, seen by retro-illumination in the early stage of lenticonus.

## INTRODUCTION

The lens is surrounded by the lens capsule which is a basement membrane secreted by the epithelial cells. As in all basement membranes the lens capsule is mainly composed of type IV collagen.

*Lenticonus* is a localized bulging of the lens capsule and the underlying cortex, that can reach a diameter of 2 to 7 mm. The conus may occur anteriorly or posteriorly. Lenticonus is differentiated from *lentiglobus* in which the bulging involves the entire lens surface.

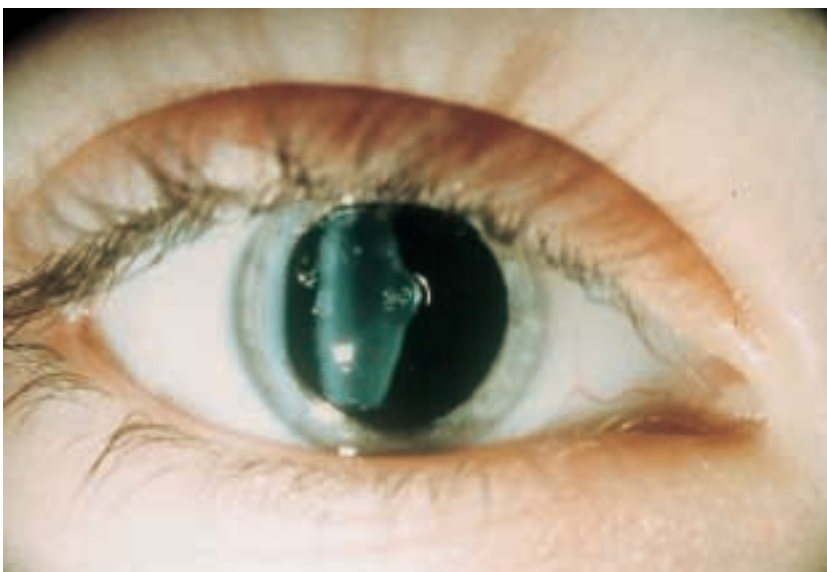

Fig. 2: Image of a conus, observed when using a narrow slit.

Biomicroscopically lenticonus is characterized by a transparent, localized, sharply demarcated conical projection of the lens capsule and cortex, usually axial in localization. In an early stage, retro-illumination shows an «oil droplet» configuration (fig 1). Using a narrow slit, the image of a conus is observed (fig 2). In a more advanced stage associated subcapsular and cortical opacities appear.

Retinoscopically the oil droplet produces a pathognomonic scissors movement of the light reflex. This phenomenon is due to the different refraction in the central and the peripheral area of the lens (fig 3).

Ultrasonography also can illustrate the existence of a lenticonus. A-scan ultrasonography may reveal an increased lens thickness and B-scan ultrasonography may show herniated lenticular material, suggestive of a lenticonus.

Amblyopia, cataract, strabismus and loss of central fixation may be observed in association with lenticonus posterior. Cataract, flecked retinopathy, posterior polymorphous dystrophy and corneal arcus juvenilis may be encountered in association with lenticonus anterior that occurs as a part of the Alport syndrome. We will discuss both types of lenticonus.

## CASE REPORTS

Two patients who respectively presented with lenticonus posterior and lenticonus anterior, are discussed.

### CASE REPORT 1

A 20-months-old girl was noticed by her mother to present strabismus. Ophthalmological examination revealed an eso- and hypertropia of the right eye, the central fixation was lost and the eye was obviously amblyopic. At the left eye the Teller visual acuity was 13.0 cy/cm at 55cm, which is a normal value at the age of 20 months. Slitlamp examination showed at the right eye a posterior lenticonus with posterior cortical opacities (fig 2). At the left eye the anterior segment was normal. Examination of the fundus

.....

\* Surgery was performed by Prof. Dr. M. J. Tassignon

showed no abnormalities. A few weeks later lens extraction, anterior vitrectomy and implantation of an IOL was performed \*. Postoperatively the parents refused occlusion therapy and an improvement of the visual acuity did not occur. Three months after surgery the visual acuity (by pictures) still was 1/100 at the right eye and a YAG capsulotomy had to be performed because of secondary cataract.

### CASE REPORT 2

A 47-years-old woman, known to be affected with X-linked dominant Alport syndrome, was

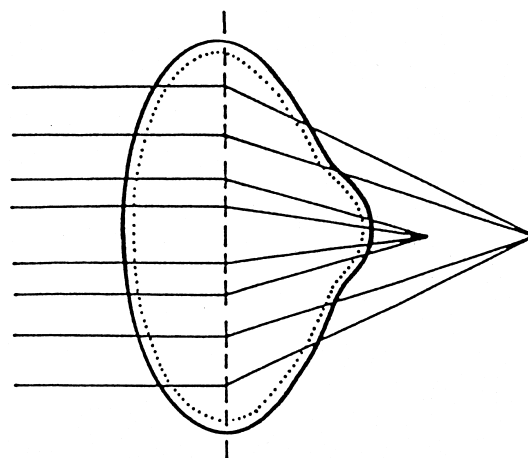


Fig. 3: Ray tracing of light in case of posterior conus. The difference in refraction of the central (myopic) and the peripheral (hyperopic) area will cause the scissors movement of the light reflex as seen retinoscopically.

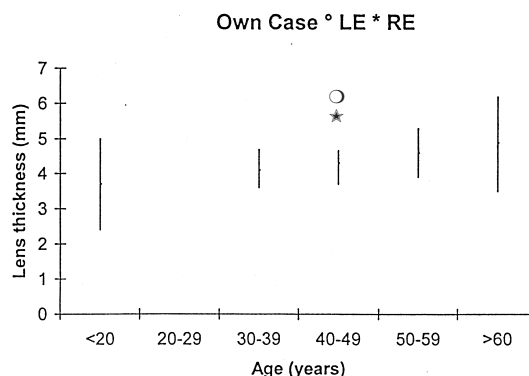


Fig. 4: Lens thickness in relation to age and lens thickness in our patient with Alport syndrome.

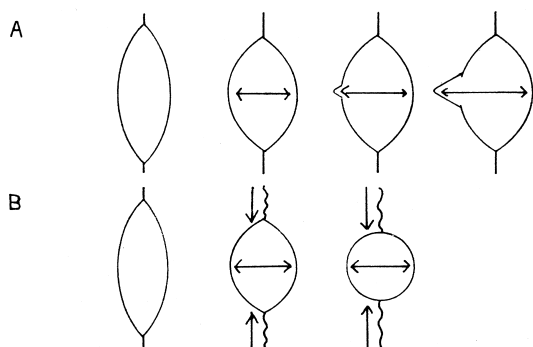


Fig. 5: Evolution of the lens morphology in lenticonus anterior (A) and spherophakia (B).

referred to us by the nephrologist to exclude ocular involvement. The patient did not mention ocular problems. The Snellen visual acuity was 10/10 at both eyes, with a correction of +2.25 at the right eye and +1.75 (-1.5 à 30°) at the left eye. Slitlamp examination showed anterior cortical opacities in both eyes. Examination of the fundus showed no abnormalities. Although an anterior lenticonus was not observed, an A-scan ultrasonography proved a significant increase of the lens thickness in both eyes: 5.71mm at the right eye and 6.13mm at the left eye (normal value: 4.33mm ± 0.35mm) (FIG 4). The anterior chamber depth was 3.64mm at the right eye and 3.41mm at the left eye. The axial length was 22.10mm at the right eye and 22.36mm at the left eye.

## DISCUSSION

### LENTICONUS POSTERIOR

Most authors agree that lenticonus posterior is a congenital defect, which is not associated with systemic disease (1, 16). In most patients the anomaly occurs unilaterally in a sporadic manner (1, 4, 6). Bilateral involvement strongly suggests autosomal dominant inheritance (1, 4, 6, 13, 15). In most cases of lenticonus posterior the age at diagnosis lies between 3 and 7 years (13). The prevalence is estimated at 1 to 4 of every 100.000 children (1). No predilection for either sex is demonstrated (1, 4). Amblyopia is the most significant visual problem associated with posterior lenticonus (1, 4).

Amblyopia is caused by optical distortion in the «oil droplet» stage, by anisometropia or by deprivation due to cataract (1). With time all patients develop cataractous changes at the level of the lenticonus, which eventually can spread to the adjacent subcapsular cortex (1, 4). Strabismus is also a frequent accompanying defect in children with lenticonus posterior (1, 4). The occurrence of strabismus is probably related to the age of onset of sensory deprivation (1). Rarely an infant with lenticonus shows leukocoria. In this case, the presence of a retinoblastoma has to be excluded (5).

The pathogenesis of lenticonus posterior remains unclear. Traction on the posterior lens capsule by remnants of the hyaloid artery system as well as a disturbance in the tunica vasculosa lentis have been suggested (11). Other hypotheses include vitritis or an overgrowth of posterior lens fibers that produce a phakoma of the lens (4). Although many theories have been proposed, none of them could be proved (1, 4). In bilateral cases a genetically determined congenital weakness of the posterior lens capsule is likely (10).

Lenticonus posterior may have a profound effect on the visual acuity as it occurs in children, who are susceptible to develop amblyopia (1, 4). To treat amblyopia occlusion therapy is always mandatory. Pupillary dilatation is also recommended to provide a consistent refraction of the light rays peripheral to the area of the lenticonus. If cycloplegic agents are used, a bifocal correction is needed for near visual tasks. With this treatment, 1 year follow-up showed an improved vision in 41% (9/22) of the children (1). Indications for lens surgery are: a visual acuity of 20/100 or less, a loss of the central fixation or amblyopia not reacting on occlusion therapy (1).

In 1978 Crough et al (4) published the results of 19 eyes treated for posterior lenticonus between 1962 and 1977. The treatment consisted of surgical aspiration of the lens, contact lens therapy and amblyopia management. Final visual acuity of 20/50 or better occurred in 63% (12/19). In the age group «0 to 4 years» 75% (9/12) had 20/50 or better vision. In the age group «over 5 years» only 43% (3/7) had 20/50 or better vision.

In 1991 Cheng et al (1) reported 41 eyes treated for posterior lenticonus in the 1974 - 1988

period. The treatment consisted of surgical aspiration of the lens, implantation of an IOL and amblyopia management. Visual acuity obtained within the first 6 postoperative months after cataract extraction was improved over preoperative visual acuity by 2 or more Snellen lines in 43% (15/35) of the patients tested. The best visual acuity observed during the entire follow-up period indicated that 49% (19/39) of the eyes achieved postoperative visual acuity of 20/20 to 20/40 and 10% (4/39) < 20/200. Longstanding follow-up in both studies showed an important loss of visual acuity due to recurrent amblyopia for which reason occlusion therapy should be continued postoperatively (1).

#### LENTICONUS ANTERIOR

Lenticonus anterior occurs bilaterally in patients with the Alport syndrome, which is a hereditary systemic disease with a prevalence of 1/5000 in a normal population. Of all patients 85% have the X-linked form, 10% the autosomal recessive form and only a small fraction the autosomal dominant form (2, 3).

The Alport syndrome is characterized by progressive renal failure, sensorineural deafness and ocular manifestations, which develop in 11 to 43% of the patients (18). The typical ocular associations are a flecked retinopathy (14) and anterior lenticonus, which probably occurs in 25% of patients with X-linked Alport syndrome, although the frequency varies in different series (3). Posterior polymorphous corneal dystrophy is observed in a few patients (2, 3, 18).

The Alport syndrome is caused by mutations affecting the gene that encodes one of the chains of type IV collagen. Type IV collagen is common to the basement membranes of the glomerulus, the cochlea, the lens capsule and the cornea (2, 3, 7). Histopathologic examination shows a thinning of the anterior lens capsule and the presence of vertical dehiscences at the inner part of the central anterior lens capsule (9, 17). Lenticonus anterior in Alport syndrome is not demonstrated in childhood. Initially an increase of the lens thickness is observed in affected patients, proved by performing a biometry of the eye. As the central anterior part of the lens undergoes the greatest changes during accommodation (17) and the lens capsule

is thinner in the central area than in the peripheral area, an anterior lenticonus will develop with time. Subcapsular and cortical cataract may appear at the level of the conus.

The treatment consists of lens extraction with implantation of an IOL (8, 12).

Although the lens thickness in our patient was significantly increased, she obtained a good visual acuity without a myopic correction. We suggest two theories that may explain this phenomenon. First of all the patient was slightly hyperopic. We also believe that in Alport syndrome, prior to the central conical protrusion of lens material, the lens thickness increases without a significant increase in the curvature of the lens. Therefore the increase in lens thickness does not cause a marked myopic shift, contrary to the high myopia that is observed in spherophakia, where the curvature of the lens increases significantly because of zonular elongation (FIG 5).

#### CONCLUSION

Lenticonus anterior is acquired. It is part of the Alport syndrome, which is a systemic disease. On the other hand lenticonus posterior is a purely ocular anomaly in which the lenticonus is congenital.

#### REFERENCES

- (1) CHENG KP, HILES DA, BIGLAN AW, PETTA-PIECE MC - Management of posterior lenticonus. *J. Pediatr. Ophthalmol. Strabismus* 1991; 28 : 143-149.
- (2) COLVILLE D, SAVIGE J, MORFIS M, ELLIS J, KERR P, AGAR J, FASSET R - Ocular manifestations of autosomal recessive Alport syndrome. *Ophthalmic Genetics* 1997; 18 : 119-128.
- (3) COLVILLE DJ, SAVIGE J - Alport syndrome. A review of the ocular manifestations. *Ophthalmic Genetics* 1997; 18 : 161-173.
- (4) CROUGH ER jr., PARKS MM - Management of posterior lenticonus complicated by unilateral cataract. *Am. J. Ophthalmol.* 1978; 85 : 503-508.
- (5) FETT D, PAEZ JH, ISENBERG S - Infantile leukocoria caused by posterior lenticonus. *Ann. Ophthalmol.* 1984; 16 : 679-680, 684.
- (6) GIBBS ML, JACOBS M, WILKIE AO, TAYLOR D - Posterior lenticonus: clinical patterns and

- genetics. *J. Pediatr. Ophthalmol. Strabismus* 1993; 30 : 171-175.
- (7) HUDSON BG, REEDERS ST, TRYGGVASON K - Type IV collagen: structure, gene organization and role in human diseases. *J. Biological Chemistry* 1993; 286: 26033-26036.
- (8) JOHN ME, NOBLITT RL, COOTS SD, BOLEYN KL, BALLEW C - Clear lens extraction and intraocular lens implantation in a patient with bilateral anterior lenticonus secondary to Alport's syndrome. *J. Cataract Refract. Surg.* 1994; 20: 652-655.
- (9) KATO T, WATANABE Y, NAKAYASU K, KANAI A, YAJIMA Y - The ultrastructure of the lens capsule abnormalities in Alport's syndrome. *Jpn. J. Ophthalmol.* 1998, 42: 401-405.
- (10) KHALIL M, SAHEB N - Posterior lenticonus. *Ophthalmology* 1984; 91 : 1429-1430, 1443 A.
- (11) KILTY LA, HILES DA - Unilateral posterior lenticonus with persistent hyaloid artery remnant. *Am. J. Ophthalmol.* 1993; 116 : 104-106.
- (12) Mc CARTNEY PJ, Mc GUINNESS R - Alport's syndrome and the eye. *Australian and New Zealand J. Ophthalmol.* 1989; 17 : 165-168.
- (13) MEYERS JS, SCHNALL BM - Bilateral posterior lenticonus. *Ophthalmic. Surg.* 1995; 26 : 383-384.
- (14) PERRIN D, JUNGERS P, GRUNFELD JP, DEL-ONS S, NOEL LH, ZENATTI C - Perimacular changes in Alport's syndrome. *Clin Nephrology* 1980; 13 : 163-167.
- (15) POLLARD ZF - Familial bilateral posterior lenticonus. *Arch. Ophthalmol.* 1983; 101 : 1238-1240.
- (16) SEIDENBERG K, LUDWIG IH - A newborn with posterior lenticonus. *Am. J. Ophthalmol.* 1993; 115 : 543-544.
- (17) STREETEN BW, ROBINSON MR, WALLACE R, JONES DB - Lens capsule abnormalities in Alport's syndrome. *Arch. Ophthalmol.* 1987; 105: 1693-1697.
- (18) THOMPSON SM, DEADY JP, WILLSHAW HE, WHITE HR - Ocular signs in Alport's syndrome. *Eye* 1987; 1: 146-153.
- .....
- Reprint request:*  
*Prof. dr. F.M. MEIRE*  
*Oogheekunde*  
*Universitair Ziekenhuis Gent*  
*De Pintelaan 185*  
*B - 9000 GENT*