

# CLEAR LENS EXTRACTION TO CORRECT HYPEROPIA IN PRESBYOPIC EYES WITH OR WITHOUT ARCUATE KERATOTOMY FOR PRE-EXISTING ASTIGMATISM.

DE SMEDT S.K. \*, VRIJGHEM J.C. \*\*

## ABSTRACT

This retrospective study evaluates visual (functional) and refractive outcome of correcting hyperopia (i.e. 2.5 D or more) by means of a cataract procedure and simultaneously the pre-existing clinical significant astigmatism (1.5 D or more with the rule; 1 D or more against the rule), if present, by means of an arcuate keratotomy.

Nine eyes undergoing clear lens extractions with intraocular lens implantation (IOL) in combination with arcuate keratotomy (group one) and 29 eyes without arcuate keratotomy (group two) are included in the study. The mean age at the time of surgery was 62.89 years (range, 50 to 83) in group one and 68.17 years (range, 53 to 86) in group two. For calculation of the lens power a modified SRK II program, aiming at emmetropia was used. In only one highly hyperopic patient the Holladay I formula was used to calculate two piggyback lenses. A modified Istre nomogram was used to determine the surgical parameters of the arcuate keratotomy. The Cravy formula and the Holladay, Cravy, Koch vector analysis were used to determine the change in refractive cylinder results.

Patients were followed postoperatively for a mean of 2.8 months in group one and 7.5 months in group two. In group one, 6 out of 9 eyes achieved a postoperative refraction within  $\pm 0.5$  D of intended refraction and 8 out of 9 were within  $\pm 1$  D of in-

tended refraction. In group two, it was 15/29 and 24/29 respectively. Postoperatively, the uncorrected visual acuity was 20/40 or better in all eyes of group one (9/9) and in 27/29 eyes of group two. None of the eyes in both groups lost two or more lines of the best corrected visual acuity.

Clear lens extraction with IOL is an effective and safe procedure for the correction of hyperopia in a presbyopic age group. In combination with an arcuate keratotomy, pre-existing astigmatism can be corrected simultaneously.

## RÉSUMÉ

Cette étude rétrospective évalue le résultat visuel (fonctionnel) et réfractif de la correction de l'hypermétropie (de 2.5 dioptries ou plus) et d'un astigmatisme significatif pré-existant dans le même temps opératoire (de 1.5 dioptrie ou plus selon la règle ou de 1 dioptrie ou plus contre la règle).

Neuf yeux, traités par extraction du cristallin clair et implantation d'une lentille intra-oculaire en combinaison avec une kératotomie arciforme (groupe un) et 29 yeux sans kératotomie (groupe deux), ont été inclus dans cette étude. Une formule SRK II modifiée a été utilisée pour le calcul de la puissance de l'implant dans le but d'obtenir l'emmétropie. Dans un cas de très forte hypermétropie la formule Holladay I a permis de calculer deux implants posés en "piggyback". Un nomogramme inspiré par Istre a été employé pour déterminer les paramètres chirurgicaux de la kératotomie arciforme. La formule de Cravy et l'analyse de vecteurs de Holladay, Cravy et Koch ont été utilisés pour déterminer les changements dans les résultats réfractifs cylindriques.

Le suivi postopératoire a été de 2.8 mois en moyenne dans le groupe un, et de 7.5 mois dans le groupe deux. Dans le groupe un, 6 yeux sur 9, avaient une réfraction post-opératoire endéans  $\pm 0.50$  diop-

.....

\* Department of Ophthalmology; University of Leuven, Belgium

\*\* Department of Ophthalmology, St. Jan Hospital, Brussels, Belgium

received: 03.03.00

accepted: 10.05.00

trie de la réfraction visée et 8 yeux sur 9 endéans +/- 1 dioptrie. Dans le groupe deux, ces résultats étaient obtenus sur 15 yeux des 29 et sur 24 yeux des 29 respectivement. En post-opératoire, l'acuité visuelle non-correctée était de 20/40 ou mieux pour tous les yeux du groupe un (9/9) et pour 27 des 29 yeux du groupe deux. Aucun des yeux a perdu 2 ou plus de lignes en acuité visuelle la mieux corrigée. L'extraction du cristallin clair et l'implantation d'une lentille intra-oculaire est une procédure chirurgicale efficace et sûre pour la correction de l'hypermétropie dans un groupe presbyope. En combinaison avec la kératotomie arciforme, l'astigmatisme pré-existant peut être corrigé.

#### KEY WORDS

hyperopia, astigmatism, clear lens extraction, arcuate keratotomy

#### MOTS CLÉS

hyperopie, astigmatisme, extraction du cristallin clair, kératotomie arciforme.

### SAMENVATTING

In deze retrospectieve studie worden de visuele (functionele) en refractieve resultaten geëvalueerd van een heldere lens extractie voor het corrigeren van hypermetropie (minstens 2,5 D) in combinatie met een arciforme keratotomie, indien voorafbestaand een klinisch significant astigmatisme aanwezig (minstens 1,5 dioptrie volgens de regel, of minstens 1 dioptrie tegel) was.

In de studie werden 9 ogen opgenomen die gelijktijdig een heldere lens extractie met intraoculaire lensimplantatie (IOL) en arciforme keratotomie ondergingen (groep één), en 29 ogen zonder arciforme keratotomie (groep twee). Voor de lensberekening werd hoofdzakelijk een aangepast SRK II algoritme gebruikt, en emmetropie werd nagestreefd. Bij slechts één hoog hypermetrope patiënt werd de Holladay I formule gebruikt in de berekening van twee piggyback lenzen. Ter berekening van de chirurgische parameters van de arciforme keratotomie, werd een aangepast Istre nomogram gebruikt. Met de Cravy formule en de Holladay, Cravy, Koch vector analyse werd de feitelijke correctie in refractieve cylinder geëvalueerd.

De patiënten werden postoperatief gemiddeld 2,8 maand opgevolgd in groep één, en 7,5 maand in groep twee. In groep één bereikten 6 van de 9 ogen een postoperatieve refractie binnen +/- 0,5 D van emmetropie, en 8 van de 9 waren binnen +/- 1 D van emmetropie. In groep twee waren deze cijfers respectievelijk 15/29 en 27/29. De postoperatieve visus zonder correctie bedroeg minstens 20/40 voor alle ogen van groep één (9/9), en voor 27/29 ogen van groep twee. In de twee groepen verloor geen enkel oog meer dan twee lijnen van zijn best gecorrigeerde visus.

Clear lens extractie met IOL is een efficiënte en veilige procedure ter correctie van hypermetropie in een oudere leeftijds populatie. In combinatie met een arciforme keratotomie kan voorafbestaand astigmatisme tegelijkertijd gecorrigeerd worden.

## INTRODUCTION

Many surgical procedures to correct hyperopia have been suggested. Pure corneal refractive techniques have been used such as hexagonal keratotomy, automated lamellar keratoplasty, laser thermal keratoplasty (LTK), photorefractive keratectomy (PRK) or laser in situ keratomileusis (LASIK)<sup>1,4-6,10-12,14,15,18,21</sup>. Hexagonal keratotomy is unreliable and risky.<sup>6</sup> Non-contact Holmium LTK might be considered in patients older than 40 years but because of excessive postoperative regression only low degrees of hyperopia (<3 D) can be corrected. Astigmatism cannot be treated using this technique<sup>14,21</sup>. Surface PRK is also limited to low and moderate hyperopia because of the refilling of the ablated ring with epithelium, increasing regression and haze<sup>5</sup>. LASIK is our procedure of choice in a non presbyopic age group, with hyperopia less than 3.5 D. In addition, pre-existing astigmatism can be treated.<sup>1</sup> However, in cases of high hyperopia (>3.5D) LASIK does not have good predictability<sup>4-6,12,14</sup> and induced optical aberrations cause limited satisfaction<sup>4,12,14</sup>.

The alternative is the implantation of a correcting lens into a phakic eye, which seems to be the best solution in patients with high hyperopia, younger than 50. In older patients the treatment of choice is a clear lens extraction with intraocular lens implantation. This procedure was first proposed by Osher in 1989.<sup>17</sup> Although this has proven to be a safe and predictable method in correcting hyperopia, the limiting factor still remains the relative inaccuracy of IOL calculation formulas<sup>4,12,13,16</sup>. In addition, loss of accommodation makes this intervention only suitable for the presbyopic age group.

In case of astigmatism this procedure is combined with arcuate keratotomy.

This study was undertaken to assess the visual (functional) and refractive outcome of correcting hyperopia in 29 eyes without simultaneous correction of the pre-existing astigmatism and in 9 eyes with simultaneous correction of pre-existing astigmatism by means of a cataract procedure alone or combined with an arcuate keratotomy in case of astigmatism. This combined intervention is called keratolenticuloplasty, a term introduced by Kershner<sup>10</sup>.

## PATIENTS AND METHODS

### STUDY DESIGN

In this study we retrospectively evaluated 9 clear lens extractions with posterior chamber IOL implantation in combination with arcuate keratotomy astigmatism correction (group one), and 29 without arcuate keratotomy (group two), performed between November 1996 and July 1999 by a single surgeon (JCV).

The inclusion criteria were moderate to high hyperopia (spherical equivalent of 2.5 D or more), a best corrected visual acuity (BCVA) preoperatively of 20/32 or better, and age 50 or older. In the first group the patients had clinically significant astigmatism, i.e. more than 1 D against the rule, more than 1.5 D with the rule.

### PREOPERATIVE ASSESSMENT

The preoperative examination included best spectacle-corrected visual acuity, manifest refractions, slitlamp and fundus examinations, applanation tonometry and keratometry (Javal). Preoperative candidates underwent an A-scan (SONOMED or TEKNAR ultrasonic biometry), using applanation technique. Calculations of the lens power were computed using mainly a modified SRK II program, aiming for emmetropia. (If hyperopia more than 25 D, +0.5 D in addition to the recommended IOL power; in case of hyperopia more than 29 D, +1.0 D extra). In one patient the Holladay I formula was used to calculate two piggyback lenses. The IOL used in this study was either an Allergan SI 40, Kelios Chauvin or Staar AC injectable lens.

All patients were thoroughly informed of the nature of the procedure and its possible complications.

### SURGICAL PROCEDURE

The eye was prepared for surgery with 1% cyclopentolate hydrochloride, and 10% phenylephrine hydrochloride drops. Topical 0.5% tetracaine and polyvidone iodine 10% were instilled before surgery.

The eyes and eyelid skin were prepared and draped.

All eyes (group one and two) had a 2.5 mm temporal clear cornea incision with a Meyco diamond knife, occasionally enlarged to 2.8 mm. Then the techniques of capsulorhexis, hydrodissection, intercapsular phacoemulsification, and intercapsular implantation of injectable IOL were followed in order. Phacoemulsification was performed with an Allergan Prestige unit. The incision was not sutured. The total operative time for the procedure averaged 10 minutes.

In case of astigmatism (group one) an arcuate keratotomy incision was performed prior to the cataract surgery using a Mastel arcuate corneal compass (MACC). The incision was placed on the appropriate optical axis based on the preoperative astigmatism and calculated according to the Istre modified nomograms (Optical zone 7 mm, depth of incision 600 microns, no pachymetry, variable length and number of incisions). (figure 1)

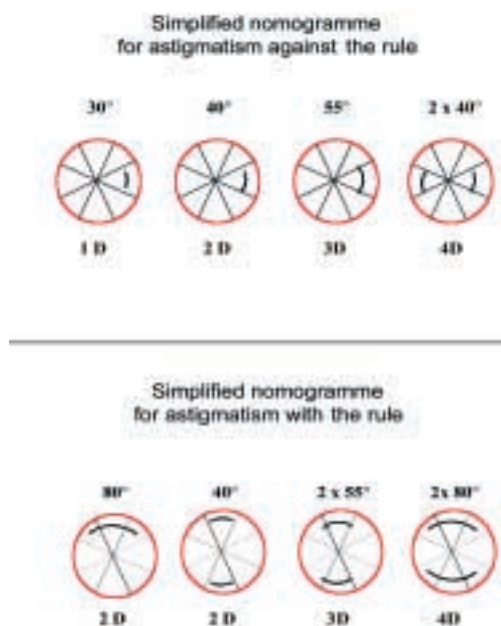


Fig. 1: Modified Istre nomogramme

## POSTOPERATIVE PHASE

Postoperatively dexamethasone 0.1% (1 mg/g), tobramycine 0.3% (3 mg/g), and Natrium-flurbiprofen 0.3% (0.3 mg/ml) was used 4 and 3 times a day respectively, tapering dexamethasone and tobramycine very gradually over 6 weeks. Patients were seen on the first and second operative day, at 2 weeks and 1 month, unless circumstances necessitated more frequent visits. On each visit, Uncorrected and Best Corrected Visual Acuity (UCVA and BCVA), manifest refraction, slitlamp, and fundus examination were performed.

## RESULTS

Mean axial length was 21.65 mm (range, 20.36 to 23.24 mm) in group one, and 21.51 mm (range, 18.23 to 23.36 mm) in group two; and mean keratometry 44.05 D (range, 41.75 to 46.00 D) in group one and 43.36 D (range, 40.75 to 46.38 D) in group two. Mean age at the time of surgery was 62.89 years with a range of 50 to 83 years in group one, and 68.17 years with a range of 53 to 86 years in group two. Mean follow-up (group one) was 2.83 months (range, 1 to 7 months), and (group two) 7.47 months (range, 1 to 24 months).

## FUNCTIONAL RESULTS

Preoperatively, the best corrected visual acuity ranged from 20/25 to 20/20 in group one (see figure 2), and from 20/32 to 20/20 in group two (see figure 3).

Postoperatively, the uncorrected visual acuity (UCVA) was between 20/32 and 20/20 in group one. In group two, it was between 20/40 and 20/20, at the exception of two patients with an UCVA of respectively 20/50 and 20/200, due to induced myopia. In this study all eyes but two (9/9 and 27/29) achieved 20/40 or better postoperative UCVA.

The postoperative best corrected visual acuity was 20/20 in all cases in group one and ranged from 20/32 to 20/20 in group two. None of the eyes in either group lost 2 or more lines of the best corrected visual acuity.

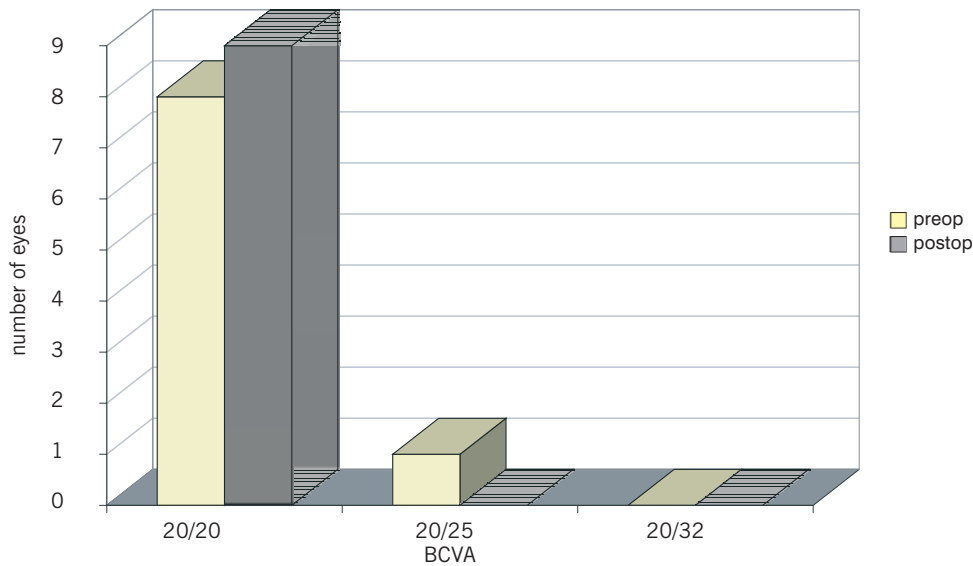


Fig. 2: BCVA group one

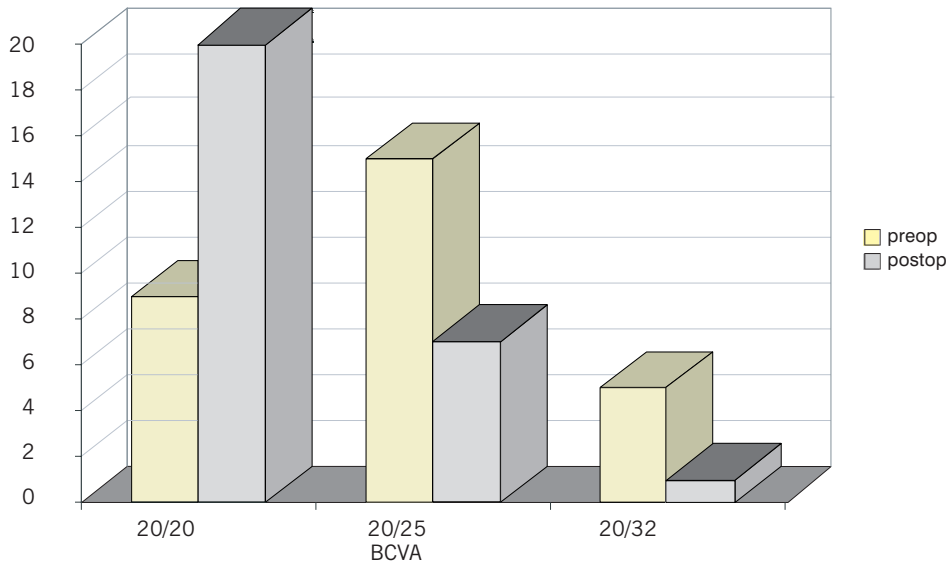


Fig. 3: BCVA group two

### REFRACTIVE RESULTS

The preoperative mean spherical equivalent refraction in group one was 4.79 D (+/- 1.33 SD; range, 2.63 to 5.88 D) and in group two 4.95 D (+/- 1.86 SD; range 2.50 to 10.75 D). Mean preoperative refractive astigmatism in group one was 2.14 D (+/- 0.50 SD; range, 1.25 to 2.75 D). In this group with clinical significant astigmatism, 4 patients out of 9 were against

the rule, 4 with the rule, and one had a left oblique astigmatism.

Of all eyes undergoing clear lens extraction in combination with arcuate keratotomy, 8 out of 9 (89 %) had a postoperative spherical equivalent of refraction within one diopter of emmetropia and all were within two diopters (group one). The mean postoperative spherical equivalent refraction in group one was -0.17 D (+/- 0.67 SD; range, +0.75 to -1.50 D). Figure 4

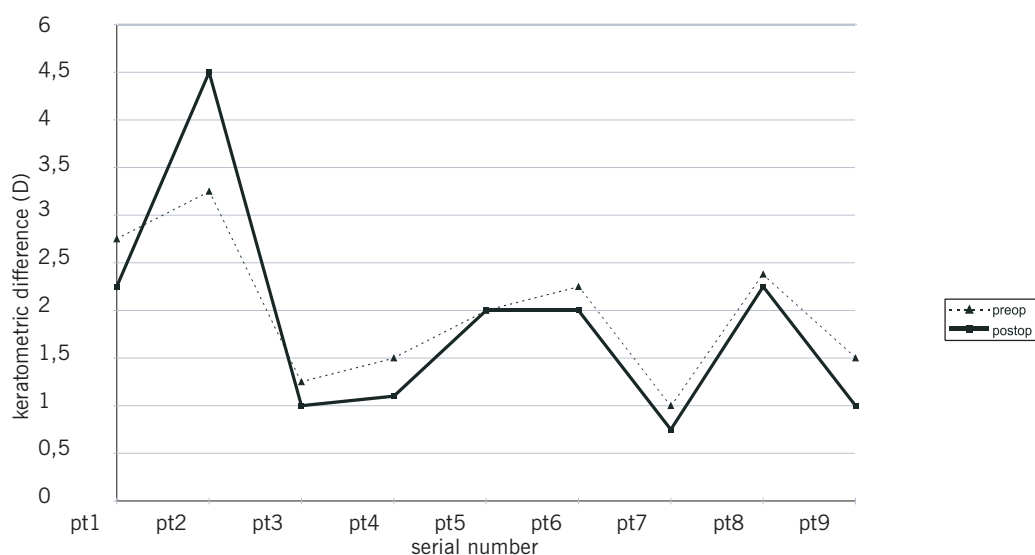


Fig. 4: Objective measurement of astigmatism

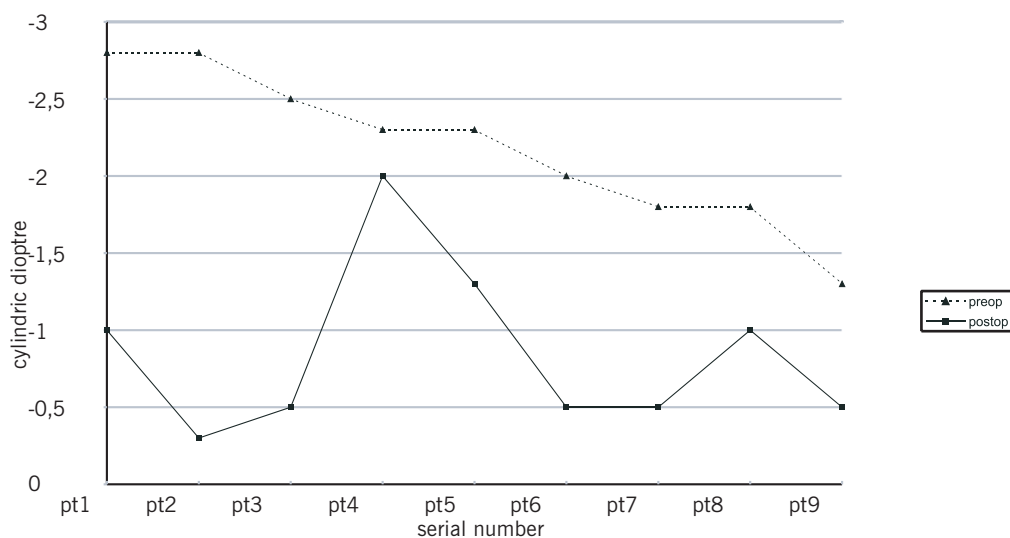


Fig. 5

shows early keratometry measurements after the AK procedure. The terms delta K and Kt, introduced by Cravy<sup>3</sup> in his formula to calculate the surgically induced spherical and astigmatic change, are 0.32 and 1.17 respectively. Delta K is the change in astigmatism with or against-the-rule, according to Cravy's definition. Kt means the total change in astigmatism without respect to that convention. Figure 5 represents the change in subjective refraction, i.e. the residual cylinder chosen by the patient after the procedure. Two patients preferred more

than one cylindrical diopter in their prescription. The mean residual refractive astigmatism was -0.83 D (+/- 0.54 SD; range, -0.25 to -2.00 D).

Figure 6 shows the change in refraction, calculated by using the Holladay, Cravy, Koch (HCK) vector analysis method<sup>9</sup>. This surgically induced refractive change (SIRC) can be expressed in both the spherocylindrical or power form. If SIRC is plus, power has been added to the eye and, if SIRC is negative, the power of the eye has been reduced. This change might

Figure 6.

HOLLADAY-CRAVY-KOCH METHOD												
eye number	preoperative refraction			postoperative refraction			surgically induced refraction change in spherocylindrical form			surgically induced refraction change in power form		
	spheric diopter	cylindric diopter	axis	spheric diopter	cylindric diopter	axis	spheric diopter	cylindric diopter	axis	spheric diopter	cylindric diopter	axis
1	7.25	-2.75	175°	1	-1	165°	6.295	-1.84	180°	6.295	-1.84	90°
2	7.25	-2.75	75°	-0.25	-0.25	30°	7.63	-2.7612	78°	7.63	-2.7612	168°
3	7	-2.5	90°	0	-0.5	115°	7.105	-2.21	85°	7.105	-2.21	175°
4	7	-2.25	90°	-0.5	-2	90°	7.5	-0.25	180°	7.5	-0.25	90°
5	4	-2.25	170°	0	-1.25	5°	4.162	-1.326	156°	4.162	-1.326	66°
6	5	-2	180°	0	-0.5	170°	5.0142	-1.5284	7°	5.0142	-1.5284	97°
7	5.5	-1.75	105°	1	-0.5	90°	3.205	-0.66	20°	3.205	-0.66	110°
8	6.5	-1.75	180°	1	-1	5°	5.522	-0.794	174°	5.522	-0.794	84°
9	3.25	-1.25	90°	0	-0.5	105°	3.298	-0.854	80°	3.298	-0.854	170°

be different from one meridian to another. For example in the first patient the AK has caused a spherical increase in power of that eye by 6.29 D, but this effect is less in the power meridian of 90°. In this case the amount of with-the-rule astigmatism has significantly been reduced. In the group without arcuate keratotomy, 83% of eyes were within one diopter of emmetropia (24/29), and all were within two diopters. In this group the mean postoperative spherical equivalent refraction was -0.10.D (+/- 0.86 SD; range, +1.75 to -2.00 D).

As mentioned previously, we mainly used an adjusted SRK II formula. In only one patient a Holladay I formula was used, giving a calculated IOL power of +42 D on the right and +43 D on the left, instead of + 35 D and +35.5 D respectively, suggested by the adjusted SRK II formula. The postoperative spherical equivalent refraction in this patient was +0.13 D on the right and -0.75 D on the left.

One case of irisprolaps and a small iridodialysis occurred in group one. Two cases of a small posterior capsular tear and one case of corneal burn with postoperative wound leakage occurred in group two. Posterior capsule opacification, necessitating YAG capsulotomy, occurred in 3 eyes, all in group two.

We did not eliminate from this study any patients with peroperative complications. There

were no pre-existing ocular conditions affecting the visual outcome.

## DISCUSSION

Moderate to high hyperopia is a truly disabling condition, especially with advancing age, since increasing presbyopia requires the addition of more positive diopters to the already existing positive correction, resulting in an even greater dependence on optical aids. A pre-existing astigmatism, may even enhance the visual discomfort. Various surgical treatments of hyperopia with or without astigmatism have been proposed.

As mentioned by previous authors, surgery on unusual small eyes, especially nanophthalmos, was thought to be at risk of surgical and postoperative complications, such as uveal effusion and malignant glaucoma. There were no cases of nanophthalmos in our series<sup>2,12,20</sup>.

We used clear lens extraction aiming at emmetropia, in combination with arcuate keratotomy in case of astigmatism to minimize cylindrical correction. However, our study reveals that complete correction of refractive error at the time of the cataract surgery was not always obtained. This might be due to errors of incorrect placement of incisions or IOL power calculations.

In the group where AK was performed for clinical significant astigmatism, early keratometry measurements showed nearly no effect on the corneal curvature. The delta K and Kt values show a rather small change in keratometry. However, when the subjective refraction is taken into account, the results are more spectacular. Only two patients preferred more than one cylindrical diopter in their prescription. The results found by refraction rarely agree with the K-readings following keratorefractive surgery<sup>9</sup>.

Because of a large variation in size of the anterior segment in short eyes, lens power selections in these hyperopic eyes still remain a challenge, despite the different available formulas. In the SRK II approach, a correction factor is added to the lens formula according to the axial length<sup>\*19</sup>. Holladay I formula takes into account a calculated iris plain (distance from the apex of the cornea to the iris) and a surgeon factor (distance from the anterior part of the iris to the optical centre of a particular IOL)<sup>8</sup>.

We mainly used a personalised, slightly adjusted SRK II formula. Only in the patient with a piggyback lens, we used the Holladay I formula, giving more accurate results in extremely short eyes. We did not use the newer lens formulas such as Holladay II and Hoffer Q ACD<sup>7</sup>. The Holladay II formula uses the corneal white to white diameter, the anterior chamber depth and the thickness of the lens to predict even better the postoperative anterior chamber depth. In the Hoffer Q ACD calculation the anterior chamber depth depends on the IOL-type and is corrected for increasing axial length and corneal curvature.

.....

\* SRK II formula:

$$P = (A + C) - 2.5AL - 0.9K$$

*P* = IOL strength

*A* = IOL type specific factor

*AL* = axial length

*K* = mean corneal curvature (Dioptre)

*C* = correction factor according to axial length

if *AL* < 20 mm then *C* = +3

if 20 < *AL* < 21 then *C* = +2

if 21 < *AL* < 22 then *C* = +1

if 22 < *AL* < 24.5 then *C* = 0

if *AL* > 24.5 mm then *C* = -0.5

## CONCLUSION

Our study suggests that clear lens extraction and intraocular lens implantation in combination with arcuate keratotomy in case of astigmatism, is an efficient and predictable procedure to correct hyperopia in a presbyopic age group. The efficiency index (mean postoperative UCVA / mean preoperative BCVA) in group one is 0.82, and 0.84 in group two.

The safety index (postoperative mean BCVA / preoperative mean BCVA) was 1.02 in group one and 1.11 in group two.

Our study is preliminary and the follow-up is limited at this point.

## REFERENCES

- (1) ARGENTO C.J., COSENTINO M.J., BIONDINI A. – Treatment of hyperopic astigmatism. *J. Cataract Refract Surg* 1997, 23, 1480-1490
- (2) BROCKHURST R.J. – Cataract surgery in non-ophthalmic eyes. *Arch Ophthalmol* 1990, 108, 965-967
- (3) CRAVY T.V. – Calculation of the change in corneal astigmatism following cataract extraction. *Ophthalmic Surg* 1979, 10, 38-49
- (4) DAVIDORF J.M., ZALDIVAR R., OSCHEROW S. – Posterior chamber phakic intraocular lens for hyperopia of +4 to +11 diopters. *J Refract Surg* 1998, 14, 306-311
- (5) DITZEN K., HUSCHKA H., PIEGER S. – Laser in situ keratomileusis for hyperopia. *J Cataract Refract Surg* 1998, 24, 42-47
- (6) FECHNER P.U., SINGH D., MULFF K. – Iris-claw lens in phakic eyes to correct hyperopia: Preliminary study. *J Cataract Refract Surg* 1998, 24, 48-56
- (7) HOFFER K.J. – The Hoffer Q formula; a comparison of theoretic and regression formulas. *J Cataract Refract Surg* 1993, 19, 700-712
- (8) HOLLADAY J., PRAGER TH., LEWIS J., RUIZ R. – Improving the predictability of intra-ocular lens power calculations. *Arch Ophthalmol* 1986, 104, 539-541
- (9) HOLLADAY J., CRAVY T., KOCH D. – Calculating the surgically induced refractive change following ocular surgery. *J Cataract Refract Surg* 1992, 18, 429-443
- (10) KERSHNER R.M. – Clear corneal cataract surgery and the correction of myopia, hyperopia, and astigmatism. *Ophthalmology* 1997, 104, 381-389
- (11) LYLE W.A., JIN G.J. – Hyperopic automated lamellar keratoplasty, complications and visual results. *Arch Ophthalmol* 1998, 116, 425-428



- (12) LYLE W.A., JIN G.J. – Clear lens extraction to correct hyperopia. *J Cataract Refract Surg* 1997, 23, 1051-1056
- (13) LYLE W.A., JIN G.J. – Clear lens extraction for the correction of high refractive error. *J Cataract Refract Surg* 1994, 20, 273-276
- (14) NANO H.D., MUZZIN S. – Noncontact holmium: YAG laser thermal keratoplasty for hyperopia. *J Cataract Refract Surg* 1998, 24, 751-757
- (15) O'BRART D.P., STEPHENSON C.G., OLIVER K., MARSHALL J. – Excimer laser photorefractive keratectomy for the correction of hyperopia using an erodible mask and axicon system. *Ophthalmology* 1997, 104, 1959-1970
- (16) OLSEN T., THIM K., CORYDON L. – Accuracy of the newer generation intraocular lens power calculation formulas in long and short eyes. *J Cataract Refract Surg* 1991, 17, 187-193
- (17) OSHER R.H. – Clear lens extraction. *J Cataract Refract Surg*, 1994, 20, 673-674
- (18) PULASKI J.P. – Comparing hyperopia treatments. *J Cataract Refract Surg* 1998, 24, 1419-1420
- (19) SANDERS D., RETZLAFF J., KRAFF M.C. – Comparison of the SRK II formula and other second generation formulas. *J Cataract Refract Surg* 1988, 14, 136-141
- (20) SIGANOS D.S., PALIKARIS I.G. – Clear Lens-ectomy and intraocular lens implantation for hyperopia from +7 to +14 diopters. *J Refract Surgery* 1998, 14, 105-113
- (21) TASSIGNON M.J., TRAU R., MATHYS B. – Le traitement de l'hypermétropie à l'aide du Laser Holmium, Laser thermokératoplastie (LTK). *Bull Soc belge Ophtalmol* 1997, 266, 75-83
- .....
- Requests for reprints:*  
 Dr Stefan De Smedt  
 Dienst Oogziekten KU Leuven  
 UZ Sint Rafael, Kapucijnenvoer 33, B-3000 Leuven.

