

---

## DIDACTIC IMAGE

# OPHTHALMOSCOPIC PRESENTATION OF PRESUMED RETINAL GLIAL CELL ACTIVATION (ARAM) IN A GLAUCOMA PATIENT

*DETRY-MOREL M.\**

---

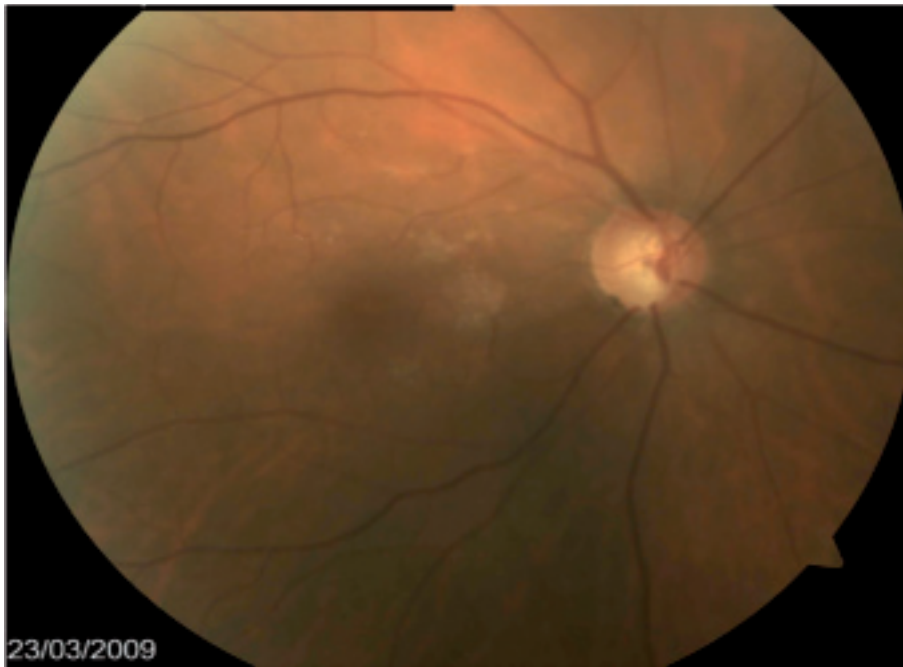## CASE REPORT

A 68-year-old woman was diagnosed ten years previously to have Normal Tension Glaucoma with quite asymmetrical glaucoma damage at the expense of her right eye. In addition to a positive familial history for glaucoma, the patient suffered from migraine, cold hands and feet, nocturnal systemic diastolic hypotension and exhibited a splinter haemorrhage opposite to the inferior temporal neuroretinal rim at initial presentation.

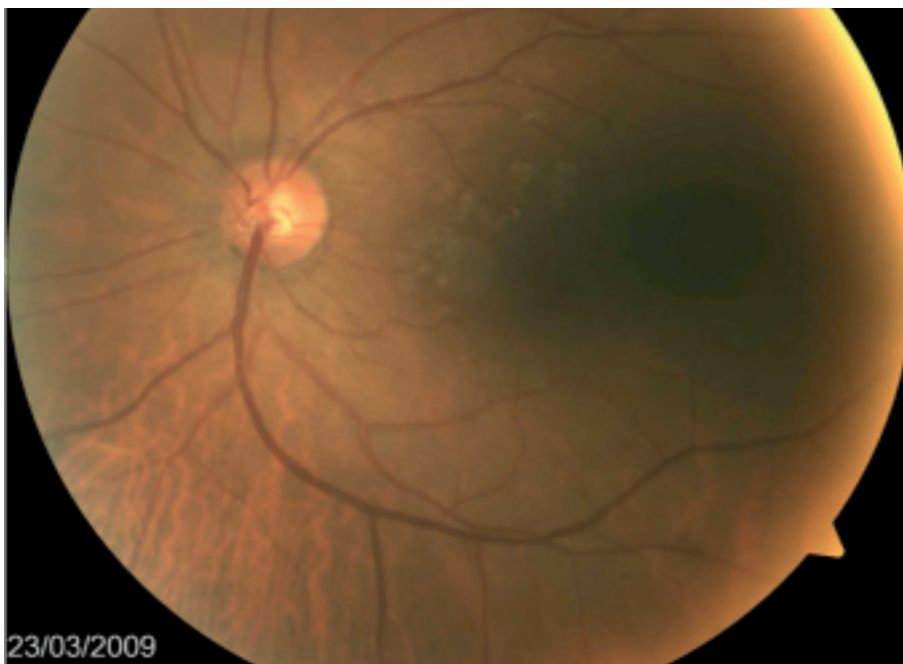Her best corrected visual acuity was 1.0, snellen 1 in both eyes. Standard automated perimetry (Humphrey 30-2 Sita Standard) showed an arciform deep para-central scotoma splitting the fixation in the superior nasal quadrant associated with an inferior nasal step in RE. Visual field was normal in LE. Anterior biomicroscopy was normal in both eyes. IOP with Goldmann applanation tonometry was 15 and 16 mm Hg respectively in RE and LE with topical medications. Central Corneal Thickness was in the normal range in both eyes ( $\pm 550 \mu\text{m}$ ). Iridocorneal angle was open and unremarkable in gonioscopy. Ophthalmoscopy revealed normal size optic discs with a vertical CD ratio of 0.7, a typical notching of the inferior temporal rim and a corresponding nerve fibre bundle defect in the right eye. The left optic disc was normal. Patchy, discrete glittering and transparent alterations of the retina were visible in both posterior poles. Their aspect was compatible with ARAM changes. These spared the fovea and preferentially lied in the vicinity of the major retinal vessels (Figure 1a and b). On red-free photographs, these changes showed slightly increased reflection and light scattered (Figure 2 a and b).

.....

\* *St Luc University Hospital  
Université Catholique de Louvain  
Avenue Hippocrate, 10  
1200-Brussels  
Belgium*



*Fig. 1a*



*Fig. 1b*

Color fundus photographs of the RE (1a) en LE (1b) showing presumed ARAM in the pole postero.

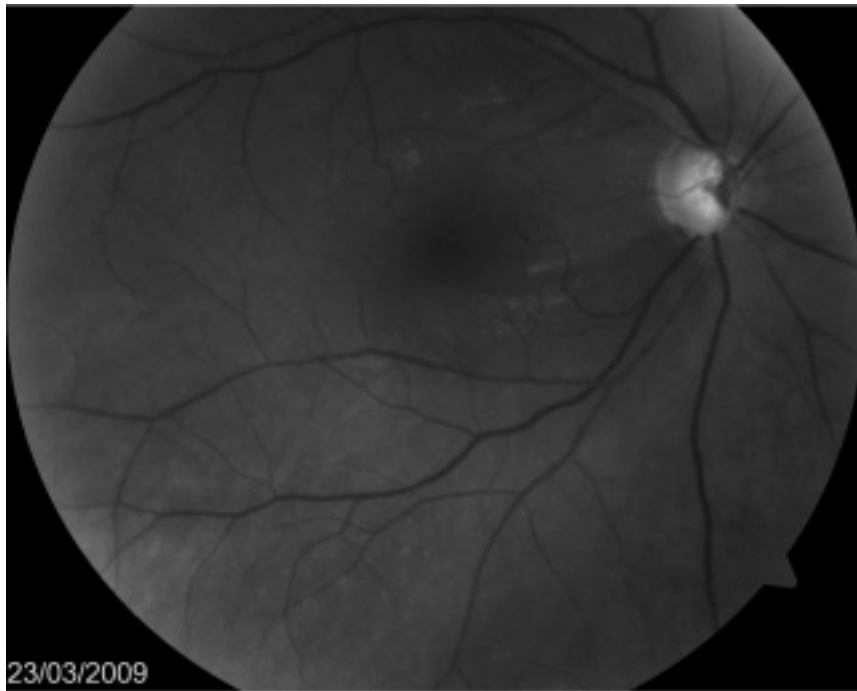


Fig. 2a

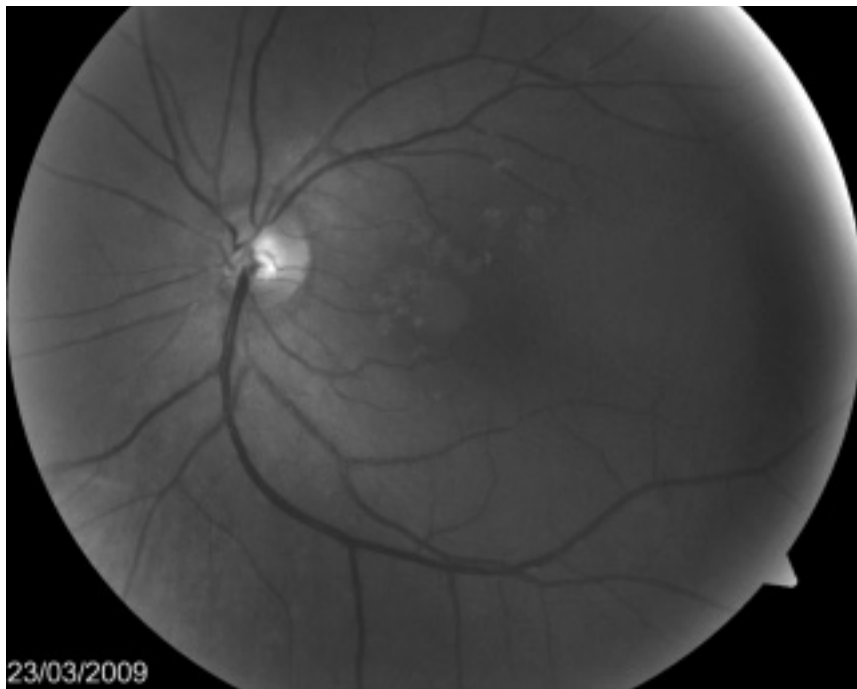

Fig. 2b

Red-free photographs of the RE (fig 1a) and the LE (fig 2b). Note the inferior temporal nerve fibre bundle defect in the right eye.

## DISCUSSION

Increased intraocular pressure and disturbed ocular blood flow have been together implicated in the pathogenesis of glaucomatous optic neuropathy (1). Clinical morphologic diagnosis of glaucomatous damage is traditionally based on the presence of an excavation of the optic nerve head, defects of the retinal nerve fibre layers, optic disc haemorrhages and peripapillary atrophy.

The presence of patchy, glittering changes of the retina in the posterior pole of glaucoma patients have been related to the activation of retinal glial cells as a response to the injury of neuronal tissue and had been termed presumed ARAM (Activated Retinal Astrocytes and Müller cells). This aspect has been found to be related to vascular dysregulation in Primary Open-Angle Glaucoma patients (2). Presumed ARAM changes are not associated with visual disturbances and typically do not correspond to the pattern of the retinal nerve fibre bundle defects (2).

Differential diagnosis of ARAM lesions includes epiretinal membrane, retinal exsudates, drusen and other retinal pigmented epithelium alterations.

## REFERENCES

- (1) FLAMMER J., ORGUL S., COSTA V.P., ORZALESI N., KRIEGLSTEIN G.K., SERRA L.M., RENARD J.P., STEFANSSON E. – The impact of ocular blood flow in glaucoma. *Prog Retin Eye Res.* 2002; 21:359-93.
- (2) GRIESHABER M.C., ORGUL S., SCHOETZAU A., FLAMMER J. – Relationship between retinal glial cell activation in glaucoma and vascular dysregulation. *J Glaucoma* 2007; 16:215-9.