

---

# HOW TO OPTIMIZE TRABECULECTOMY

ZEYEN T.\*

---

Trabeculectomy, a guarded sclerostomy introduced by Cairns in 1968 (1), is the most widely used filtration surgery. (2) In recent years, important changes have been introduced in order to make trabeculectomy safer and also more efficient. The Moorfields safe surgery system was developed by Peng Khaw in 2004 (3), and was mainly geared towards reducing the risk of postoperative complications. The most important postoperative complications are (4):

1. Hyphema
2. Wound leaks
3. Flat anterior chamber requiring surgery
4. Hypotony and its complications, maculopathy and choroidal detachment
5. Late onset blebitis and endophthalmitis

Our routine trabeculectomy technique is summarized in the appendix. (5) In this chapter, we will focus on how to reduce the risk of postoperative complications and how to achieve the target intraocular pressure (IOP) by appropriate postoperative bleb management.

## Prevention of intraoperative hemorrhages and hyphema

Intraoperative hemorrhages can occur at the conjunctiva or sclera level. Wet-field cautery is probably the safest tool allowing for minimal scleral burns. Intraocular bleeding is rare and is usually secondary to the drop in IOP. Intraocular bleeding can be avoided by keeping the anterior chamber well formed throughout surgery and by making the IOP drop as progressive as possible. However, in patients with fragile vessels (e.g., Amsler sign in Fuchs heterochromia) or on anticoagulation therapy, intraocular bleeding may occur. Both blood and cautery-induced thermal injury may stimulate fibro-

blast proliferation and may lower the chances of bleb survival. Therefore, we prefer to discontinue anti-platelet aggregants and anticoagulants prior to surgery (table 1) since their effect on the platelets is often irreversible and this effect is reversed only when the platelets are renewed. (6,7) One should take into account that some herbal medicines (e.g., garlic, ginseng, and ginkgo biloba) also have platelet-inhibiting properties and should therefore be stopped two weeks prior to surgery. Depending on their half-life, oral anticoagulants (vitamin-K antagonists like coumarin derivatives) should be stopped 7 to 10 days before surgery. They should be replaced by injections of low molecular weight heparin derivatives until the day before surgery if the patient is at high risk of developing thrombo-emboli. Oral anticoagulants and anti-aggregants should be restarted 24 hours after surgery while continuing the injections of heparin derivatives for four more days. Anti-aggregants should not be discontinued during the first year after the implantation of a drug-eluting stent. In this case, one should perform the operation under topical and subconjunctival/subtenon anesthesia and warn the patient that the risk of bleeding and postoperative scarring is higher. Using one or two drops of Apraclonidine (Iopidine, Alcon®) before starting the operation will blanch the conjunctiva without the pupillary and cardiovascular side-effects of phenylephrine.

## Prevention of wound leaks

Positive Seidel tests are more frequent with a fornix based than with a limbal based conjunctival flap. A fornix based flap, however, is preferred by many surgeons because it is technically easier, gives a good exposure of the sclerostomy, and promotes a diffuse filtration, avoiding the "ring of steel" often seen with a limbal based flap. Leaks can be avoided by meticulous wound closure using a "purse string" tech-

.....

\* University Hospital, Leuven, Belgium

Table 1: Guidelines for stopping anti-platelet aggregants before filtering surgery.

Anti-platelet aggregants	Stop pre-operatively
Acetylsalicylic acid (ASA)	2 weeks
Thiënopyridine (Ticlopidine & Clopidogrel)	2 weeks
Dipyridamol	1 week
Non-steroidal anti-inflammatory (NSAI)	1 week

nique with two lateral nylon 10/0 sutures, burying the knot and securing the conjunctiva firmly on top of the cornea (<http://www.ucl.ac.uk/ioo/research/khawlibrary.htm>). It is usually a good prognostic sign for a negative Seidel test to observe a roll of conjunctiva overlying the cornea. Additional nylon 10/0 mattress sutures, firmly fixing Tenon's capsule to the cornea, can be added without making corneal grooves to further seal the wound. The risk of wound leaks is further diminished by not prolonging the lateral scleral incisions into the cornea (stopping at 0.5-1 mm from the limbus).

Wound leaks are more frequent if anti-metabolites were used. We suggest using them only if the risk for postoperative fibrosis is high (Table 2) or if very low target pressures are desirable (e.g., < 12 mmHg). We use mitomycin-C (MMC) 0.2 mg/ml for max 3' or 5-FU 50 mg/ml for 5' (in eyes with a thin sclera; buphthalmic or myopic eyes with an axial length 26 mm). We recommend using polyvinyl alcohol (PVA) instead of methylcellulose sponges because the latter tend to fragment with the risk of leaving small pieces in the wound. We tend to use small pieces of PVA (4-5) and treat an area as large as possible, including putting one piece underneath the scleral flap. During the treatment, we pull the conjunctiva forward to avoid contact of anti-metabolites with the edge of the conjunctiva. After removing the sponges, we rinse the wound with a minimum of 20 cc of balanced salt solution (BSS), lifting the conjunctiva to allow a broad flow, including underneath the scleral flap.

#### Prevention of a flat anterior chamber requiring surgery

In order to avoid a flat anterior chamber post-operatively, it is necessary to keep the cham-

Table 2: Indications for the use of anti-metabolites (5-FU or MMC)

- |   |
|---|
| <ul style="list-style-type: none"> <li>• Increased risk for postoperative fibrosis:               <ul style="list-style-type: none"> <li>- Patients &lt; 40 years</li> <li>- Afro-Caribbean</li> <li>- Previous surgery involving the conjunctiva</li> <li>- Chronic uveitis</li> </ul> </li> <li>• Low target pressure (&lt; 12 mmHg)</li> </ul> |
|---|

ber well formed throughout the surgery. This can be done by using an anterior chamber maintainer or by filling the anterior chamber with a viscoelastic immediately after the paracentesis. It is also important to avoid overfiltration. This is achieved by delineating a scleral flap that is sufficiently large (4 x 5 mm), by dissecting the flap to half thickness, and by tailoring the tightness of the scleral flap sutures. This can best be accomplished with an anterior chamber maintainer (see appendix) or while injecting BSS through the paracentesis. We recommend using a few drops of atropine 1% (Minims 1 ml, Chauvin, Belgium) at the end of the operation to rotate the ciliary body posteriorly, promoting the formation of the anterior chamber.

#### Prevention of hypotony

The prevention of hypotony and its complications, maculopathy and choroidal detachment, is mainly related to reducing the use of anti-metabolites (Table 2) and by handling them properly if they are indicated (see above). Additionally, it is important to make the scleral flap sufficiently large (4 x 5 mm) to cover the sclerostomy since the main function of the scleral flap is to provide resistance to aqueous outflow and prevent hypotony. Finally, it is recommended not to cut the flap sutures too early with the laser. Often, loosening the adjustable sutures or massage will be sufficient if the IOP is too high for the first postoperative days. Laser suturelysis can be performed safely one week postoperatively.

#### Late onset blebitis and endophthalmitis

The risk for late onset blebitis and endophthalmitis can be reduced by using antimetabolites judiciously and carefully (see above) and by looking at positive Seidel tests if the IOP is

low (< 6 mmHg), even months or years after surgery. A low IOP with a thin cystic bleb is particularly suspicious. Late onset wound leaks need to be repaired. Prolonged use of topical antibiotics does not prevent late onset blebitis or endophthalmitis.

### Postoperative bleb management

The success of a trabeculectomy is not guaranteed with an uneventful operation. To obtain the target pressure, appropriate postoperative bleb management is mandatory. Since subclinical inflammation can persist for several months after a trabeculectomy, it is recommended to use eye drops containing steroids and antibiotics four times daily for at least two months without tapering. If a steroid response is suspected (elevated IOP in the presence of a functioning bleb), weaker steroids (e.g., rimexolone or fluorometholone) can be used. If staging is preferred (trabeculectomy first and cataract surgery thereafter), it is strongly recommended to postpone the cataract operation until six months after trabeculectomy.

If the IOP is elevated during the first postoperative days, loosening the adjustable flap sutures or massage will be sufficient. The adjustable sutures can be loosened under topical anesthesia using a Khaw Transconjunctival Adjustable Suture Control Forceps (Duckworth and Kent, England). It is recommended not to cut the releasable (fixed) flap sutures the first days after surgery since this might induce overfiltration and hypotony. In case the sclerostomy is obstructed by blood, one may consider an intracameral injection of tissue plasminogen activator (t-PA 8 µg in 0.1 ml of BSS). If the IOP is still above the target pressure after one week, laser suture lysis should be performed, first one suture and within one week the second one. Laser suture lysis can be postponed until several weeks if antimetabolites (especially MMC) were used during surgery. It is recommended to measure the IOP immediately after the suture lysis and, if necessary, to perform a massage to improve filtration. If the IOP is still too high after four weeks, one can remove the adjustable sutures. This can easily be done under topical anesthesia by pulling the adjustable suture out of the corneal groove using a tying forceps.

If excessive fibrosis occurs, bleb failure can be prevented by injecting 5-FU subconjunctivally near the filtering bleb. Up to four weekly injections of 0.1 ml of 5-FU (50 mg/ml) can be given. If bleb failure is unavoidable, we suggest to perform a revision by needling rather than reopening the wound surgically. Needling and lifting the scleral flap can be done under topical anesthesia, and is much less traumatic (i.e., induces less fibrosis) than a surgical re-intervention. Of course, a revision by needling can only be performed if the flap is clearly visible through the conjunctiva. It is usually a good prognostic sign to observe effusion of aqueous humor while lifting the scleral flap or entering the anterior chamber. The success rate of a revision by needling is probably higher if performed within one year of the trabeculectomy. Strong evidence was found for an association between the immediate attainment of a low IOP (<11 mmHg) and longer survival times.<sup>8</sup> Finally, we prefer to needle an encapsulated bleb if the IOP is elevated. Although medical therapy is an alternative, we believe that one or two needlings of an encapsulated bleb will promote the formation of a diffuse bleb with lower IOPs. Needling and needling-revision are always accompanied by a subconjunctival injection of 5-FU (0.1 ml of a solution of 50 mg/ml).

### REFERENCES

- (1) CAIRNS JE. – Trabeculectomy. Preliminary report of a new method. *Am J Ophthalmol* 1968;66(4):673-9.
- (2) EDMUNDS B, THOMPSON JR, SALMON JF et al. – The National Survey of Trabeculectomy. II. Variations in operative technique and outcome. *Eye* 2001;15(Pt 4):441-8.
- (3) WELLS AP, BUNCE C, KHAW PT. – Flap and suture manipulation after trabeculectomy with adjustable sutures: titration of flow and intraocular pressure in guarded filtration surgery. *J Glaucoma* 2004;13(5):400-6.
- (4) EDMUNDS B, THOMPSON JR, SALMON JF et al. – The National Survey of Trabeculectomy. III. Early and late complications. *Eye* 2002;16(3):297-303.
- (5) STALMANS I., GILLIS A., LAFAUT A.S. et al. – Safe trabeculectomy technique: long term outcome. *Br J Ophthalmol.* 2006 Jan;90(1):44-7.
- (6) COBB C.J., CHAKRABARTI S., CHADHA V. et al. – Sanders R. The effect of aspirin and warfarin therapy in trabeculectomy. *Eye* 2007; 21(5):598-603.

- (7) LAW S.K., SONG B.J., YU F., KURBANYAN K. et al. – Hemorrhagic complications from glaucoma surgery in patients on anticoagulation therapy or antiplatelet therapy. *Am J Ophthalmol* 2008; 145(4):736-746.
- (8) BROADWAY D.C., BLOOM P.A., BUNCE C. et al. – Needle revision of failing and failed trabeculectomy blebs with adjunctive 5-fluorouracil: survival analysis. *Ophthalmology*. 2004; 111(4):665-73.

**Appendix.** Summary of trabeculectomy technique

Before starting the operation, one or two drops of povidone iodine (Alcon®, Fort Worth, Texas, USA) are applied to blanch the conjunctiva, avoiding the pupillary and cardiovascular side effects of adrenaline and phenylephrine.

A corneal traction suture is placed with silk 8/0 and a fornix-based conjunctival flap dissected in one quadrant. Antimetabolites are used when indicated (mitomycin 0.2 mg/ml for max 3' or 5-fluoro-uracil 50 mg/ml for 5'). After gentle diathermy, a scleral flap of 5 x 4 mm with side incisions at 0.5 mm from the cornea is delineated with a 30° blade (Alcon®). The flap is then dissected at half thickness with a crescent knife (Alcon®), without prolonging the lateral incisions into the cornea. The central part of the flap is dissected 1 mm into clear cornea.

Scleral flap sutures (nylon 10/0) are pre-installed: two adjustables laterally (Figure 1) and two releasables (i.e., fixed) in between. A corneal paracentesis is made infero-temporally using a clear-cut side port knife of 1.2 mm (Alcon®). The conic 1.3 mm Blumenthal anterior chamber maintainer (BD-Visitec®, Franklin Lakes, New Jersey, USA) is positioned (Figure 2) with the bottle of BSS (Alcon®) at 30 cm above the patients' eye. A trabeculectomy is

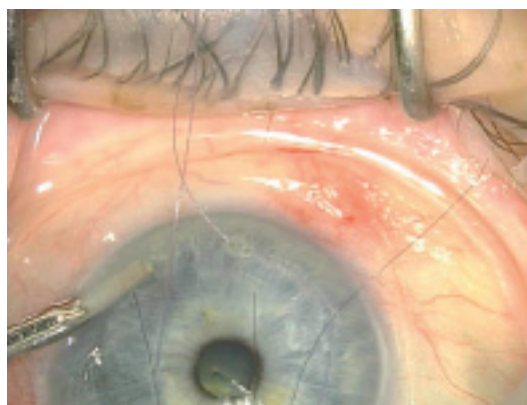

Fig. 2: Anterior chamber maintainer.

performed using the Khaw titanium punch of 0.5 mm (Duckworth & Kent®, Hertfordshire, UK), followed by a peripheral iridectomy.

The flap sutures are closed: the two adjustables at the corners of the flap with four throws (Figure 1) and the two releasables buried in between. The number and tightness of the releasable flap sutures depend on the flow through the AC maintainer; when judged necessary, sutures are loosened, removed, tightened, or added. At a bottle height of 30 cm above the eye, a flow rate of 1 drop every 3-4" is expected to result in an IOP of approximately 10-15 mmHg. The flow is double-checked with Weck sponges at the posterior lip of the scleral flap to ensure that only minimal lubrication is observed. Finally, the conjunctiva is closed with two nylon 10/0 sutures, using a 'purse string' technique burying the knots. Additional nylon 10/0 sutures are added in between (when indicated) to further seal the wound. A topical combination preparation containing steroids and antibiotics is prescribed for two months post-operatively.

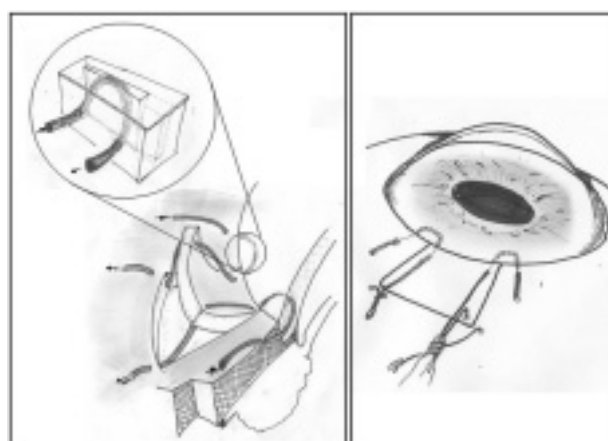


Fig. 1: Adjustable sutures.