

STRIPPING OF DESCMET'S MEMBRANE WHILE REFILLING THE ANTERIOR CHAMBER

KATRIEN CLAES, INGEBORG STALMANS
AND THIERRY ZEYEN

CASE REPORT

A 67-year-old man underwent a trabeculectomy for pseudo-exfoliative glaucoma. The post-operative course was complicated by overfiltration with hypotony and a flat anterior chamber (AC) with lens touch. While the AC chamber was refilled at the slitlamp with a viscoelastic (Healon[®]), stripping of Descemet's membrane was observed. The patient was referred to our department.

Slitlamp examination showed a diffuse filtering bleb (Seidel negative), a clear cornea, stripping of Descemet's membrane (except superiorly) with Healon[®] trapped between Descemet and corneal stroma (figures 1 and 2), a flat AC with Descemet-lens and Descemet-iris touch, pharmacological mydriasis, and a choroidal detachment on funduscopy. The intraocular pressure (IOP) was 6 mmHg.

In order to reposition Descemet's membrane, a small hole was first made in the membrane opposite the original corneal paracentesis infero-temporally using a 15° knife. Healon[®] was then injected into the AC via a second paracentesis supero-nasally in an attempt to flat-

ten Descemet's membrane by squeezing out the viscoelastic trapped in front of it. The trapped Healon[®] could escape via the infero-temporal corneal paracentesis (out of the eye) and via the hole made in Descemet's membrane (into the AC). Balanced Salt Solution (BSS) was then used to irrigate and aspirate the residual Healon[®]. At the end, non-expandable 20% Sulfur hexafluoride (SF-6) gas was injected into the AC in order to compress Descemet's membrane against the stroma. Up to this moment the cornea remained clear, but once the Healon[®] was removed from the pocket between Descemet and stroma, the cornea gradually became oedematous.

This surgical repair only partially repositioned Descemet's membrane and the AC collapsed again after a few days due to the overfiltration. A bleb-revision was then carried out. First, additional scleral flap-sutures were positioned and tightened according to the irrigation flow. Then, a drainage of the choroidal detachment was carried out. Finally, an air bubble was injected in the AC to compress Descemet's membrane against the stroma.

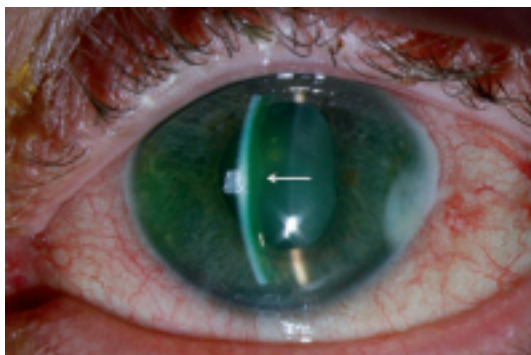

Fig. 1. Stripping of Descemet's membrane seen at the slitlamp (arrow).

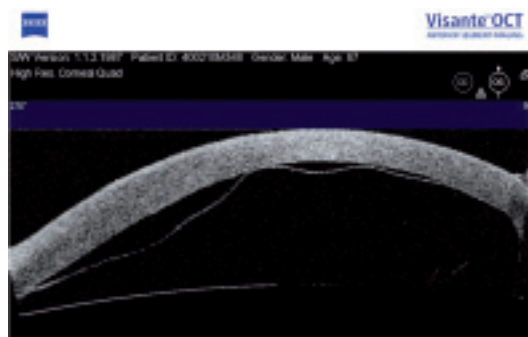


Fig. 2. Stripping of Descemet's membrane seen with the anterior chamber Optical Coherence Tomograph (VisanteTM OCT)

The air bubble resolved quickly and Descemet's membrane partially reattached once more. An second injection of 1.5 ml of 20% SF-6 gas (1cc SF6 + 4cc air) maintained in the AC for 10 days and finally almost completely repositioned Descemet's membrane.

At present, slitlamp examination of the patient reveals a filtering bleb, a clear cornea, a reattached Descemet's membrane, a deep AC and lens opacities (figure 3). The IOP is 14 mmHg. Cataract extraction is scheduled in a few months.

DISCUSSION

An early postoperative flat AC with hypotony following trabeculectomy should be treated according to its severity and etiology.

In stage 1 , where there is no touch between cornea and iris, cycloplegics will usually be sufficient, especially if there is no wound leak.

In stage 2, characterized by contact between cornea and iris, a conservative treatment with cycloplegics is recommended if there is no wound leak. In case of a small wound leak with positive Seidel test, a low dose of Acetazolamide (125 mg twice daily for 5-10 days, reducing temporarily the aqueous flow) will usually resolve the problem. If not, a large diameter (20 mm) bandage lens may be fitted for 1 or 2 weeks. In case of an important wound leak or wound dehiscence, especially with a non-existing bleb, additional conjunctival sutures should be added.

In a stage 3 flat AC, where there is contact between the lens and the cornea, the AC should be refilled within 24 hours with a viscoelastic, if necessary combined with the measures described above.

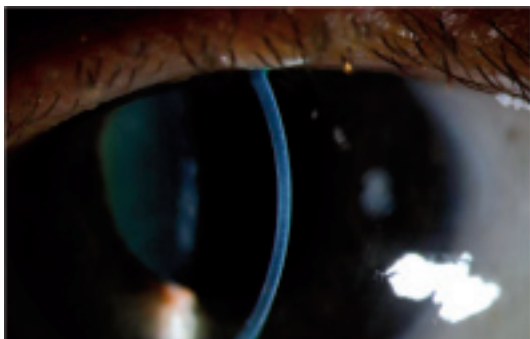


Fig. 3. Slitlamp view of repositioned Descemet's membrane

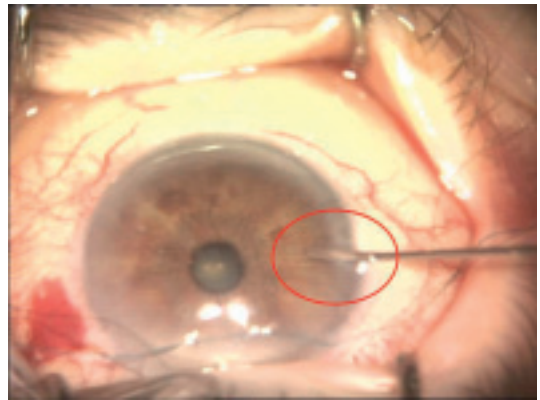


Fig. 4. Tip of Rycroft canula visible when (re-)filling the anterior chamber

To the best of our knowledge, this is the first report of stripping of Descemet's membrane while refilling a flat AC early after trabeculectomy. Refilling the AC with a viscoelastic in a stage 3 flat AC is not without risk. One should never attempt to inject the viscoelastic if the tip of the Rycroft canula is not clearly visible in the AC.

An interesting feature of this case is the fact that the cornea remained clear as long as the viscoelastic material was present in the space between cornea and Descemet. Most probably, Healon[®] acted as a barrier to prevent the aqueous humor to enter the stroma. Corneal oedema only occurred once the Healon[®] was replaced by BSS and aqueous humor. An important factor for surgical repair was to create a small hole in Descemet's membrane in order to be able to remove the trapped viscoelastic (partially via the corneal paracentesis and partially via the hole in Descemet's membrane). Spontaneous resorption of the viscoelastic was not an option in this case because the detachment was too large and spontaneous resorption might take several months, risking irreversible corneal oedema.

In this case, a combination of treating the overfiltration by adding scleral flap-sutures, draining choroidal effusions, removing the trapped viscoelastic, and finally injecting longstanding (10 days), non-expandible gas (SF-6 20%) could cure the patient and reposition Descemet's membrane.

Although the long-term prognosis of this complication is usually good, stripping of Descem-

et's membrane can be avoided when (re-)filling the AC by always clearly seeing the tip of the canula inside the AC (figure 4).

REFERENCES

- (1) KOZART D.M., EAGLE RC Jr. – Stripping of Descemet's membrane after glaucoma surgery. *Ophthalmic Surg.* 1981 Jun; 12(6): 420-3.
- (2) FEYS J., MOHAND-SAID M., NODARIAN M., HOLLARD P. – Spontaneous clearing of the cor-

- nea with detachment of Descemets membrane. *J Fr Ophtalmol.* 2002 May; 25(5): 502-4
- (3) ROY S., MERMOUD A. – Complications of deep nonpenetrating sclerectomy. *J Fr Ophtalmol.* 2006; 29:1180-97.

KEY WORDS

Descemet stripping, flat anterior chamber, filtering surgery, glaucoma