



# Sixth nerve palsy : children

Dr. S. Prinsen

Oogkliniek Deurne

BSA 15/03/2007

# Sixth nerve palsy: children

- Julie (7 years) (Grandfather = physician )
- Saturday night: acute esotropia and diplopia  
compensatory head turn
- Workup:
  - Normal pediatric examination
  - 2 weeks before: influenza
  - Normal ophthalmological examination
  - MRI: normal

# Sixth nerve palsy: children

- Julie

- Benign viral n. VI paresis
- Spontaneous full recovery in 4 weeks

# Sixth nerve palsy: children

- Marianne ( 11 years )
  - Acute diplopia ++ with esotropia, closing 1 eye
  - 10 days before hospitalisation because of fever, headache and nuchal rigidity
  - “meningitis”
  - LP: normal

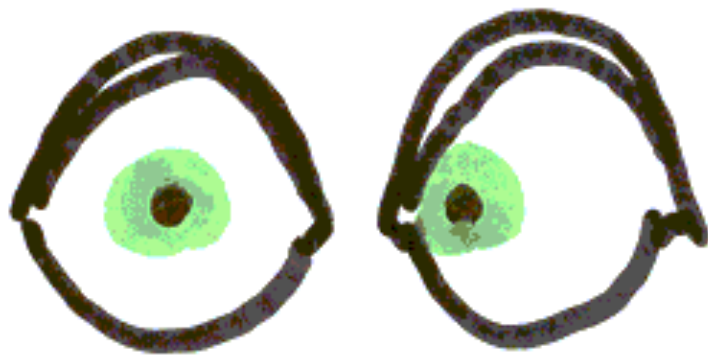# Sixth nerve palsy: children

- Workup:
  - Normal ophthalmological examination
  - CT scan: brainstem tumor
- Marianne died 2 years later


# Sixth nerve palsy : children

- Symptoms
- Differential diagnosis
- Etiology of isolated sixth nerve palsy
- Workup
- Treatment

# Sixth nerve palsy : children



"Looks to your  
RIGHT"



"Looks to your  
LEFT"

# Sixth nerve palsy : children

- *Symptoms : esotropia in primary position*
  - *unilateral* : esotropia increases on gaze direction toward the involved muscle and compensatory horizontal face position toward the palsied eye
  - *bilateral* : esotropia
    - BUT eyes may be straight e.g. Moebius and bilateral Duane syndrome



# Sixth nerve palsy : children

- *Symptoms :congenital and recently acquired palsy*
  - “secondary deviation exceeds primary deviation”
  - Manifest greater esotropia when fixating with the palsied eye (sec. dev.) , lesser deviation when fixating with the sound eye (prim. dev.)
  - This gradually disappears due to contracture of the ipsilateral medial rectus and hypertrophy of the contralateral medial rectus

# Sixth nerve palsy : children

- *Differential diagnosis :*

*Not every lateral rectus malfunction is  
a “sixth nerve palsy”*

# Sixth nerve palsy : children

- *Differential diagnosis : other causes of abduction deficits*
  - myasthenia gravis
  - orbital trauma : medial rectus entrapment
  - congenital deficits : Duane and Moebius syndromes
  - “convergence spasm” (spasm of the near reflex)

# Sixth nerve palsy : children

- *Differential diagnosis : Duane syndrome*
  - Type I , II , and III
  - Left eye , female
  - most characteristic clinical presentation is an absence of abduction of an eye with some degree of restricted adduction and retraction when an attempt is made to adduct

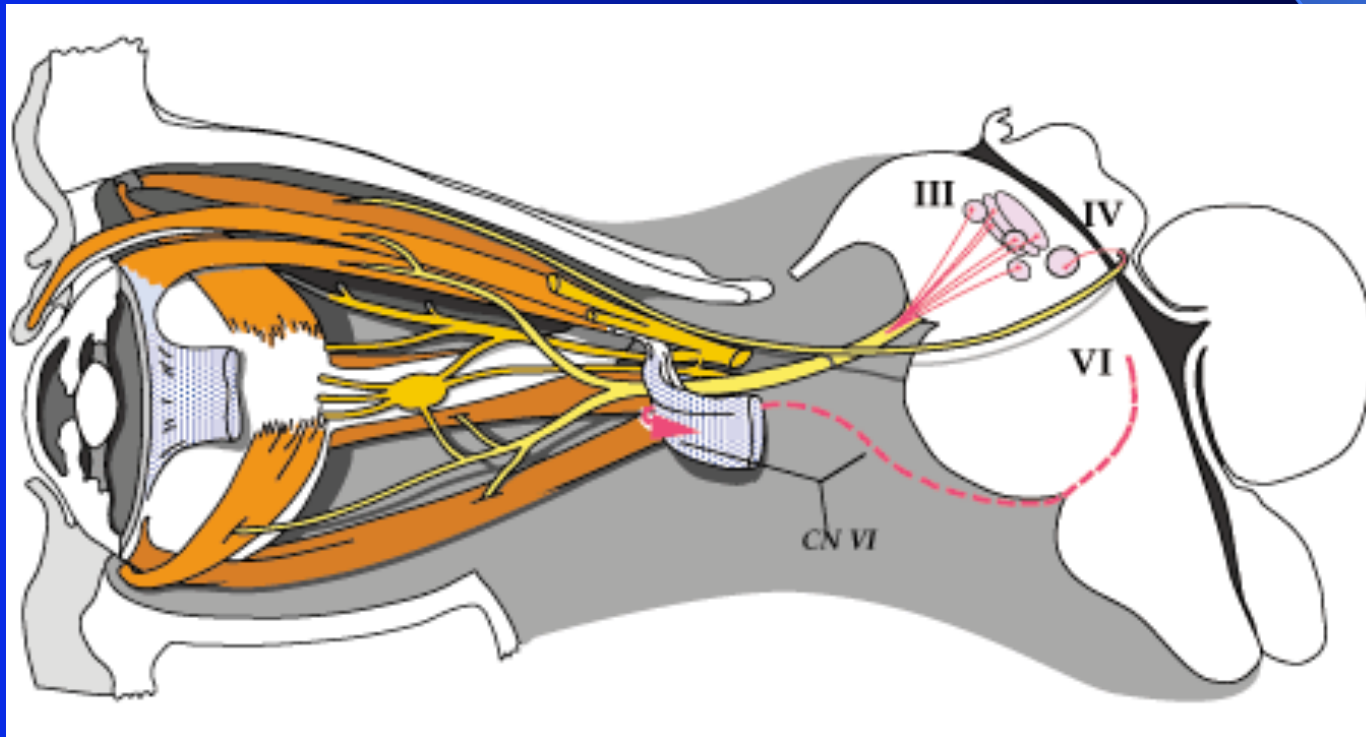
# Sixth nerve palsy: children

- *Differential diagnosis : Duane syndrome*

	<b>N VI</b>	<b>Duane</b>
<b><i>Angle Eso</i></b>	Large	Small
<b><i>Abduction</i></b>	~ angle	Severe restriction
<b><i>Adduction</i></b>	Overaction	Normal or restricted
<b><i>Palpebral fissure</i></b>	Normal	Widening on attempted abduction
<b><i>Retraction</i></b>	No	Retraction in adduction
<b><i>Vertical Deviations</i></b>	No	Often A or V pattern

# Sixth nerve palsy : children

- *Differential diagnosis : Duane syndrome*



# Sixth nerve palsy : children

- *Differential diagnosis:  
Moebius syndrome*



- the abnormal ocular motility is only a portion of this relatively extensive malady (congenital paralysis of n. VI and VII, palsy of the tongue, deafness, hand deformity, autism)
- Aplasia of the nuclei of the abducens, facial, and glossopharyngeal nerves ,defective FLM
- esotropia and inability to abduct the eyes are the usual reasons to be referred to an ophthalmologist

# Sixth nerve palsy : children

- *Differential diagnosis : Moebius syndrome*



- Horizontal versions are congenitally absent
- Often esotropia ( A and V patterns are common with compensatory head posture)
- Surgery : abnormal traction tests ; thickened and fibrotic horizontal muscles



# Sixth nerve palsy : children

- *Incidence of pediatric third, fourth, and sixth CN palsies (Holmes and coworkers)*
  - IV 36 %
  - VI 33 %
  - III 22 %
  - multiple nerve involvement 9 %

# Sixth nerve palsy : children

- *Etiology of isolated sixth nerve palsy*
  - Congenital
  - Acquired

# Sixth nerve palsy : children

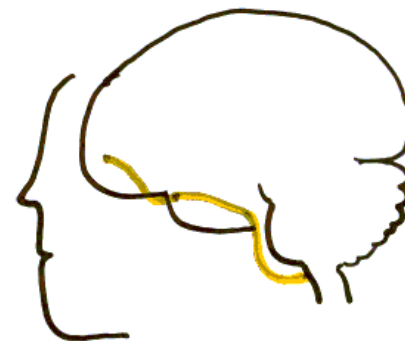
- *Etiology of isolated sixth nerve palsy*
  - Congenital = rare
  - Transient lateral rectus paresis in 0.5 % newborns with spontaneous disappearance in 97% by 6 weeks (Reisner and co)

# Sixth nerve palsy : children

- *Etiology of isolated sixth nerve palsy : acquired*

Because of the long intracranial course the VI is very vulnerable to:

1. Increased intracranial pressure (hydrocephalus,tumor)
2. Trauma
3. Meningeal edema
4. Inflammation in the base of the skull
5. Displacement of the brain stem
6. Toxic substances
7. Demyelinating diseases
8. Viruses



CRANIAL N. VI  
HAS A LONG  
INTRACRANIAL  
COURSE

# Sixth nerve palsy : children

- *Etiology of isolated sixth nerve palsy : acquired (pediatric series: Robertson and co)*

1.	neoplastic	39 %
2.	traumatic	20%
3.	inflammatory	17 %
4.	miscellaneous	12 %
5.	undetermined	9 %
6.	vascular	3 %

# Sixth nerve palsy : children

- *Etiology of isolated sixth nerve palsy : acquired*
  - viruses :
    - varicella
    - influenza
  - bacterial meningitis
  - after lumbar puncture (benign, bilateral and self-limiting)
  - benign recurrent isolated sixth nerve palsies ( no pain, full recovery in 8 to 12 weeks, up to 11 recurrences)

# Sixth nerve palsy : children

- *Etiology of isolated sixth nerve palsy : acquired*

## **Gradenigo syndrome :**

- complication of otitis media and mastoiditis involving the petrous apex of the temporal bone ( pinching of the VI against the petrosphenoidal ligament)

# Sixth nerve palsy : children

- *Etiology of isolated sixth nerve palsy : acquired*
- Gradenigo syndrome :
  - young children
  - Respiratory infection
  - Elevated temperature
  - Facial pain
- R/ antibiotics: improvement in 3 to 6 weeks



# Sixth nerve palsy : children

- *Workup :*

1. History : recent illness or trauma?  
neurologic symptoms ?  
chronic ear infections?

2. Complete pediatric, neurologic, and ophthalmic examination  
(function of the other cranial nerves and appearance of the optic disc)

3. Otoloscopic examination

4. MRI of the brain

# Sixth nerve palsy : children

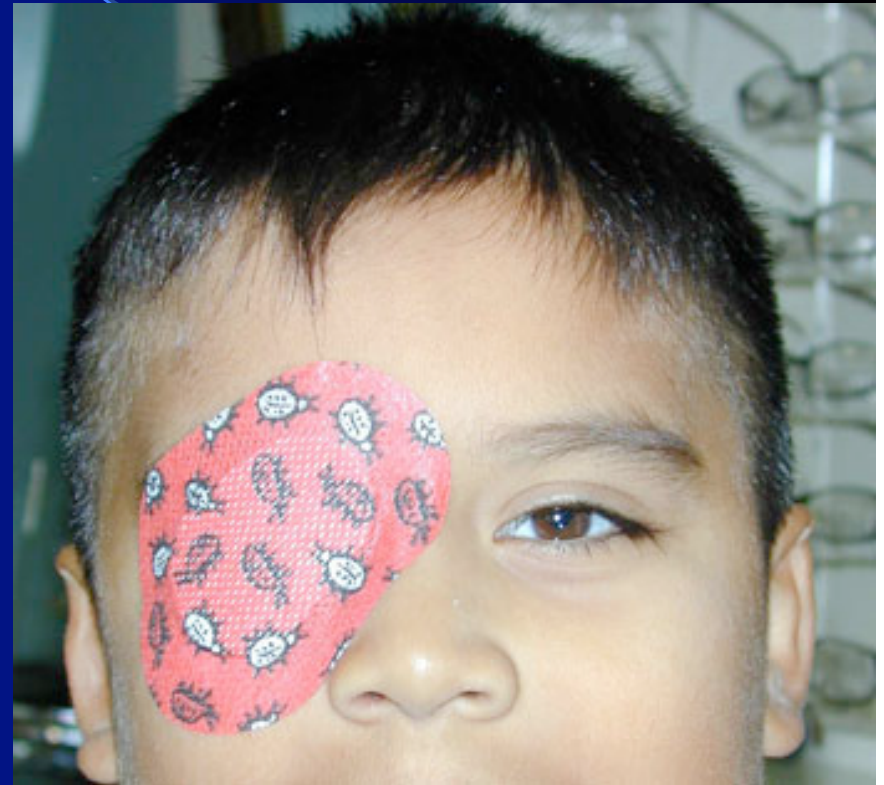- *Workup :*

If the palsy does not resolve spontaneously within 6 months, if esotropia worsens or if other clinical signs become evident, REPEAT MRI and lumbar puncture is indicated.

# Sixth nerve palsy : children

- *Treatment :*

1. Treatment of the underlying problem
2. Amblyopia treatment
3. Relief of symptomatic diplopia :
  - compensatory head posture
  - alternate occlusion
  - prisms
4. Strabismus surgery (stable deviation that persists more than 6 months)
5. ( botulinum toxin )



# Sixth nerve palsy : children

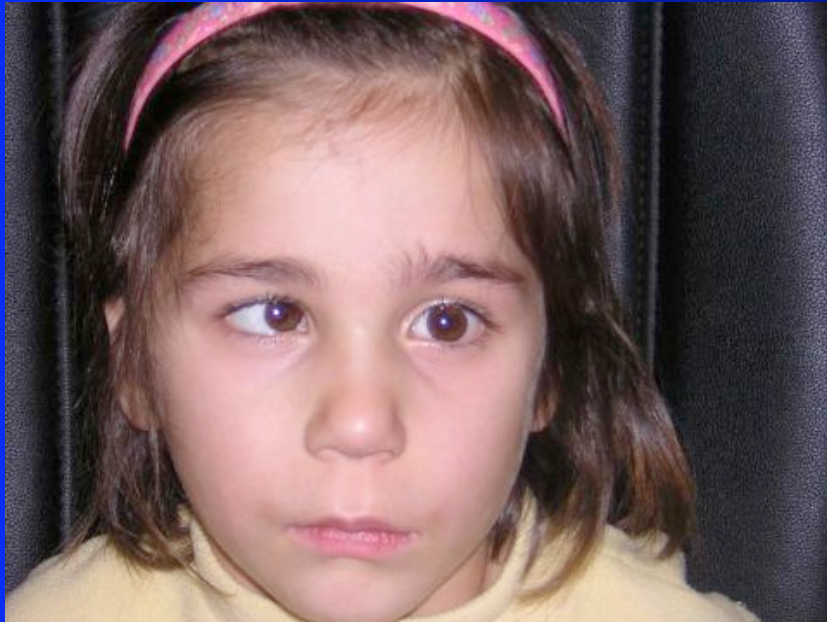- *Treatment : strabismus surgery*
  1. Moderate lateral rectus paresis ( the tone in the palsied lateral rectus is sufficient to abduct the eye beyond the midline) :  
recession medial rectus-resection lateral rectus
  2. Severe paresis or paralysis :  
muscle transfer procedure

# Sixth nerve palsy : children

- *Treatment : muscle transfer procedure*

1. Transposition of the vertical rectus muscle insertions to the lateral rectus insertion
2. Permanent joining of the vertical and lateral rectus muscles at the equator ( Jensen operation)
3. Modification by Hummelsheim: movement of only the temporal halves.

# Sixth nerve palsy : children



- Thank you for your attention