NEWBORN WITH BILATERAL HAZY CORNEAS

BLEYEN I. BARTELS M. C.**
*WOLFS R.C.W.**

SUMMARY

In this case report we present a preterm born baby with bilateral hazy corneas and initially normal intraocular pressures. After birth, the corneal opacification increased and a progressive buphthalmos became evident in the right eye. A trabeculectomy was performed in the right eye. Our final diagnosis was sclerocornea in combination with Peters' anomaly.

RÉSUMÉ

Nous présentons une prématurée avec deux cornées opaques et des tensions intra-oculaires initiallement normales. Après la naissance, la cornée s'est opacifiée encore plus et l'oeil droit a développé une buphtalmie progressive. Une trabéculectomie a été pratiquée à l'oeil droit. Notre diagnostic final est une sclérocornée combinée avec une anomalie de Peters.

KEY WORDS

Peters' anomaly, sclerocornea, buphthalmos, corneal opacification, intraocular pressure

MOTS-CLÉS

Anomalie de Peters, sclérocornée, buphtalmie, opacification de la cornée, tension intra-oculaire

.....

** Erasmus MC, University Hospital, Rotterdam*

received: 04.09.06
accepted: 21.10.06

CASE REPORT

On the second day after birth, a 28 weeks old preterm baby (46XX, weight of 935 grams and Apgar score at birth of 3/4/6) was presented to the ophthalmologist because of bilateral hazy corneas. The mother (G4, P0, A3) suffered from schizophrenia and was known to use Haldol and cannabis during this pregnancy. There was no known malnutrition. The father had also a psychiatric history and suffered from bilateral congenital cataract. There was no anterior segment dysgenesis described in either parent. Clinical examination of the preterm was normal except for the bilateral hazy corneas. Extensive screening for metabolic disorders and infections was negative. Toxic screening was negative for alcohol but positive for cannabis. Genetic examination could not yet be performed due to legal issues.

During the clinical ophthalmological examination the anterior chambers appeared normal and the lenses were presumably clear. An echo B scan examination showed an attached retina bilaterally. Retinopathy of prematurity could not be assessed due to the hazy corneas. It was not possible to measure the intraocular pressure with a Tonopen, but intraocular pressure was initially normal on palpation in both eyes. The central corneal opacification increased slightly and 4 weeks after birth the left cornea showed a central perforation with iris prolaps. This was treated conservatively with chloramphenicol ointment and drops. Two weeks later the intraocular pressure had increased on palpation in both eyes, more in the right than the left, and a progressive buphthalmos became evident in the right eye. The left eye was treated with timolol 0,1%. At the age of 6 1/2 weeks a trabeculectomy was performed in the right eye. No defined limbus could be seen and a smooth continuation between sclera and cornea made the exact measurement of the corneal diameter difficult (Figure 1). After the iridectomy a small vitreous prolaps was removed with Vannas scissors. Postoperatively the intraocular pressure remained stable around 14 mmHg in both eyes. Both corneas remained hazy, but the patient showed signs of searching for light. Our final diagnosis was sclerocornea in combination with Peters' anomaly.

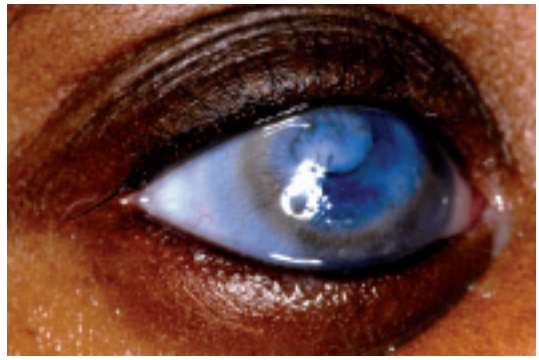

Figure 1. Sclerocornea with also central opacity caused by Peters'anomaly. Here the limbus is better recognizable, probably because of the older age of the patient.

DISCUSSION

Peters'anomaly, sclerocornea and congenital endothelial dystrophy represent mesenchymal dysgeneses of the cornea. In sclerocornea there is a peripheral, white, vascularized corneal rim that blends with sclera obliterating the limbus. The central cornea is generally normal. In total sclerocornea, the entire cornea is involved with a clearer central part. The opacification affects the full thickness of the stroma. Potentially coexisting abnormalities include shallow anterior chamber, iris abnormalities and microphthalmos. Systemic abnormalities include limb deformities, craniofacial and genitourinary defects (1, 9).

In Peters'anomaly there is a congenital central corneal opacity with corresponding defect in the posterior stroma, Descemet's membrane and endothelium. The cornea is rarely vascularized and usually clear at the periphery, although scleralization of the limbus is common. Other associated anterior segment abnormalities include glaucoma (50-70% of cases), anterior polar cataract and less often microcornea, microphthalmos, cornea plana, sclerocornea, colobomata and mesodermal dysgenesis of the angle and iris (3). Developmental mechanisms include faulty separation of the lens vesicle from the surface ectoderm, primary abnormal migration of neural crest cells into the cornea and intrauterine corneal inflammation (4, 12).

Table 1. *Previously mapped loci and genes known to cause anterior segment anomalies (2,4,10).*

Disorder	Chromosomal linkage	Gene
Aniridia	11p1318	PAX619
Axenfeld-Rieger Anomaly	6p25	FOXC13
Axenfeld-Rieger Syndrome	4q25 (RIEG1)20	PITX24
	13q14(RIEG2)21	Unknown
	6p2514	FOXC114
Iris Hypoplasia	4q25(RIEG1)22	PITX25
Iridogoniodysgenesis syndrome	-	PITX223
Peters anomaly	-	PAX624
	-	FOXE3
	-	PITX225
	-	CYP1B126
	-	FOXC1
Posterior polymorphous corneal dystrophy	20q1127	Unknown
Primary congenital glaucoma	1p3628	Unknown
	2p2129	CYP1B12

Genetics

Development of the anterior segment of the eye is a complex process that depends on multiple inductive events and coordinated interactions between cells of ectodermal, neuroectodermal, and neural crest origin. The neural crest is a specialized population of mesenchymal cells that emigrates from the dorsal margin of the neural folds at the time of neural tube closure. Cranial neural crest cells migrate and differentiate into various ocular tissues, such as the corneal endothelium and stroma, the iris stroma, the trabecular meshwork and the ciliary body stroma (7). It has been found that the cranial neural crest is especially vulnerable to teratogens and that the same malformation can be caused by many different agents. Stromland *et al.* describe various ocular teratogens in humans and the numerous possible effects on ocular development. Cannabis, however, is described as an unlikely teratogen (11).

Anterior segment morphogenesis appears to be particularly sensitive to deviations in expression levels of the regulatory genes on which it depends. Mutations in a number of transcription factor genes - all of which are involved in the control of developmental processes in other organs as well - cause congenital anterior segment malformations in the heterozygous state. Genetic defects causing many of the anterior segment disorders have been mapped to various chromosomal regions as shown in Table 1 (4, 6).

Table 2. *Associated ocular and systemic anomalies (8, 5).*

Ocular anomaly	Systemic anomaly
Glaucoma	Retarded growth
Microphthalmos	Cleft lip/palate
Colobomas	Conotruncal anomalies of the heart
Sclerocornea	Ear anomalies
Persistent fetal vasculature	Central nervous system anomalies
Buphthalmos	Urogenital anomalies
Optic nerve staphyloma	Facial anomalies
Optic atrophy	Laryngomalacia
	Macroglossia
	Limb malformations
	Joint laxity

Phenotypically

Peters' anomaly is usually seen as an isolated ocular defect, but associated ocular and systemic anomalies are described (Table 2). Mostly, the associated ocular and systemic anomalies in patients with Peters' anomaly are related to maldevelopment of the neural crest cells. Early treatment for those systemic anomalies is essential.

Ozeki et al. revealed that Peters'anomaly, with corneolenticular adhesion, other ocular anomalies or glaucoma, was accompanied by systemic anomalies more frequently than not. Therefore, these cases especially need to be evaluated for the presence of systemic anomalies (8).

Surgical management and visual outcome

Surgical management is mainly focused on corneal transplantation and glaucoma surgery.
Yang et al. showed that long-term graft clarity could be achieved in 36% of eyes, 93% of which were first grafts. Surgical intervention (one or more procedures) is effective in controlling IOP in 32% of eyes with associated congenital glaucoma, often requiring adjunctive medical therapy (13).
Visual outcome is guarded in children with Peters'anomaly. This may be explained, in part, by the high incidence of postoperative complications. Pervasive neurologic impairment - brain abnormalities, developmental delay, mental retardation, and other types of cognitive dysfunction - may also play an influential role in determining visual results. Furthermore, both anterior and posterior segment pathology and sensory aberrations - strabismic, anisometropic, and deprivational amblyopia - may also play a role as well as the inability of examiners to follow refractions, to institute refractive correction, and to enforce compliance (14).

References

(1) BHAT Y.R., SANOJ K.M. – Sclerocornea. *Indian Pediatr.* Mar 2005; 42:277.
(2) HONKANEN R.A., NISHIMURA D.Y., SWIDERSKI R.E., BENNETT S.R., HONG S., KWON Y.H., STONE E.M., SHEFFIELD V.C., ALWARD W.L.M. – A family with Axenfeld-Rieger syndrome and Peters Anomaly caused by a point mutation (Phe112Ser) in the FOXC1 gene. *Am J Ophthalmol.* 2003; 135:368-375.
(3) KENYON K.R. – Mesenchymal dysgenesis in Peters' anomaly, sclerocornea and congenital endothelial dystrophy. *Exp Eye Res.* 1975; 21:125-142.
(4) MATSUBARA A., OZEKI H., MATSUNAGA N., NOZAKI M., ASHIKARI M., SHIRAI S., OGURA Y. – Histopathological examination of two cases of anterior staphyloma associated with Peters' anomaly and persistent hyperplastic primary vitreous. *Br J Ophthalmol.* 2001; 85:1421-1425.
(5) NAJJAR D.M., CHRISTIANSEN S.P., BOTHUN E.D., SUMMERS C.G. – Strabismus and amblyopia in bilateral Peters anomaly. *J Am Ass Pediatr Ophthalmol Strabismus.* 2006; 10: 193-197.
(6) ORMESTAD M., BLIXT A., CHURCHILL A., MARTINSSON T., ENERBACK S., CARLSSON P. – Foxe3 haploinsufficiency in mice: a model for Peters' anomaly. *Invest Ophthalmol Vis Sci.* 2002; 43:1350-1357.
(7) OZEKI H., SHIRAI S. – Developmental eye abnormalities in mouse fetuses induced by retinoic acid. *Jpn J. Ophthalm.* 1998; 42: 162-167.
(8) OZEKI H., SHIRAI S., NOZAKI M., SAKURAI E., MIZUNO S., ASHIKARI M., MATSUNAGA N., OGURA Y. – Ocular and systemic features of Peters' anomaly. *Graefes Arch Clin Exp Ophthalmol.* 2000; 238:833-839.
(9) REZENDE R.A., UCHOA U.B., UCHOA R., RAPUANO C.J., LAIBSON P.R., COHEN E.J. – Congenital corneal opacities in a cornea referral practice. *Cornea.* 2004; 23:565-570.
(10) SEMINA E.V., BROWNELL I., MINTZ-HITTNER H.A., MURRAY J.C., JAMRICH M. – Mutations in the human forkhead transcription factor FOXE3 associated with anterior segment ocular dysgenesis and cataracts. *Human Molecular Genetics*. 2001; 10: 231-236.
(11) STROMLAND K., MILLER M., COOK C. – Ocular teratology. *Surv. ophthalm.* 1991; 35: 429-446.
(12) WARING G.O., RODRIGUES M.M. – Congenital and neonatal corneal abnormalities. In: Tasman W, Jaeger EA, eds. *Foundations of clinical ophthalmology*. Vol 1, Chap 9. Philadelphia: Lippincott, 1993; 1-38.
(13) YANG L.L., LAMBERT S.R. – Peters' anomaly. A synopsis of surgical management and visual outcome. *Ophthalmol Clin North Am.* 2001; 14:467-477.
(14) YANG L.L., LAMBERT S.R., LYNN M.J., STULTING R.D. – Surgical management of glaucoma in infants and children with Peters' anomaly: long-term structural and functional outcome. *Ophthalmology.* 2004; 111:112-117.

.....

Correspondence and reprints

Isabel BLEYEN
Belgielei 95 -97
B-2018 Antwerpen
isabelbleyen@yahoo.com