

TOPICAL ANESTHESIA WITHOUT INTRACAMERAL LIDOCAINE IN CATARACT SURGERY

SPIRITUS A.*, HUYGENS M.*, CALLEBAUT F.*

ABSTRACT

Purpose: To evaluate the efficacy of topical anesthesia with oxybuprocaine 0.4 % without intracameral lidocaine as an alternative to peribulbar or retrobulbar anesthesia in cataract surgery.

Methods: Fifty-eight patients (eighty-two eyes) were included in this study. All patients received topical anesthesia with oxybuprocaine 0.4 %. No intracameral lidocaine was used at the start of the intervention. Seventy-five per cent of patients received oral sedation with lorazepam 2.5 mg. All surgery was done using a superior corneal incision and phacoemulsification followed by a foldable IOL implantation. Subjective pain was assessed at 4 intervals during surgery using a 4-point pain scale. All patients were evaluated for intraoperative eye motility and blepharospasm. Patient and surgeon satisfaction was measured with a 4-point satisfaction scale.

Results: 15 % of patients experienced mild pain during phaco and 43 % had mild pain during corneal suturing. No patient had severe pain during the operation. In 4 % of patients, intracameral lidocaine was used to relieve pain. The surgeon and patient satisfaction was high. No eye movements or blepharospasm were recorded in 75 % and 62 % of cases respectively. No serious complications occurred.

Conclusion: Topical anesthesia is a safe and effective alternative to peribulbar and retrobulbar anesthesia in corneal cataract surgery for the experienced surgeon.

RESUME

But: Evaluer l'efficacité de l'anesthésie topique avec oxybuprocaine 0.4 % comme alternative pour

l'anesthésie péribulbaire et rétrobulbaire dans la chirurgie de la cataracte.

Méthodes: Cinquante-huit patients (quatre-vingt-deux yeux) ont été inclus dans notre étude. Tous les patients ont reçu une anesthésie topique avec oxybuprocaine 0.4 % sans lidocaïne dans la chambre antérieure. Septante-cinq pour-cent des patients ont reçu une sédation orale avec lorazepam 2.5 mg. La technique chirurgicale a toujours été l'incision cornéenne supérieure et phacoémulsification avec implant pliable. La douleur subjective a été évaluée 4 fois pendant l'intervention utilisant une échelle de 4 points. La motilité oculaire et les spasmes palpébraux ont également été évalués. La satisfaction du chirurgien et des patients a été évaluée avec une échelle de 4 points.

Résultats: 15 % des patients ont ressenti une légère douleur pendant la phaco et 43 % pendant les sutures cornéennes. Aucun patient n'a ressenti une sévère douleur. Dans 4 % des cas, de la lidocaïne 1% a été administré dans la chambre antérieure pour diminuer la douleur. La satisfaction du chirurgien et des patients était élevée. La motilité oculaire était bien contrôlée dans 75 % et les spasmes palpébraux dans 62 % des cas. Il n'y a pas eu de complications sérieuses.

Conclusion: Pour le chirurgien expérimenté, l'anesthésie topique est dans la chirurgie de la cataracte une alternative sûre et effective pour l'anesthésie péribulbaire et rétrobulbaire.

MOTS CLÉS

Anesthésie topique, oxybuprocaine, lidocaïne 1%, chirurgie de la cataracte, phacoémulsification.

KEY WORDS

Topical anesthesia, oxybuprocaine, intracameral lidocaine, phacoemulsification, cataract surgery.

* AZ St Lucas-St Jozef
Assebroek (Brugge)

received 04.10.99
accepted 29.12.99

INTRODUCTION

Advances in cataract surgery techniques with the advent of phacoemulsification and the consequent reduced surgical time, led to a renewed interest in topical anesthesia. Our goal was to study the subjective experience for both the patient and the surgeon using topical anesthesia in combination with oral sedation.

PATIENTS AND METHODS

Fifty-eight patients (eighty-two eyes) were included in the study. Very anxious patients, patients with communication problems and patients with miotic pupils or white cataracts were excluded. The age ranged from 50 to 89 years. All patients received topical anesthesia with oxy-

buprocaine 0.4 %: 3 times 1 drop at 2 minutes interval. Seventy-five per cent of patients received oral sedation with lorazepam 2.5 mg. Intracameral lidocaine 1 % was not used at the beginning of the intervention.

All cataract surgery was performed by the same surgeon (M.H). No bridle rectus suture was used. A 3.5 mm superior corneal incision was made. After capsulorhexis and phacoemulsification, a foldable intraocular lens was implanted. The surgeon evaluated the pain score 4 times: after corneal incision, capsulorhexis, phacoemulsification and corneal suturing. A 4-point pain scale was used to evaluate the subjective pain experienced by the patient: 0 = no pain; 1 = mild pain; 2 = moderate pain; 3 = severe pain.

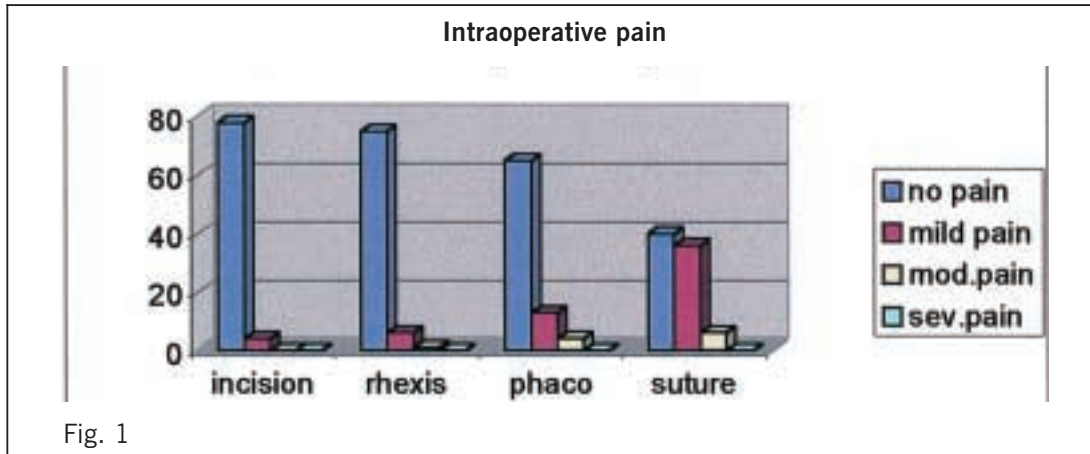


Fig. 1

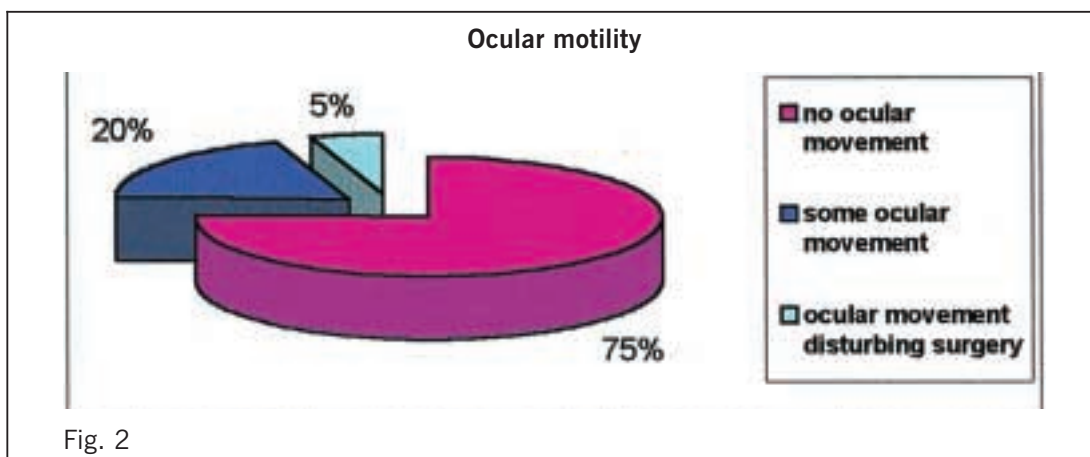
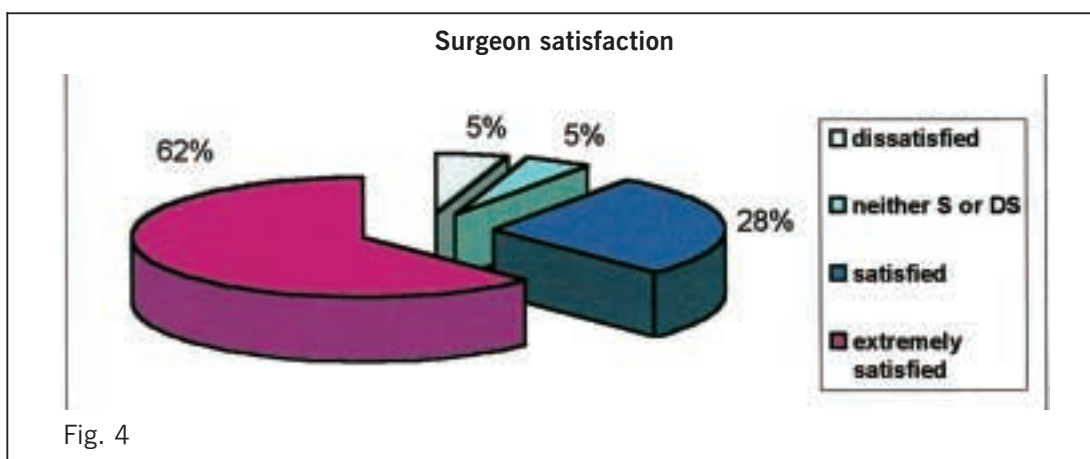
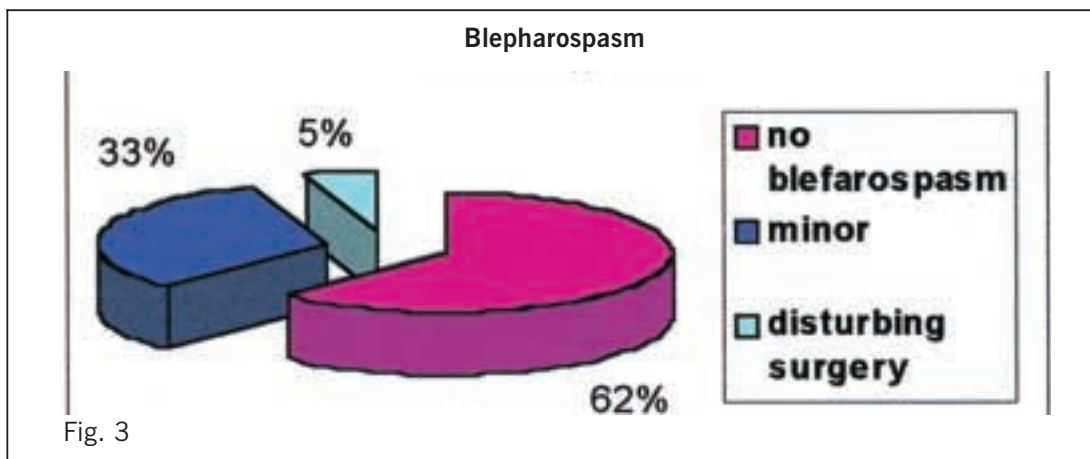


Fig. 2



Patients were asked to inform the surgeon if they experienced any pain at any time of the surgery. If so, one drop of oxybuprocaine was administered. If pain persisted, 0,5 ml preservative-free intracameral lidocaine 1% was used.

RESULTS

Intraoperative pain

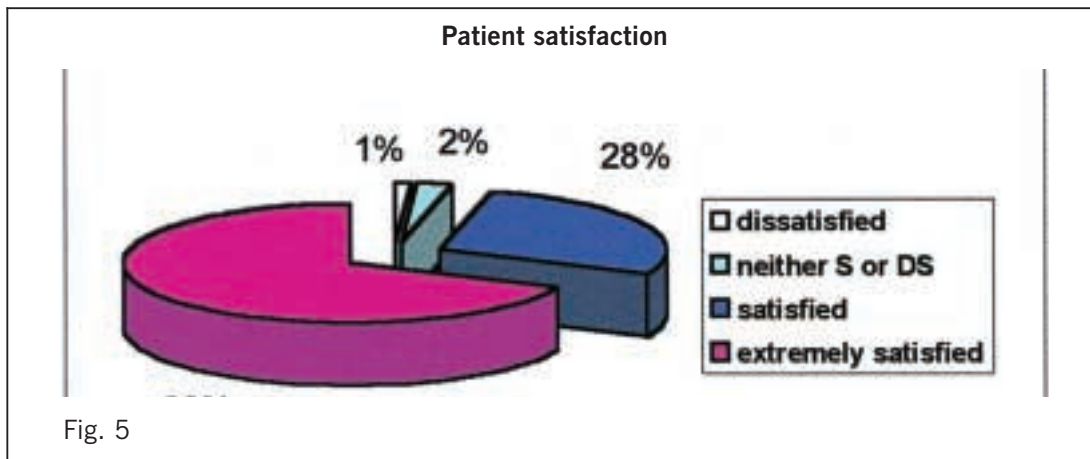
Five per cent and seven per cent of patients had mild pain during the incision and the capsulorhexis respectively. Fifteen per cent of patients experienced mild pain during the phacoemulsification and forty- three per cent during the corneal suturing (fig.1). No patient had severe pain during the entire intervention. In four per cent of patients, 0,5 ml intracameral lidocaine 1% was used to relieve pain.

Intraoperative surgical difficulties

Eye motility, blepharospasm, positive vitreous pressure and a poor patient compliance were the main reasons for surgical difficulties. No eye movements and no blepharospasm were recorded in seventy-five and sixty-two per cent of cases respectively (fig 2 and fig 3). Six per cent of patients had positive vitreous pressure. There was no case of conversion to retrobulbar injection.

Intra-and postoperative complications

No serious intraoperative complications occurred. There were 3 cases of mild corneal burns with postoperative wound leakage and 2 cases of positive Seidel requiring an additional suture. There were no cases of capsular rupture or vitreous loss.



Postoperatively, there was one patient with visual loss due to cystoid macular edema.

Surgeon satisfaction

The surgeon was very satisfied in 62 % of the operations, satisfied in 28 % and dissatisfied in only 5% of the interventions (fig 4).

Patient satisfaction

Figure 5 shows the patient satisfaction pattern. Sixty-nine per cent of the patients were extremely satisfied and twenty-eight per cent were satisfied. Only one per cent was dissatisfied. This was not related to the anesthesia technique but to the visual result (cystoid macular edema). All patients preferred topical anesthesia again if the other eye was not yet operated (fig 5).

DISCUSSION

Small incision cataract surgery under topical anesthesia has many advantages over traditional paraocular anesthesia: no pain from the anesthetic application, no needle-related complications (hemorrhage, globe perforation or optic nerve damage), no need to discontinue systemic anticoagulants or aspirin and immediate visual recovery.^{1,10} Nevertheless, topical anesthesia has also its limitations: the surgeon must be very competent to be comfortable, and not every patient is a good candidate: that is the reason why very anxious patients, patients

with communication problems, with miotic pupils or white cataracts were excluded.^{3,5}

The main disadvantage of topical anesthesia is the absence of akinesia. To achieve akinesia, patients were asked to look at the light of the microscope. To reduce photophobia, light intensity of the microscope was set initially to its lowest level and gradually raised to normal values at the beginning of the capsulorhexis.⁴

The surgeon's communication with the patient is very important: in order to relieve anxiety, he must warn the patient before each important step of the intervention.⁸ Encouraging the patient is very important to obtain optimal patient's cooperation.

With topical anesthesia, only the trigeminal nerve endings in the cornea and the conjunctiva are blocked. Failure of topical anesthesia to block the impulses in the long sensory fibers makes manipulation of the iris or stretching of the ciliary and zonular tissues uncomfortable for patients. Recently, a number of reports compared the patient comfort during cataract surgery with topical anesthesia alone versus topical anesthesia and intracameral lidocaine. In a randomized prospective trial using a ten-point visual analog pain scale, Crandall and coauthors² found no significant difference in intraoperative pain scores between patients who received topical anesthesia alone or patients who received topical anesthesia and intracameral lidocaine. However, other reports^{6,9} have shown that patients under topical anesthesia alone were more likely to experience

discomfort during iris manipulation and zonular stretching. In our study, the pain scale went up during phacoemulsification with fifteen percent of patients experiencing mild discomfort requiring intracameral injection of 0,5 ml lidocaine in 4% of cases.

The higher discomfort at the time of corneal suturing could be explained by the wearing off of the topical anesthetic due to the length of surgery and by the less anesthetic effect on scleral tissue. For this reason, after completing the study, we decided to add systematically anesthetic drops before corneal suturing. We also try to convert to self sealing temporal corneal incisions.

For surgeons wanting to convert to topical anesthesia, we believe they have to be very comfortable with the phaco procedure so that it can be carried out at a certain speed and with a minimum of intraocular manipulations. In the event that topical anesthesia proves to be inadequate, the surgeon can fill the chamber with viscoelastic agent, place a suture in the wound, give a retrobulbar injection and resume surgery.⁴

CONCLUSION

Our results demonstrate that topical anesthesia is a safe and effective alternative to peribulbar and retrobulbar anesthesia in cataract surgery for the experienced surgeon.

REFERENCES

- (1) CARINO, MD, SLOMOVIC, MD, CHUNG, MD – Topical tetracaine versus topical tetracaine plus intracameral lidocaine for cataract surgery. *J. Cataract Refr. Surg.* 1998; 24: 1602-1608
- (2) CRANDALL AS, ZABRISKIE NA, et al. – A comparison of patient comfort during cataract surgery with topical anesthesia versus topical anesthesia and intracameral lidocaine. *Ophthalmology.* 1999; 106: 60-66
- (3) ESTEVE C, KARILA A, JUNOT F, GHASSEMI A – Modalités anesthésiques de la cataracte sous topique. *Ophthalmologie* 1998; 12: 134-136
- (4) FICHMAN.R, MD – Use of topical anesthesia alone in cataract surgery. *J. Cataract Refr. Surg.* 1996; 22: 612-614
- (5) FRASER S, SIRIWADENA D, JAMIESON H, GIRAULT J – Indicators of patient suitability for topical anesthesia. *J. Cataract Refr. Surg.* 1997; 23: 781-783
- (6) GILLS JP, CHERCHIO M, RAANAN MG – Unpreserved lidocaine to control discomfort during cataract surgery using topical anesthesia. *J. Cataract Refr. Surg.* 1997; 23: 545-550
- (8) ROMAN S, AUCLIN F, ULLERN M – Topical versus peribulbar anesthesia in cataract surgery. *J. Cataract Refr. Surg.* 1996; 22: 1121-1124
- (9) TSENG H, CHEN FK – A randomized clinical trial of combined topical-intracameral anesthesia in cataract surgery. *Ophthalmology* 1998; 105: 2007-2011
- (10) ZEHETMAYER M, RADAX U, SKORPIK C, MENAPACE R – Topical versus peribulbar anesthesia in clear corneal cataract surgery. *J. Cataract Refr. Surg.* 1996; 22: 480-483

* Reprint requests:

Huygens M., AZ St Lucas-St Jozef
St Lucaslaan 29, 8310 Assebroek (Brugge)
Belgium