

# ORBITAL OSTEOMA: THREE CASE REPORTS

BENATIYA ANDALOUSSI I.\*; TOUIZA E.\*;  
BHALLIL S.\*; OUDIDI A.\*\*; BOUAYED M. A.\*;  
DAOUDI K.\*; EL ALAMI M. N.\*\*; TAHRI H.\*

## SUMMARY

### Introduction:

Osteoma is the most frequent benign tumor of paranasal sinuses. It is generally asymptomatic and usually discovered by chance during radiological imaging. Three cases with orbital extension are reported and discussed.

### Observations:

*1<sup>st</sup> observation:* Mrs. M.N. is an 18 years-old caucasian female who presented a stony orbital deformity associated with chronical dacryocystitis. Tomography of the orbit revealed a probable ethmoidal osteoma compressing the lacrimal canals. The management consisted in a surgical excision of the whole tumor by external approach, associated with a dacryocystorhinostomy. The patient's follow-up for the last 12 months was normal.

*2<sup>nd</sup> observation:* Miss K.A. is a 16 years-old caucasian female who came to consultation for a swelling of the medial angle of the left eye. Computed tomography images showed a fronto-ethmoidal process displaying a bone density consistent with an osteoma. The tumor was removed through an external ethmoidectomy. The patient was free of symptoms at 6 months follow-up.

*3<sup>rd</sup> observation:* Mrs. F. Z. is a 45 years-old patient who presented a 5 years history of right painful exophthalmos. The computed tomography was consistent with a fronto-ethmoidal osteoma with intraorbital extension near the optic nerve. The surgical excision was limited to the intraorbital portion. Post-operative complications included ptosis and diplopia.

.....

\* *Departement of Ophthalmology, Hassan II University Hospital, Fès, Morocco.*

\*\* *Departement of Oto-rhino-laryngology, Hassan II University Hospital, Fès, Morocco*

received: 20.03.06

accepted: 17.05.06

### Discussion:

Osteomas most commonly affect the fronto-ethmoid sinuses. They rarely show intraorbital extension or cause intracranial complications. They are generally asymptomatic. Symptoms are generally of late onset and are a consequence of tumoral growth and compression of neighbouring organs, as it is the case in our patients. Tumoral exophthalmos is the major ophthalmological sign. The computed tomography is of a great contribution, not only for diagnosis but also for the choice of the surgical approach. The classical surgical technique consists generally in a surgical excision of the osteoma. This surgery may induce ocular or neurosurgical complications.

### Conclusion:

Osteomas of the paranasal sinuses are usually asymptomatic. If they become voluminous, they may cause orbital manifestations and serious complications. The rarity of ethmoidal osteoma with orbital growth made our cases interesting to report.

## RÉSUMÉ

### Introduction:

L'ostéome orbitaire est une tumeur osseuse bénigne, communément asymptotique et souvent de découverte radiologique fortuite. Nous en rapportons trois cas à extension intra-orbitaire.

### Observations:

*Observation N° 1:* Madame M.N., âgée de 18 ans, présente une tuméfaction de consistance pierreuse intéressant l'angle interne de l'orbite gauche due à un ostéome ethmoïdal comprimant les voies lacrymales. Le traitement a consisté en une exérèse chirurgicale en bloc de la tumeur, et une dacryocystorhinostomie. Les suites opératoires se sont avérées normales après un recul de 12 mois.

*Observation N° 2:* Mademoiselle K.A., âgée de 16 ans, consulte pour une tuméfaction de l'angle interne de l'œil gauche. La tomodensitométrie (TDM) montre un processus fronto-ethmoïdal de densité osseuse fortement évocateur d'un ostéome. Le traitement a consisté en une exérèse chirurgicale en bloc.

Les suites opératoires se sont avérées simples après un recul de six mois.

*Observation N° 3:* Madame F.Z., âgée de 45 ans, présente une exophtalmie douloureuse unilatérale droite évoluant depuis 5 ans. La TDM révèle un ostéome fronto-ethmoïdal à extension intra-orbitaire affleurant le nerf optique. L'exérèse chirurgicale s'est limitée à la portion intra-orbitaire. Les suites opératoires ont été marquées par un ptosis et une diplopie.

*Discussion:*

Le siège orbitaire des ostéomes est particulièrement rare. Il est le plus souvent asymptomatique. Les symptômes sont généralement d'apparition tardive après croissance tumorale et compression des organes de voisinage, comme c'est le cas de nos patientes. L'exophtalmie d'allure tumorale en est le signe ophthalmologique majeur.

L'imagerie médicale, en particulier la tomodensitométrie, reste d'un grand apport, non seulement pour l'élaboration du diagnostic mais aussi pour le choix de la voie d'abord chirurgicale. Le traitement fait appel le plus souvent à l'exérèse chirurgicale en bloc. Cette chirurgie peut être émaillée de certaines complications oculaires voir neurochirurgicales.

*Conclusion:*

L'ostéome orbitaire est une tumeur bénigne à croissance lente pouvant entraîner des complications orbitaires graves. Ces observations nous ont paru intéressantes à rapporter du fait de la rareté des ostéomes ethmoïdaux à évolution orbitaire.

**KEY WORDS**

osteoma ,orbit, ethmoids, surgery

**MOTS-CLÉS**

ostéome, orbite, ethmoïde, chirurgie

Osteoma is the most common benign tumor of paranasal sinuses (10). It is generally asymptomatic and usually discovered on routine imaging techniques (1). If it becomes symptomatic, the most common manifestations are exophthalmos, headaches and facial pain. Throughout three cases with orbital extension, we analyze the different epidemiological, etiological, clinical and therapeutical aspects as well as the surgical difficulties occurring in the treatment of this affection

**1<sup>ST</sup> OBSERVATION:**

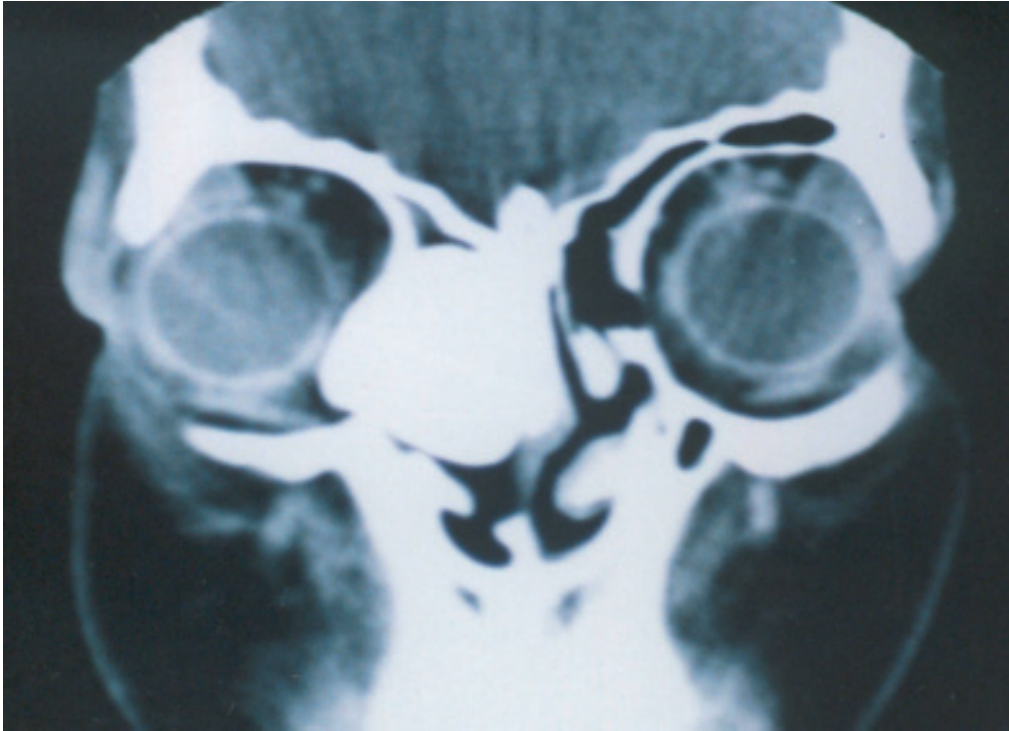
Mrs. M.N., an 18 years-old caucasian female, presented a stony orbital deformity associated with a chronic dacryocystitis. Standard X-rays associated with tomography of the orbit (fig.1) revealed a probable ethmoidal osteoma compressing the lacrimal canals. The management consisted in a surgical excision of the whole tumor using an external approach (fig.2), associated with a dacryocystorhinostomy. The pathological exam of the tumor was in favor of an osteoma. The patient's follow-up for the last 12 months was normal.

**2<sup>ND</sup> OBSERVATION:**

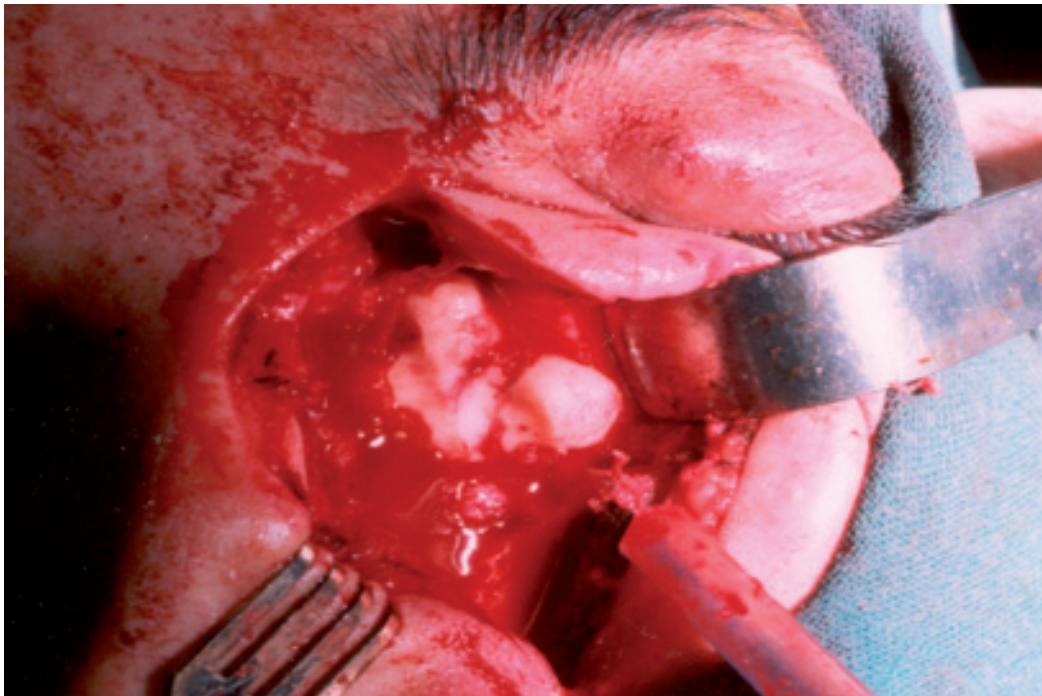
Miss K.A. is a 16 years-old caucasian female who came to consultation for a swelling of the medial angle of the left eye. The clinical exam revealed a stony consistency of the swelling without any other ocular lesions. The computed tomography showed a fronto-ethmoidal process displaying a bony density consistent with an osteoma. The tumor was removed through external ethmoidectomy (fig. 3 and 4). The patient was still free of symptoms after 6 months.

**3<sup>RD</sup> OBSERVATION:**

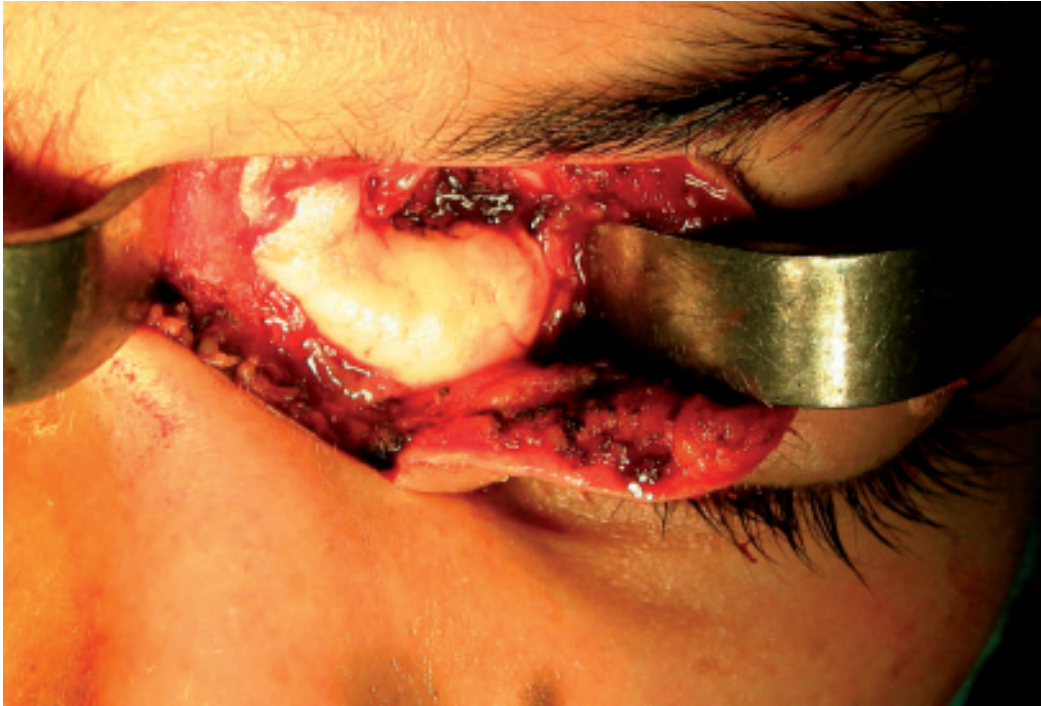Mrs. F.Z., a 45 years-old patient, presented a 5 years history of a right painful exophthalmos. The computed tomography of the head was consistent with a fronto-ethmoidal osteoma with intraorbital extension near the optic nerve (fig.5). The surgical excision was limited to the intraorbital portion (fig.6). Postoperative complications included ptosis, diplopia and supraorbital nerve anesthesia. All of them spontaneously resolved in the next 3 months



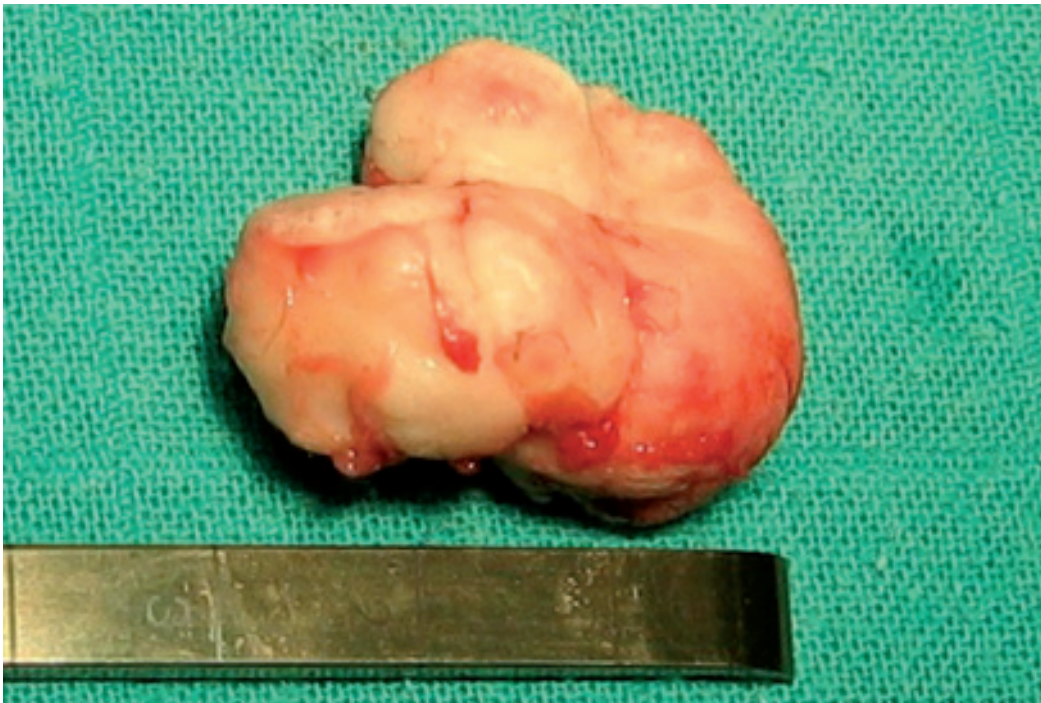*Fig. 1:* CT-scan of the head of the patient (1st case) showing an ethmoidal osteoma compressing the lacrimal tracts.



*Fig. 2:* Aspect of the ethmoidal osteoma in patient 1 before resection.



*Fig. 3: Preoperative aspect of the osteoma in patient 2.*



*Fig. 4: Aspect of the osteoma in patient 2 after surgical debulking of the tumor.*

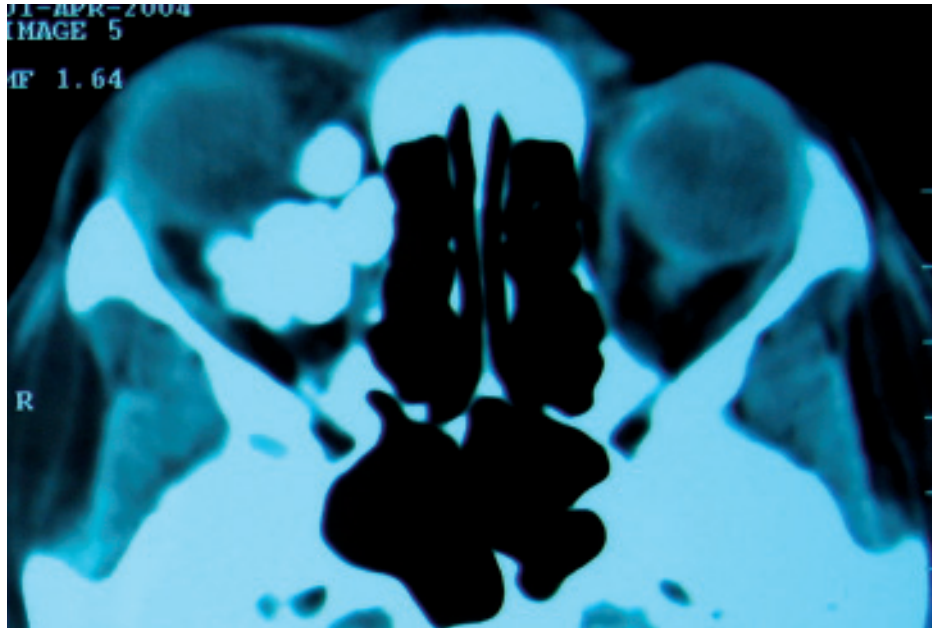


Fig. 5: Axial tomography of the orbital osteoma in patient 3.

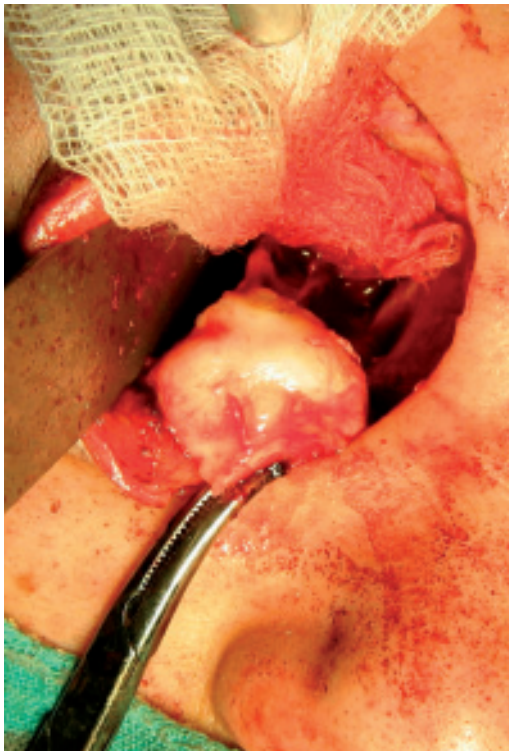


Fig. 6: Surgical resection of the orbital tumor in patient 3.

## DISCUSSION

Orbital osteoma was described for the first time in 1506 by Veigra who reported the case of an osteoma of the superior medial angle of the orbit diagnosed in a young woman who presented an exophthalmos with facial distortion.

Orbital localization of osteomas is particularly rare, and their incidence represents 0.9 to 5.1% of all orbital tumors (9, 10). The mean age is 46.4 years with sex ratio men/women of 1.85. This is thought to be secondary to the fact that men are more exposed to traumas than women, and also have larger sinuses. These hypotheses don't correlate with our cases since they are all females, with no reported history of trauma or megasinus.

The osteoma is a mesenchymal tumor that develops at the expense of bones and sinuses of the face. The most frequent sites of origin are the frontal sinus in 71.8% (2) of cases, the ethmoidal sinus in 16.9% (as described in our cases), the maxillary sinus in 6.3% and the sphenoidal sinus in 4.9%. The growth rate is very slow, from 12 to 30 years according to reported series, and eventough after incomplete excision, relapse may occur after 2 to 8 years (11, 13).

The size of osteomas is variable. They can measure up to 12.5 cm. In our reported cases, it varied between 3 and 4.2 cm.

The majority of osteomas have a smooth surface. However, as for our patients 1 and 3, they can be multilobular, especially if they are located in the ethmoidal sinus where cells branch out in a pseudopode-like shape.

Orbital osteoma is usually asymptomatic. Symptoms are generally of late onset and are a consequence of tumoral growth and compression of neighbouring organs (1, 3). The tumor-induced proptosis is the major ophthalmological sign (case n° 3). Other possible symptoms include diplopia secondary to oculomotor muscle involvement, choroidal folds, papillary oedema, optic nerve compression and atrophy, orbital cellulitis, and lacrimal tract obstruction (case n° 1). The extraocular manifestations may be: headache in 60% of cases (case n° 3), facial distortions, rhinorrhea, anosmia, as well as psychological disturbances such as altered mental status, confusion, amnesia, etc.

Radiological imaging, particularly the computed tomography scanning, is of a great contribution, not only for diagnosis but also for the choice of surgical approach (2).

Several pathogenical hypotheses are proposed (4, 7):

- Genetical theory: genetical factors are probably playing an important role in the development of osteomas included in Gardner's syndrome characterized by intestinal polyps and multiple osteomas (12);
- Traumatological and embryonal theories explaining the metaplasia of the connective tissue, the sinusal mucosa behaving like a periosteum and developing a bony substance;
- Infectious theory: very discussed, according to which the bony metaplasia is secondary to a chronic infectious and inflammatory state.

The therapeutical attitude depends on the tumor size, location, and extension and on the presence or not of complications (3).

Asymptomatic and small orbital osteomas are generally respected and require a yearly clinical and radiological control.

The surgical treatment is indicated:

- In case of a voluminous osteoma and complicated as in our observations.

- In sphenoidal localization threatening the visual function even though the tumor is small and asymptomatic.
- More rarely for aesthetic worries.

The classical surgical technique consists (4, 6) generally in a surgical excision in block by a transfacial way after an eyebrow or paralateral-nasal incision according to the tumor site. The difficulties of this approach are first the risk of sacrifice of the big oblique pulley, secondly the oculomotor paralysis (Case 3) if not an osteomeningeal breach. Other neurosurgical approaches by craniotomy or mixed (transfacial and neurosurgical) are reserved to osteomas with cerebral extension (10).

The resection by nasal endoscopy (5, 8) constitutes a new sure and efficient surgical alternative, offering some aesthetic advantages and lowering the morbidity noted in the classical surgical techniques. This approach is not possible for voluminous orbital osteomas.

## CONCLUSION

Osteomas of the paranasal sinuses are usually asymptomatic. If they become voluminous, they may cause orbital manifestations and serious complications. The rarity of osteomas in ethmoidal location with orbital growth made our cases interesting to report.

## REFERENCES

1. BECELLI R., SANTAMARIA S., SALTAREL A., CARBONI A., IANNETTI G. – Endo-orbital osteoma: two case reports. *J Craniofac Surg.* 2002; 13: 493-6
2. FOBE L.P., MELO E.C., CANNONE L.F., FOBE J.L. – Surgery of frontal sinus osteoma. *Arq Neuropsiquiatr.* 2002; 60:101-5.
3. GOLDENBERG D., GILBOA M., DANINO J., FLAX-GOLDENBERG R., MILLER B., JOACHIMS H.Z. – A large ethmoido-orbital osteoma presenting with in an 11-year-old boy. *J Pediatr Ophthalmol Strabismus.* 2000; 37: 238-240.
4. HALHAL M., NACIRI M., BERBICH O., BENABDELLAH W., BERRAHO A. – Osteoma of the orbit, a case report. *J Fr Ophtalmol.* 2000; 23: 888-91.
5. HUANG H.M., LIU C.M., LIN K.N., CHEN H.T. – Giant ethmoid osteoma with orbital extension, a nasoendoscopic approach using an intranasal drill. *Laryngoscope.* 2001; 111: 430-2.

6. KARAPANTZOS I., DETORAKIS E.T, DRAGONAKI E.E., GANASOULI D.L., DANIELIDES V., KOZOBOLIS V.P – Ethmoidal osteoma with intraorbital extension: excision through a transcutaneous paranasal incision. *Acta Ophthalmol Scand.* 2005; 83: 392-4.
7. MANSOUR A.M., SALTI H., UWAYDAT S., DAKROUB. R., BASHSHOUR.Z – Ethmoid sinus osteoma presenting as epiphora and orbital cellulitis: case report and literature review. *Surv Ophthalmol.*1999; 43:413-26,.
8. SCHICK B., STEIGERWALD C., EL RAHMAN EL TAHAN A., DRAF W. – The role of endonasal surgery in management of frontoethmoidal osteoma. *Rhinology.* 2001; 39: 66-70.
9. SELVA D., WHITE V.A., O'CONNELL J.X., ROOTMAN J. – Primary Bone Tumors of the Orbit. *Surv Ophthalmol.* 2004; 49: 328-42.
10. SIREB B.S., BENDA P.M., STANLEY R.B. Jr, ROSEN CE. – Orbital osteoid osteoma. *Arch Ophthalmol.*1999; 117: 414-5.
11. SPENCER M.G., MITCHELL D.B. – Growth of a frontal sinus osteoma. *J Laryngol Otol.* 1987; 101:726-8.
12. WHITSON W.E., ORCUTT J.C., WELWINSKAW M.D. – Orbital osteoma in Gardner's syndrome. *Am J Ophthalmol.* 1986; 101: 236-41.
13. ZOULOUMIS L., LAZARIDIS N., MARIA P, EPIVATIANOS A. – Osteoma of the ethmoidal sinus: a rare case of recurrence. *Br J Oral Maxillofac Surg.* 2005; 43:520-2.

**ACKNOWLEDGEMENTS:**

Benchaqroun Karimi Hassan, MD and Benjaber Kawtar, MD for their help in translation.

.....

*Correspondence and reprints:*

*Idriss BENATIYA ANDALOUSSI  
N° 3, rue Al Yamam, Avenue Nouakchoutt,  
Zohor I, Fès, Maroc.  
E-mail: cherdoc@hotmail.com*