

# COMPARATIVE SAFETY PROFILE BETWEEN “MODERN” TRABECULECTOMY AND NON-PENETRATING DEEP SCLERECTOMY

DETRY-MOREL M. \*, POURJAVAN S. \*,  
DETRY M.B. \*

---

## ABSTRACT

*Purpose:* To compare the incidence and the severity of short- and medium-term complications following “modern” trabeculectomy (mTRAB) with non-penetrating deep sclerectomy (NPDS).

*Material-Methods:* Comparative retrospective non randomized study including 65 eyes (55 patients) (mean age: 68.6 years) with medically uncontrolled glaucoma. mTRAB was performed in 43 eyes, NPDS in 22 eyes. mTRAB was performed according to a slightly modified P.T. Khaw protocol. NPDS procedures were done according to Kozlov's and Mermod's technique with SKGEL® implant in 18/22 eyes. Intraoperative antimetabolites (AMETAB) were given in 25 eyes (58%) in the mTRAB and 17 (77%) in the NPDS ( $p > 0.05$ ).

*Results:* Mean follow-up was longer in NPDS ( $10.7 \pm 5.5$  months) than in mTRAB ( $8.5 \pm 3.4$  months) ( $p < 0.05$ ). Preoperatively, the two groups were comparable in respect of age, type of glaucoma, mean IOP, severity of VF defects and bleb failure risk factors ( $p > 0.05$ ). Peroperatively, mTRAB were uneventful in 86% vs 90% of NPDS. 1<sup>st</sup> month postop complications occurred in 60.4% in mTRAB and 77.2% in NPDS ( $p > 0.05$ ). Most of them were minor and transient in both surgeries. Postop early anterior chamber inflammation was mild to moderate

in all cases. The incidence of wound leaks (21% in the mTRAB group and 18% in the NPDS group) and hyperfiltration related complications (14% and 13.6% respectively in the mTRAB and NPDS group) were comparable between the two procedures ( $p > 0.05$ ). Intraoperative antimetabolite application was not associated with an increased rate of postoperative hyperfiltration related complications. Scarring of filtration blebs had concerned a lower percentage of mTRAB eyes (19%) than the NPDS (36%). The number for 5-FU injections was less – although not significantly – in the mTRAB than in the other group (18.6% in mTRAB versus 41% in NPDS ( $p = 0.05$ )). Late complications were not observed in the mTRAB group. Iris prolapse associated with increased IOP occurred in 3 of the 22 NPDS procedures (13.6%). Final mean visual acuity was unchanged compared with preop value and was similar between the 2 groups ( $p > 0.05$ ). Diffuse, mildly vascularized filtration blebs were observed in 84% in mTRAB and 64% in DS ( $p > 0.05$ ). Mean IOP significantly decreased from  $24.8 \pm 8.3$  mm Hg to  $13.4 \pm 4.3$  mm Hg in mTRAB and from  $25.1 \pm 6.5$  mm Hg to  $14.7 \pm 4.6$  mm Hg in DS ( $p > 0.05$ ). It was not different between the 2 groups with and without AMETAB augmentation. 70% of the mTRAB achieved a final IOP  $\leq 15$  mmHg vs 41% in NPDS ( $p < 0.05$ ). The mean number of postop medications was 0.49 in mTRAB and 0.96 in NPDS ( $p < 0.05$ ). Complete (target IOP reached without meds) and qualified (target IOP reached with and without meds) final success rates were 60% and 88% in mTRAB and 36.4% and 68.2% in NPDS ( $p > 0.05$ ).

*Conclusions:* Whether surgery was augmented with intraoperative antimetabolite or not, mTRAB revealed as a priority to be associated with comparable and even less complications than deep sclerectomy.

.....

\* Cliniques Universitaires St Luc  
UCL  
Brussels

received: 22.02.06

accepted: 30.04.06

tomy. Owing to the limitations of our study and until further confirmation, our results have suggested that mTRAB was associated with a slightly more important IOP reduction as well as higher success rates than NPDS.

## RÉSUMÉ

**Objectif:** Le but de notre étude est de comparer l'incidence et la sévérité des complications observées à court et moyen terme dans le décours de la "trabéculéctomie revisitée" (mTRAB) par rapport à celles de la sclérectomie profonde (SP).

**Matériel-Méthodes:** Nous avons conduit une étude rétrospective, non randomisée incluant un total de 65 yeux (55 patients, âge moyen: 68.6 ans) porteur d'un glaucome non contrôlé médicalement. Le groupe des trabéculéctomies "revisitées" comprend 43 yeux, celui des sclérectomies profondes, 22 yeux. Les mTRAB ont été réalisées selon une variante légèrement modifiée de la technique de P.Khaw, les SP selon la technique de Kozlov et de Mermoud et ont été associées à la mise en place d'un implant SKGEL® dans 18/22 cas. Nous avons eu recours à une application d'un antimétabolite en peropératoire dans 25 mTRAB (58%) et 17 SP(77%) ( $p > 0.05$ ).

**Résultats:** Le recul moyen est plus long dans le groupe des SP ( $10.7 \pm 5.5$  mois) que dans celui des mTRAB ( $8.5 \pm 3.4$  mois). En préopératoire, les 2 groupes sont comparables aussi bien pour ce qui a trait à l'âge des patients, le type de glaucome, la PIO moyenne, la sévérité des déficits périmétriques, et les facteurs d'échec de la chirurgie filtrante ( $p > 0.05$ ). 86% des mTRAB, 90% des SP se sont déroulées sans complications. Au cours du 1<sup>er</sup> mois post-op, nous avons observé des complications dans 60.4% des mTRAB et 77.2% des SP ( $p > 0.05$ ). La plupart d'entre elles étaient mineures et transitoires et ce dans les deux techniques. L'inflammation de chambre antérieure a été légère à modérée dans tous les cas. L'incidence des fuites conjonctivales (21% dans les mTRAB et 18% dans les SP) et des complications d'hyperfiltration (14% dans les mTRAB et 13.6% dans les SP) a été comparable dans les deux techniques ( $p > 0.05$ ) et n'a pas été plus élevée dans les cas où un antimétabolite a été employé en peropératoire. Des problèmes de fibrose conjonctivo-ténonienne ont été observés dans 19% des mTRAB versus 36% des SP. Le recours à des injections sous-conjonctivales de 5-Fluorouracile a été moins fréquent dans le groupe des MTRAB que dans celui des SP (18.6% versus 41%) ( $p = 0.05$ ). Plus à distance de la chirurgie, nous n'avons pas observé de complication particulière dans le groupe des mTRAB. Un enclavement de l'iris associé à une hypertonie oculaire est survenu dans 3 cas de SP (13.6%). L'acui-

té visuelle finale a été maintenue à son niveau préopératoire, sans différence entre les 2 techniques ( $p > 0.05$ ). Dans 84% des mTRAB et 64% des SP, la bulle de filtration apparaît diffuse et discrètement vascularisée ( $p > 0.05$ ). La PIO moyenne est passée de  $24.8 \pm 8.3$  mmHg à  $13.4 \pm 4.3$  mmHg dans le groupe des mTRAB et de  $25.1 \pm 6.5$  mmHg à  $14.7 \pm 4.6$  mmHg dans celui des SP ( $p > 0.05$ ). La PIO finale s'est révélée comparable entre les 2 techniques qu'il y ait eu ou non emploi d'un antimétabolite en perop. 70% des mTRAB ont une PIO finale  $\leq 15$  mmHg vs 41% des SP. Le nombre moyen des médicaments d'appoint au dernier contrôle est de 0.49 pour la mTRAB et de 0.96 pour la SP ( $p < 0.05$ ). Les taux de succès complet (PIO cible atteinte sans médicaments) et relatif (PIO cible atteinte avec et sans médicaments) sont de 60% et de 88% pour la mTRAB et de 46.4% et 68.2% pour la SP ( $p > 0.05$ ).

**Conclusion:** Qu'il y ait application ou non d'un antimétabolite pendant l'intervention, notre étude montre en priorité que la trabéculéctomie "revisitée" est associée à un taux de complications comparable, sinon légèrement inférieur à celui de la sclérectomie profonde. Compte tenu de ses limites et jusqu'à plus ample confirmation, notre analyse suggère secondairement que la trabéculéctomie donne une chute de PIO et des taux de succès légèrement supérieurs à ceux de la sclérectomie profonde.

## KEY WORDS

Glaucoma surgery, trabeculectomy, non-penetrating drainage glaucoma surgery, deep sclerectomy, antimetabolites.

## MOTS-CLÉS

Chirurgie du glaucome, trabéculéctomie, chirurgie non perforante du trabéculum, sclérectomie profonde, antimétabolites.

Improvement of the complication profile and the efficacy of glaucoma filtering surgery is still a major concern for glaucoma surgeons (4, 20, 22). Non-penetrating deep sclerectomy (NPDS) has been shown to be associated with less frequent early postoperative complications than standard Cairn's trabeculectomy, albeit most often at the expense of less satisfactory long-term control of the intraocular pressure (IOP) (2, 4-6, 9, 12, 14, 15, 17, 18, 19, 22, 24). Revisited by P.T. Khaw in this early millennium, "modern" trabeculectomy (mTRAB) differs from standard trabeculectomy in a specific instrumentation and technical refinements aiming at minimizing the incidence and the severity of hyperfiltration related complications, at promoting posterior unrestricted drainage of aqueous, and therefore at increasing the postoperative success of surgery and the quality of the filtration blebs (3, 10, 12, 13). To the best of our knowledge, results of this recently revisited approach have neither been reported nor compared with NPDS yet.

The purpose of our study was to evaluate the incidence and the severity of peroperative, early and medium-term postoperative complications observed after mTRAB compared with those after NPDS according to the two procedures have been augmented with intraoperative antimetabolites or not.

## MATERIAL-METHODS

### 1. PATIENTS

This was a comparative, retrospective, non randomized, interventional case study including a total of 65 consecutive procedures performed between July 2003 and November 2004 by the same surgeon (M.D.M) in 55 patients (34 female and 21 male) suffering from glaucoma refractory to maximally tolerated medical therapy. The mean age of patients was  $68.6 \pm 15.1$  years (range: 14 to 91 years). African ethnicity concerned 2 patients in the mTRAB group. "Modern" trabeculectomy (mTRAB) was performed in 43 eyes whereas NPDS was done in 22 out of the 65 eyes.

## 2. SURGERY

### A. "MODERN" TRABECULECTOMY

Trabeculectomy was performed according to a slightly modified P. Khaw's protocol as following and illustrated on the figure 1(10,12).

1. Placement of a superior 9-0 vicryl peripheral corneal traction.

Dissection of a fornix-based conjunctival flap on 2 hours o'clock width with dissection of conjunctiva and Tenon's capsule backwards. Haemostasis using bipolar cautery.

Dissection of a rectangular 4 x 3 mm scleral flap (about 50% of the scleral thickness) and continuation into a sclerocorneal tunnel on its anterior one third.

2. Preplacement of two nylon 10-0 adjustable sutures in the bed of two corneal grooves performed at 0.5 mm from the limbus in front of the lateral sides of the scleral flap. Preplacement of one releasable suture.

3. Paracentesis in the inferior temporal quadrant with a V-Lance™ Knife 20 Gauge 1.3 mm (Alcon®). Introduction of a Blumenthal conic anterior chamber maintainer canula (B.D. Visitech® FL, USA) connected to an infusion bottle in order to provide anterior chamber continuous infusion.

Positioning of the infusion bottle at 50 cm above the patient's head to maintain an intracameral IOP of about 10 mm Hg.

4. Trabeculectomy in a deep block dissection with the 0.5x0.5 Khaw's small Descemet membrane punch (Duckworth and Kent™, Lentsita™ for Belgium)

5. Peripheral iridectomy.

Topical atropine 1% administration.

6 and 7. Closure of the scleral flap by tying up of adjustable sutures with a seamanship's knot (slipknots consisting in 4 simple loops). Closure of the preplaced releasable suture. If needed and according to the degree of observed filtration, placement of one or more additional releasable sutures with buried knots. A slight aqueous percolation through the interstices of the scleral flap must be still observed at this time.

8. Tight closure of the conjunctivo-tenonian flap with 10-0 Biosorb® (P-3 needle)(Alcon®) separate sutures.

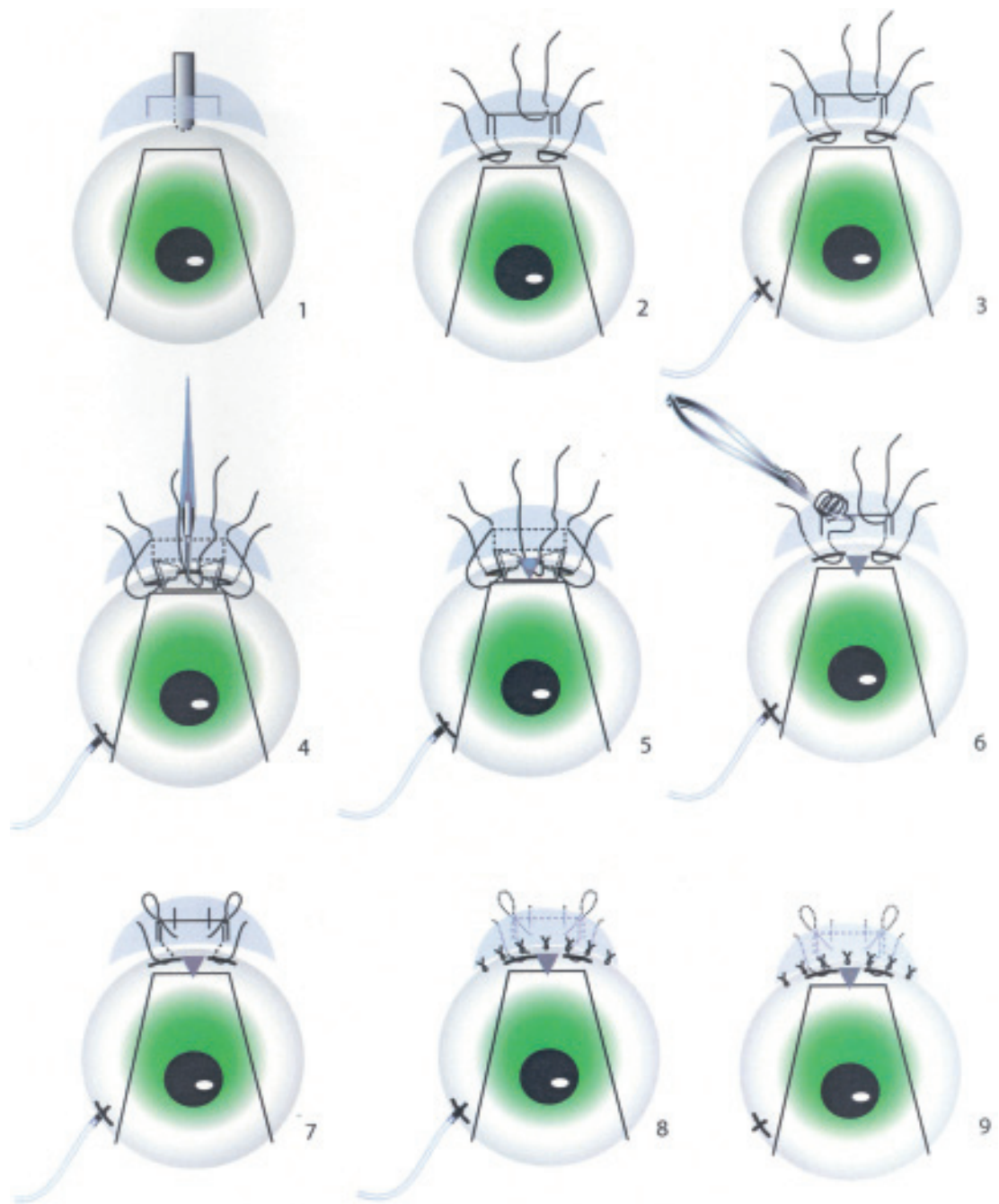


Fig 1. "Modern" trabeculectomy: step by step.

Michèle lemaire

9. Withdrawal of the anterior chamber infusion canula and suture of paracentesis with a nylon 10-0 monofilament.

-Inferior subconjunctival injection of betamethasone (4mg/ml).

#### B. NON-PENETRATING SCLERECTOMY.

Deep sclerectomy has been performed according to the following Kozlov and Mermoud's technique (17). After placement of a superior 9-0 vicryl peripheral corneal traction, a fornix-based conjunctival flap was dissected superiorly on about 3 hours and the sclera was exposed. A one third scleral thickness limbus based scleral flap measuring 5 x 5 mm was dissected anteriorly into clear cornea for about 1.5 mm. A second triangular deep scleral flap was then dissected leaving only a very thin layer of deep sclera over the choroid. Anteriorly the dissection was carried down to unroof and remove Schlemm's canal and juxtacanalicular trabeculum. More anteriorly, the excision of corneal stroma was carried down to Descemet's membrane. At this stage of the procedure, aqueous humor was seen to percolate through the thin remaining trabeculo-Descemet membrane.

After excision of the deep triangular scleral flap, a triangular 3.5 x 3.5 mm reticulated hyaluronic acid implant (SKGEL<sup>®</sup>, CORNEAL<sup>®</sup>, Paris, France) was placed in the center of the deep sclerectomy dissection site in 18 out of the 22 eyes (82%) whereas Healon GV<sup>®</sup> (AMO) was applied in the other cases.

The rectangular superficial scleral flap was then repositioned over the SKGEL<sup>®</sup> implant or the Healon GV<sup>®</sup> and closed with 10-0 monofilament nylon sutures with buried knots. Finally, the conjunctivo-tenonian flap was carefully sutured with 10-0 Biosorb<sup>®</sup> (P-3 needle)(Alcon<sup>®</sup>) separate sutures.

#### C. INTRAOPERATIVE ANTIMETABOLITE APPLICATION

In both groups, 2 or 3 small sponges soaked with 5 fluorouracil (5-FU)(50mg/ml) or Mitomycin C (0.1-0.2 mg/ml) were applied after the dissection of the conjunctiva and before the dissection of the scleral flap, when needed. Sponges were placed beneath the conjunctival flap

as posteriorly as possible to increase the antimetabolite treatment area.

Intraoperative antimetabolite application was comparable in the two surgical groups and was performed in 25 out of the 43 eyes (58%) in the mTRAB group and 17 out of the 22 eyes (77%) in the NPDS group (chi-square p-value  $p > 0.05$ ). 5-FU was used in 4 eyes of each group with a mean duration of application of  $144 \pm 53$  seconds (range:45 seconds to 180 seconds). Mitomycin C augmentation was comparable in the two groups, with a total of 21 eyes in the trabeculectomy group and 13 eyes in the NPDS group ( $p > 0.05$ ) (Table 1).

The mean duration of application of Mitomycin was  $60 \pm 53$  seconds in the mTRAB group and  $36 \pm 13$  seconds in the NPDS group ( $p > 0.05$ ).

#### D. FIRST MONTH POSTOPERATIVE MANAGEMENT

First month postoperative management in the mTRAB group included step-by-step laser suture lysis and withdrawal of releasable sutures. According to the spontaneous evolution, laser suture lysis was considered between day 3 and day 14. Releasable sutures were generally withdrawn from the surgical corneal groove within one week interval, using a jeweller's forceps at the third postoperative week.

Due to technical difficulties, control and mobilization of adjustable sutures with a special transconjunctival forceps (Khaw Transconjunctival Adjustable Suture Control Forceps manufactured by Duckworth and Kent<sup>TM</sup>) was not done during the early postoperative visits.

Table 1: Summary of intraoperative use of antimetabolites

	MTRAB (n=43)	NPDS (n=22)
<b>Antimetabolites</b>	<b>25 (58%)</b>	<b>17 (77%)</b>
5-Fluorouracil (5-FU) (45 to 180 sec)	4	4
Mitomycin C 0.1 mg/ml	7	6
Mitomycin C 0.2 mg/ml	14	7
Mitomycin C (MMC) (mean duration of application)	$60 \pm 53$ sec	$40 \pm 19$ sec



In the NPDS group, goniotomy with Nd:YAG laser was performed when failure with raised IOP was documented.

In both groups, postoperative topical treatment consisted in a combination of framisetin, dexamethasone three times daily for 4 weeks. If needed, cyclopentolate was instilled once or twice daily during the early postoperative days. Moreover 5-FU (5 mg) injections were given whenever clinical signs of excessive filtration bleb scarring were observed. Bleb needling was performed when Tenon's cyst was visible.

Complete ocular examination was carried out preoperatively and postoperatively, at day 1, 7, at 1, 2, and 3 months and every 3 months thereafter.

According to their morphologic characteristics, the filtration blebs were classified as follows: 1. flat, diffuse, vascularized bleb. 2. mildly elevated, vascularized bleb. 3. flat, diffuse and avascular bleb. 4. cystic and avascular bleb.

### 3. SUCCESS CRITERIA

Complete success was defined as a clinical target IOP reached without medication for each patient at the last examination.

Qualified success was considered when an individual final target IOP was reached with or without medication.

The calculation of target IOP was done using H. Jampel's formula (11):

Target IOP = maximum IOP – maximum IOP% – Z (Z = optic nerve damage severity factor).

When "maximum" IOP (which is the value of IOP at which glaucomatous damage presumably occurred) was unknown, the calculation was based on the severity of optic nerve damage and the associated risk factors for glaucomatous neuropathy.

### 4. STATISTICAL ANALYSIS

Chi-square analysis for 2x2 tables and Anova test were used for comparative analysis of preoperative demographic characteristics, postoperative complications, success rates in surgeries augmented with intraoperative antimetabolites or not. Unpaired sample two-tailed *t*-tests were used to compare the pre and postoperative IOP measurements. Statistical analy-

sis was performed using StatView program (Version 4.5 for Macintosh, Abacus Concepts). A *p*-value of less than 0.05 was considered statistically significant.

## RESULTS

The mean age of patients ( $\pm$  SD) was 62.3  $\pm$  16.4 years in the mTRAB group and 71.9  $\pm$  9.1 years in the NPDS group ( $p < 0.05$ ).

Comparative analysis of patient's demographics and risk factors for failure for surgery between the two procedures showed that there were no significant difference in terms of sex, type of glaucoma, preoperative IOP, numbers of previous filtering procedures or laser treatments as well as numbers and durations of prior topical medications ( $p > 0.05$ ) between eyes undergoing mTRAB and NPDS (chi-square  $p$ -value  $> 0.05$ ). The NPDS group has included significantly older patients as well as more numerous pseudophakic eyes than the mTRAB group ( $p < 0.05$ ).

The mean preoperative visual acuity ( $\pm$  SD) was significantly higher in the trabeculectomy group (0.8  $\pm$  0.3) than in the NPDS group (0.6  $\pm$  0.3) ( $p < 0.05$ ).

Table 2 summarizes the demographics of the two surgical groups.

The mean follow-up time was respectively 8.5  $\pm$  3.4 months (range: 5 to 12 months) in the mTRAB group and 10.7  $\pm$  5.5 months (range: 3 to 20 months) in the NPDS one's ( $p < 0.05$ ).

### 1. Perioperative complications

Perioperatively, procedures were uncomplicated in 37 out of the 43 trabeculectomies (86 %) and 20 out of the 22 NPDS (90.1 %). A microhyphema had occurred in 4 eyes (9.3%) in the mTRAB group and in one eye (4.5%) in the NPDS cohort. Except for 2 eyes (4.7%) in the mTRAB having exhibited a shallow anterior chamber at the end of the procedure, anterior chamber was kept deep during the whole course of both surgeries.

### 2. 1<sup>st</sup> month postoperative complications

For the whole sample and all complications included, 1<sup>st</sup> month postoperative complications

Table 2. Patient characteristics

	MTRAB (n=43)	NPDS (n=22)	p value
<i>Mean age</i> (mean years $\pm$ SD)	62.3 $\pm$ 16.6	71.9 $\pm$ 9.7	< 0.05
Sex	20 F/ 16 M	14 F/ 5 M	NS
<b>Race</b>			
Caucasian	34 patients	19 patients	
African	2 patients	0	
<i>Diagnosis</i>		(n = eyes)	NS
POAG	28	20	
OHT	3	1	
PCAG	4	0	
PXG	3	1	
Secondary glaucoma	3	0	
Congenital glaucoma	2	0	
<i>Pseudophakic/aphakic</i>	3	11	< 0.05
<i>Previous Filtering procedure</i>	15/65 eyes (23.1%)		NS
Trabeculectomy x1	7	3	
Trabeculectomy x2	1	0	
NPDS x1	2	0	
Phacotrabeculectomy	0	1	
Phacoextraction + NPDS	1	0	
<i>Previous laser treatments</i>	15	7	NS
<i>Preoperative medications</i> (mean number $\pm$ SD)	2.6 $\pm$ 0.7	2.8 $\pm$ 1.4	NS
<i>Duration of medication</i> (mean number of months $\pm$ SD)	115 $\pm$ 81	132 $\pm$ 86	NS
<i>Preoperative visual acuity</i>	0.8 $\pm$ 0.3	0.6 $\pm$ 0.3	< 0.05
<b>Visual field defect</b> (SAP HFA) (30 and 10-2 Sita Standard)			
No	4	1	
Mild (MD < -6 dB)	8	3	
Moderate (-12 dB > MD > -6dB)	7	3	
Severe (MD > -12 dB)	24 (56%)	15 (68%)	

were observed in 43 out of the 65 eyes (66.2 %). These concerned 26 out of the 43 (60.4%) and 17 out of the 22 (77.2 %) respectively of the mTRAB and the NPDS surgeries ( $p > 0.05$ ). Most of them were minor and transient. Post-operative early anterior chamber inflammation was mild to moderate in all cases. The frequency of distribution of hyphema, of transient conjunctival wound leaks (positive Seidel test), hyperfiltration related shallow anterior chamber (grade I: peripheral iris-cornea contact) associated with peripheral choroidal detachment or not, was comparable between the two groups ( $p > 0.05$ ). In both groups, wound leaks were mild, had a 4 days maximum duration and were resolved by one suture with 10-0 Biosorb® (Alcon®) and/or the application of a 20.50 mm Megasoft contact lens (Procornea®).

Excessive fibrosis of the filtration bleb was observed in 8/43 eyes (19%) in the mTRAB group and 8/22 (36%) in the NPDS group. 5-FU injections were performed in 8 out of the 43 (18.6%) mTRAB procedures versus 9 out of the 22 (41%) NPDS ones ( $p = 0.05$ ). The mean number of 5-FU injections ( $\pm$  SD) was 6.4 $\pm$ 2.4 and 5.3 $\pm$ 1.2 respectively in the mTRAB group and NPDS group ( $p > 0.05$ ).

The frequency of distribution of the observed complications was comparable in the 2 groups, whether intraoperative antimetabolites were given or not ( $p > 0.05$ ). In the subgroup without preoperative antimetabolites, 10/18 eyes (55.6%) of the mTRAB group and 4/5 eyes (80%) of the NPDS group had developed post-operative complications. When intraoperative antimetabolites were given, complications had occurred in 64% (16/25 eyes) in the mTRAB

Table 3. 1<sup>st</sup> month postoperative complications.

	MTRAB (n=43)	NPDS (n=22)	p value
1. Mean follow-up (months ± SD)	8.5±3.4	10.7±5.5	<0.05
2. Perioperative complications			
Micro-hyphema	4 (9.3%)	1 (4.5%)	
Shallow anterior chamber (grade 1)	2 (4.7%)	0	
Reduced percolation through trabeculo- Desmets membrane	0	1	
3. First month post-operative complications			
None	40%	23%	
Hyphema	3	2	
Transient wound leaks	9 (21%)*	4 (18%)*	NS
Transient shallow chamber (grade 1) with choroidal detachment	6 (14%)*	3 (13.6%)*	
Excessive scar tissue	8 (19%)	8 (36%)	
5-FU injections	8 (18.6%)	9 (41%)	=0.05
Iris prolapse	0	1	

Table 4. Listing of 1<sup>st</sup> month postoperative complications observed in mTRAB and NPDS groups, according intraoperative application of antimetabolites was used or not.

	NO PEROP ANTIMETABOLITES			PEROP ANTIMETABOLITES		
	mTRAB	NPDS	X <sup>2</sup> p	mTRAB	NPDS	X <sup>2</sup> p
	n eyes			n eyes		
	(n=18)	(n=5)		(n=25)	(n=17)	
No complications	8 (44.4%)	1 (20%)	NS	9 (36%)	4 (23.5%)	NS
Leaking blebs (Seidel +)	3 (16.7%)	0		6 (24%)	4 (23.5%)	
Anterior chamber shallowing without/with choroidal detachment	3 (16.7%)	1 (20%)		3 (12%)	2 (11.8%)	
Hyphema	0	0		3 (12%)	2 (11.8%)	
Excessive scarring	4 (22.2%)	3 (60%)		4 (16%)	5 (29.4%)	
Post-YAG laser goniopuncture iris incarceration	-	0		-	1 (5.9%)	

group and 76.4% (13/17 eyes) in the NPDS group (Chi Square  $p > 0.05$ ).

Table 3 lists the 1<sup>st</sup> month postoperative complications. Table 4 details the different complications observed within the 1<sup>st</sup> postoperative month in the two groups, according intraoperative application of antimetabolites was used or not.

### 3. Late (medium-term) complications

Beyond the 1<sup>st</sup> postoperative month, hyperfiltration associated with a shallowing of the anterior chamber was observed at 3 months postoperatively in a 41 year-old woman with advanced chronic primary closed-angle glaucoma and having been performed trabeculectomy augmented with a 60 seconds duration in-

traoperative mitomycin C (0.1 mg/ml) application. This resolved at the 6-month visit. Blebitis was successfully treated in a 81 year-old high myopic woman following NPDS without perioperative antimetabolites.

Nd:Yag laser gonioperforations were performed in 17 out of the 22 (77.3%) NPDS procedures and were complicated by iris incarcerations in 3 eyes.

Surgical exploration of the filtration site was performed at 2 and 3 months postoperatively in 2 eyes and was successful in one case.

The morphologic characteristics of the filtration blebs were comparable in terms of frequency of distribution between the two surgeries. In the mTRAB group, 36 of the 43 (83.7%) filtration blebs appeared diffuse or slightly elevated and vascularized versus 63.6% of the NPDS eyes ( $p > 0.05$ ). Avascular blebs were



noticed in 7 eyes (16.2%) in the mTRAB group and 8 eyes (36.3%) in the NPDS group. At this stage of our study, avascular blebs were not related with the intraoperative application of Mitomycin C (chi-square p-value > 0.05).

The mean final visual acuity (SD) was not significantly altered compared to its preoperative level and was comparable between the two surgical procedures ( $0.8 \pm 0.$  and  $0.6 \pm 0.3$  respectively in the “modern” trabeculectomy group and the NPDS group ( $p > 0.05$ ).

From a mean preoperative value of  $24.8 \pm 8.3$  mm Hg in the mTRAB group and of  $25.1 \pm 6.5$  mmHg in the NPDS group, IOP was highly significantly reduced to  $13.4. \pm 4.3$  mm Hg in the mTRAB group and  $14.7 \pm 4.6$  mmHg in the NPDS cohort at the last visit, without any significant difference between the two procedures ( $p > 0.05$ ). This corresponded to a mean percentage of IOP reduction of 46% and 41% respectively in the mTRAB and the NPDS group comparatively with the preoperative IOP level. Graph 1 shows the mean IOP results in the two procedures, their standard deviation and the sample size at each time interval. It outlines that the mean IOP was significantly reduced and relatively stable for each procedure over the whole observation period.

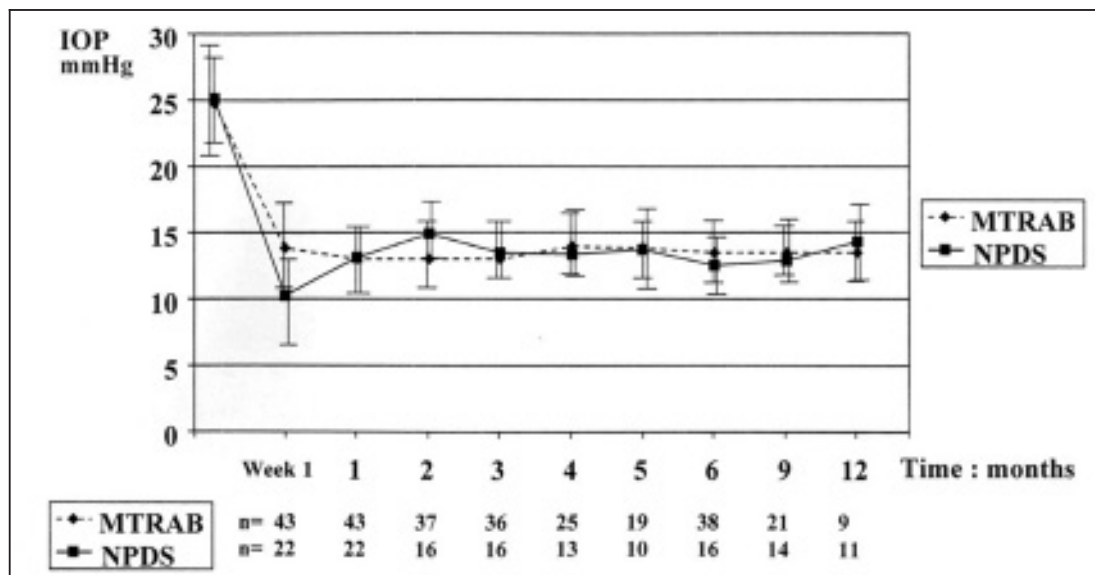
Independently of any intraoperative antimetabolite use, seventy per cent of the “modern” trabeculectomy procedures (30/43 eyes) achieved a final IOP of 15 mm Hg or less. This was significantly higher than in the NPDS group where 9 out of the 22 eyes (41%) had reached this target IOP ( $p < 0.05$ ).

The mean number of postoperative medications (SD) was significantly lower in the mTRAB ( $0.49 \pm 0.74$ ) as compared to the NPDS ( $0.96 \pm 1.1$ ) ( $p < 0.05$ ).

According to the predefined success criteria, 60 % (26/43 eyes) in the mTRAB group and 8/22 (36.4%) in the NPDS group presented with complete success at the last visit. Qualified success increased to 88% (38/43 eyes) in the mTRAB group and to 68.2% (15/22 eyes) in the NPDS group (chi-square p-value > 0.05).

## DISCUSSION

Since almost 30 years, non-penetrating trabecular surgery has been introduced with the aim of avoiding the potential complications associated with ocular entry. Following more recent modifications, it has been promoted as a serious alternative to trabeculectomy, mainly for its more attractive complication profile, particu-



Graph. 1: Mean IOP results (SD) with sample size at each time interval.

larly when cataract formation is considered (22). The results of most of the prospective randomised studies comparing trabeculectomy with non-penetrating deep sclerectomy or visco-canalostomy have suggested in an intermediate time period, such as 3-7 years, that the short-term gain of a lower rate of complications seen in non-penetrating trabecular procedures was at the expense of long-term benefit in the form of adequate IOP control (5-7 9, 12, 14, 15-17, 18, 19, 22, 24).

By focusing their research on the observation that high initial aqueous outflow can be deleterious after any filtration surgery, P. Khaw and co-workers had recently innovated trabeculectomy procedure, aiming at achieving safer long-term post-surgery outcomes with minimal complications (3, 10, 12, 20). In conjunction with advances allowing safer control of long-term healing processes, both titrations of preoperative IOP through anterior chamber continuous infusion and short-term postoperative IOP with step-by-step scleral flap suture release, have been a major advance in terms of the prevention of early hypotony.

Except for the age of patients and the number of pseudophakic eyes, our retrospective study included two well-matched groups in terms of risk for surgical failure. Preoperatively mTRAB and NPDS eyes were comparable with respect to previous filtering surgery and preoperative topical medications. Pseudophakic eyes were more numerous in the NPDS group than in the mTRAB group, whereas patients belonging to NPDS group were significantly older than in the other group. The better safety profile of NPDS compared to standard trabeculectomy in pseudophakic eyes, especially when the posterior capsule is no more intact and vitreous is present in the anterior chamber, could explain the difference in the sample of the pseudophakic eyes between the two groups.

Maintaining the intraocular pressure (IOP) in the low teens had been shown to be required to prevent or minimize glaucoma progression in patients with advanced glaucomatous damage (1, 8). When a filtering surgery is necessary in glaucomatous patients with severe glaucomatous damage, intraoperative application of antimetabolites is a standard practice to reach very low target IOP (8). Intraoperatively we had applied antimetabolites in eyes with previous

filtering surgery history and/or suffering from severe visual field defects. The use of an intraoperative low dose antimetabolite consisting in Mitomycin C in the majority of the eyes, had concerned a high percentage of our series (58% in the mTRAB group and 77% in the NPDS group), but it was statistically comparable in the two surgical procedures.

Our experience dealing with "modern" trabeculectomy suggests in priority that the safety of this improved technique is comparable and even more, slightly higher than those with NPDS, whether antimetabolites have been applied or not.

The incidence of 1<sup>st</sup> month postoperative complications such as wound leaks (21% in the mTRAB group and 18% in the NPDS group) and hyperfiltration related complications (14% and 13.6% respectively in the mTRAB and NPDS group) were comparable between the two procedures. All of them were minor and transient. Moreover intraoperative antimetabolite application was not associated with an increased rate of postoperative hyperfiltration related complications.

Late complications were not observed in the mTRAB group whereas iris prolapse occurred in 3 out of the 22 NPDS procedures (13.6%).

Interestingly the incidence of scarring complications of the filtration blebs had concerned a lower percentage of mTRAB eyes (19%) than the NPDS (36%). Anyway the postoperative need for 5-FU injections was less -although not significantly- frequent, in the mTRAB than in the other group (18.6% in mTRAB versus 41% in NPDS).

Considering the current 77% incidence of Nd:YAG laser goniopuncture in the NPDS eyes (converting eyes to a fully penetrating technique) and the significantly longer follow-up in this group (mean 10.7 months versus 8.5 months in mTRAB), comparable IOP reduction was obtained in the two procedures. In both groups, the mean IOP was significantly reduced from its preoperative values (46% in the mTRAB group versus 41% in the NPDS group) and relatively stable for each procedure throughout the follow-up of the study. Moreover 70% of the mTRAB reached a final IOP equal or less than 15 mm Hg. This was significantly higher than the 41% rate observed in the NPDS cohort.

Adjunctive topical medications could be significantly reduced in the mTRAB group, even more than in the NPDS group ( $p < 0.05$ ).

Whereas the frequency of distribution of the final success did not significantly differ between the two procedures, the complete and qualified success rates were comparable to slightly higher in the mTRAB group than in the NPDS cohort: 60% and 88% in mTRAB versus 36.4% and 68.2% in NPDS.

Even also important, by doing this technique and whether using intra- and postoperative antimetabolites or not, filtration bleb morphology was safe and consistent with the maintenance of an excellent ocular comfort in a large majority of the patients, in both procedures. Both fornix-based conjunctival flap and strictly posterior application of intraoperative antimetabolites when needed, are crucial to promote diffuse, mildly vascularized filtration and to reduce the incidence of avascular cystic high risk filtration blebs (20,23). However our follow-up is still too short to confirm that the current characteristics of the filtration blebs, specially in the subgroup augmented with Mitomycin C, will be stable and concomitantly associated with a reduced incidence of endophthalmitis. Although we have delivered Mitomycin C perioperatively with the lowest dose and during a shorter time of exposure than usually done in the literature, potential long-term complications associated with intraoperative use of Mitomycin should warn of the potential dangers of routinely using antimetabolites during surgery (8, 21, 23).

Modern trabeculectomy has some other potential advantages. It requires a shorter learning curve than deep sclerectomy, as being suggested in our experience. Owing to the good watertightness of the sutures and the maintenance of the anterior chamber depth both pre- and postoperatively, modern trabeculectomy, like deep sclerectomy, can be performed in one-day surgery.

In our experience, visual recovery was similar between the two surgical groups. However, considering our still limited follow-up, our findings do not allow us to conclude that mTRAB is associated with a reduced incidence of postoperative cataract formation owing to its less invasive nature, specially compared with standard Cairn's trabeculectomy.

Again we are aware that our study is biased and limited by its retrospective nature and the small and heterogeneous sample size.

## CONCLUSION

This study allows us to conclude as a priority that revisited trabeculectomy is associated with a safety profile (especially concerning hyperfiltration related complications) similar to those of non-penetrating drainage glaucoma surgery whether procedures are augmented with intraoperative antimetabolite or not. All the observed complications were transient and not sight threatening.

Out of the limelight and owing to the limitations of this study, our results suggest that "modern" trabeculectomy is associated with a slightly more important, although not statistically significant, IOP reduction and a higher success rate than deep sclerectomy. It is associated with final IOP's of 15 mm Hg or less in a significantly higher percentage than deep sclerectomy. Reflected by a significantly fewer number of postoperative 5-FU injections, it possibly induces less postoperative subconjunctival fibrosis. Postoperative topical medications can be more significantly alleviated with modern trabeculectomy compared with deep sclerectomy. Insofar as "modern" trabeculectomy will confirm to achieve both minimal complications and satisfactory control of IOP, it can be reasonably assumed that this revisited approach becomes the "master" filtering procedure of choice for the management of glaucoma in the future.

## REFERENCES

- (1) THE AGIS INVESTIGATORS – The advanced glaucoma intervention study (AGIS):7. The relationship between control of intraocular pressure and visual field deterioration. *Am J Ophthalmol* 2000;130:429-440.
- (2) AMBRESIN A., SCHAARAWY T., MERMOUD A. – Deep sclerectomy with collagen implant in one eye compared with trabeculectomy in the other eye of the same patient. *J Glaucoma* 2002;11:214-220.
- (3) BATTERBURY M., WISHART P.K. – Is high initial aqueous outflow of benefit in trabeculectomy? *Eye* 1993;7:109-112

- (4) BORISUTH N.S., PHILIPS B., KRUPIN T. – The risk profile of glaucoma filtration surgery. *Curr Opin Ophthalmol* 1999;10:112-116.
- (5) CARASSA R.G. – Visco canalostomy. In: Weinreb R.N., Leibmann J.M., editors. *Glaucoma 1999: concepts and controversies*. American Academy of Ophthalmology, 1999:113-120.
- (6) CHISELITA D. – Non-penetrating deep sclerectomy versus trabeculectomy in primary open-angle glaucoma surgery. *Eye* 2001;15:197-201.
- (7) EL-SAYYAD F., HELAL M., EL-KHOLIFI H., KHALIL M., EL-MAGHRABI A. – Nonpenetrating deep sclerectomy versus trabeculectomy in bilateral primary open angle glaucoma. *Ophthalmology* 2000;107:1671-1674.
- (8) THE EUROPEAN GLAUCOMA SOCIETY. – Terminology and Guidelines for Glaucoma. (European Guidelines) Antimetabolites in glaucoma filtering surgery. 2<sup>nd</sup> Edition Savona, Italy, Editrice DOGMA, 2003, 3.7 (3-37).
- (9) GANDOLFI S.A.A., CIMINO L. – Deep sclerectomy without absorbable implants and with unsutured scleral flap :prospective: prospective, randomised 2-year clinical trial vs trabeculectomy with releasable sutures. *Invest Ophthalmol Vis Sci* 2000; 41:S83.
- (10) HITCHINGS R.A. – Trabeculectomy-The Golden Standard. *In Glaucoma Therapy. Current Issues and Controversies*. Eds T.Shaarawy and J.Flammer. Martin Dunitz.2004;18: 249-255.
- (11) JAMPEL H. – Target pressure in glaucoma therapy. *J Glaucoma* 1997;6:133-138
- (12) KHAW P.T.– In: “Glaucoma surgery”. By Lerner S.F. and Parrish II R.K. Edt Lippincott 1999; chap 3:15 (ISBN 0-19262998).
- (13) KHAW P.T, WELLS A.P. – Trabeculectomy in the UK: is there room for improvement? *Eye* 2001; 15: 437-438.
- (14) KOBAYASHI H., KOBAYASHI K., OKINAMI S. – A comparison of the intraocular pressure-lowering effect and safety of visco canalostomy and trabeculectomy with Mitomycin C in bilateral open-angle glaucoma. *Graefes Arch Clin Exp Ophthalmol* 2003;241:359-366.
- (15) LACHKAR Y., NEVERAUSKIENE J., JEANTEUR-LUNEL M.-N., GRACIES H, BERKANI M., ECOFFET M., KOPEL J., KRETZ G., LAVAT P., LEHRER M., VALTOT F., DEMAILLY P. – Nonpenetrating deep sclerectomy: a 6-year retrospective study. *Eur J Ophthalmol* 2004; 14:26-36.
- (16) LÜKE C., DIETLEN T.S., JACOBI P.C., KONEN W., KRIEGLSTEIN G.K. – A prospective randomized trial of visco canalostomy versus trabeculectomy in open-angle glaucoma: a 1-year follow-up study. *J Glaucoma* 2002; 11:294-299.
- (17) MERMOUD A., SSHNYDER C.C., SICKENBERG M., CHIOU A.G.Y., HEDIGUER S.E.A., FAGGIONI R. – Comparison of deep sclerectomy with collagen implant and trabeculectomy in open angle glaucoma. *J Cataract Refract Surg* 1999; 25:323-331.
- (18) NETLAND P.A. – Nonpenetrating glaucoma surgery. *Ophthalmology* 2001; 108:416-421.
- (19) O'BART D.P.S., ROWLAND E., ISLAM N., NOURY A.M.S. – A randomised, prospective study comparing trabeculectomy augmented with antimetabolites with a visco canalostomy technique for the management of open angle glaucoma uncontrolled by medical therapy. *Br J Ophthalmol* 2002; 86:748-754.
- (20) PAPADOPOULOS M., KHAW P.T. – Improving glaucoma filtering surgery. *Eye* 2001; 15:131-132.
- (21) SIRIWARDENA D., EDMUNDS B., WORMALD R.P.L., KHAW P.T. – National survey of antimetabolites use in glaucoma surgery in the United Kingdom. *Br J Ophthalmol* 2004; 88:873-876.
- (22) WEINREB N.R, CROWSTON J.G. – Reports and Consensus Statements of the 2<sup>nd</sup> Global AIGS Consensus Meeting on Glaucoma Surgery - Open Angle Glaucoma. Krugler Publications, The Hague, The Netherlands, ISBN 90 6299 203 X, 2005;135 pages.
- (23) WELLS A.P., CORDEIRO M.F., BUNCE C.V., KHAW P.T. – Cystic bleb related complications in limbal versus fornix based flaps in paediatric and young adult trabeculectomy with high dose mitomycin C. *Invest Ophthalmol* 2001; 42:2913-B55.
- (24) YALVAC I.S., SAHIN M., EKIOGLU U, MIDILLIOGLU I.K., ASLAN B.S., DUMAN S. – Primary visco canalostomy versus trabeculectomy for primary open-angle glaucoma: three year prospective randomized clinical trial. *J Cataract Refract Surg* 2004; 30:2050-2057.
- .....
- Correspondence and Reprints:
- Prof. Dr. M. DETRY-MOREL  
St Luc University Hospital  
Department of Ophthalmology  
Avenue Hippocrate, 10  
B-1200 BRUSSELS  
BELGIUM  
e-mail: detry@ofta.ucl.ac.be