
PHTHIRIASIS PALPEBRARUM: 2 CASE REPORTS

VANDEWEGHE K. *, ZEYEN P.**

SAMENVATTING

Phthiriasis palpebrarum, veroorzaakt door de phthirus pubis, is een zeldzame oorzaak van blefaroconjunctivitis, en wordt dan ook vaak over het hoofd gezien. We stellen 2 patiënten voor met jeuk en irritatie t.h.v. het rechter bovenooglid. Biomicroscopie toonde enkele luizen en neten verankerd t.h.v. de cilia. Bij dermatologisch onderzoek bleken talrijke luizen en neten aanwezig t.h.v. de romp en pubisstreek. De luizen en neten t.h.v. de cilia werden manueel verwijderd indien mogelijk, en aan de patiënten werd opgedragen dagelijks wat vaseline aan te brengen t.h.v. de ooglidranden. De patiënten werden ook behandeld met malathion 0.5% lotion. Bij controle na 2 weken waren geen luizen of neten meer aanwezig bij de eerste patiënt.

ABSTRACT

Phthiriasis palpebrarum, caused by the phthirus pubis, is a rare cause of blepharoconjunctivitis, and is therefore often neglected. We present 2 patients who suffered itching and irritation at the right upper eyelid.

Biomicroscopic examination showed a few lice and nits anchored to the eyelashes. Dermatologic examination revealed the presence of numerous lice and nits at the trunk and pubic area.

The lice and nits were manually removed if possible, and the patients were asked to put vaseline on the eyelid margins. The patients were also treated with malathion 0.5% lotion. After control, two weeks later, no more lice nor nits were present in the first patient.

.....

* Dept. of Ophthalmology, UZ Leuven, Leuven, Belgium.

** Dept. of Ophthalmology, AZ Middelheim, Antwerpen, Belgium.

received: 26.02.06

accepted: 08.04.06

RÉSUMÉ

La phtiriasse palpébrale, causée par le morpion, est une cause rare de blépharoconjunctivite, et est par conséquent souvent négligée.

Nous présentons deux patients qui se plaignaient de démangeaison et d'irritation au niveau de la paupière supérieure droite.

La biomicroscopie montrait quelques poux et oeufs, attachés aux cils.

Au cours d'un examen dermatologique, des poux et des oeufs étaient également trouvés sur le torse et dans la région pubienne.

Les poux et les oeufs sur les cils ont été enlevés manuellement si possible, et les patients ont dû appliquer chaque jour un peu de vaseline sur les bords des paupières. Les patients ont également été traités avec une lotion de malathion 0,5%. Deux semaines plus tard, le premier patient a été contrôlé et tous les poux et oeufs avaient disparu.

KEY WORDS

Phthiriasis palpebrarum, pubic lice, malathion, vaseline

MOTS-CLÉS

Phtiriasse palpébrale, poux, malathion, vaseline

CASE REPORTS:

CASE 1

A 44-year old man consulted for redness and small crusts on the upper eyelid since two weeks, followed by itching and irritation of the eyelid margin. He had no other complaints.

Biomicroscopic examination revealed an erythematous swelling of the upper eyelid margin with crusts. Two grey-white lice were anchored at the cilia (fig 1) and a few nits at the base of the cilia (fig 2). There was a conjunctival follicular reaction and discrete conjunctival injection.

Phthiriasis pubis was confirmed after microscopic examination.

The lice and nits were manually removed with a pair of tweezers. The patient was asked to put daily some vaseline ointment on the eyelids during two weeks. He was also sent to a dermatologist, who found numerous lice on the trunk and pubic region. The patient and his wife

both had to be treated with malathion 0,5% lotion on hairy places of the trunk and the limbs; this lotion was removed in the morning.

At the control examination, two weeks later, no more lice or nits were seen.

CASE 2

A 7-year old girl came to the emergency department suffering from constant itching on the right eyelid. This lasted for a week.

Biomicroscopic examination revealed the presence of 3 lice on the eyelashes and red-brown faeces of the lice on the eyelids. There was a discrete follicular conjunctival reaction.

This time it was not possible to remove the lice. Treatment was started with vaseline ointment twice a day on the cilia, during two weeks and a single application of malathion 0,5% lotion on the body for 12 hours. Dermatologic control and treatment of the parents was advised. The patient did not show up for control.

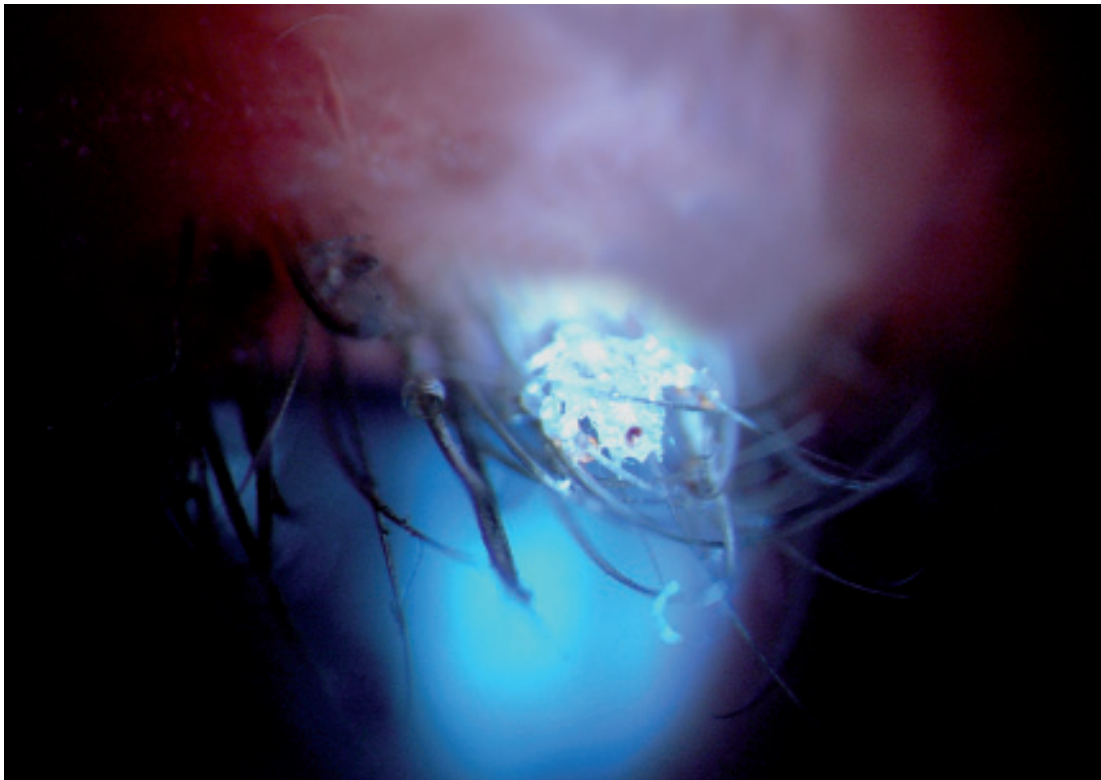


Fig 1. A grey-white louse, anchored at the cilia.

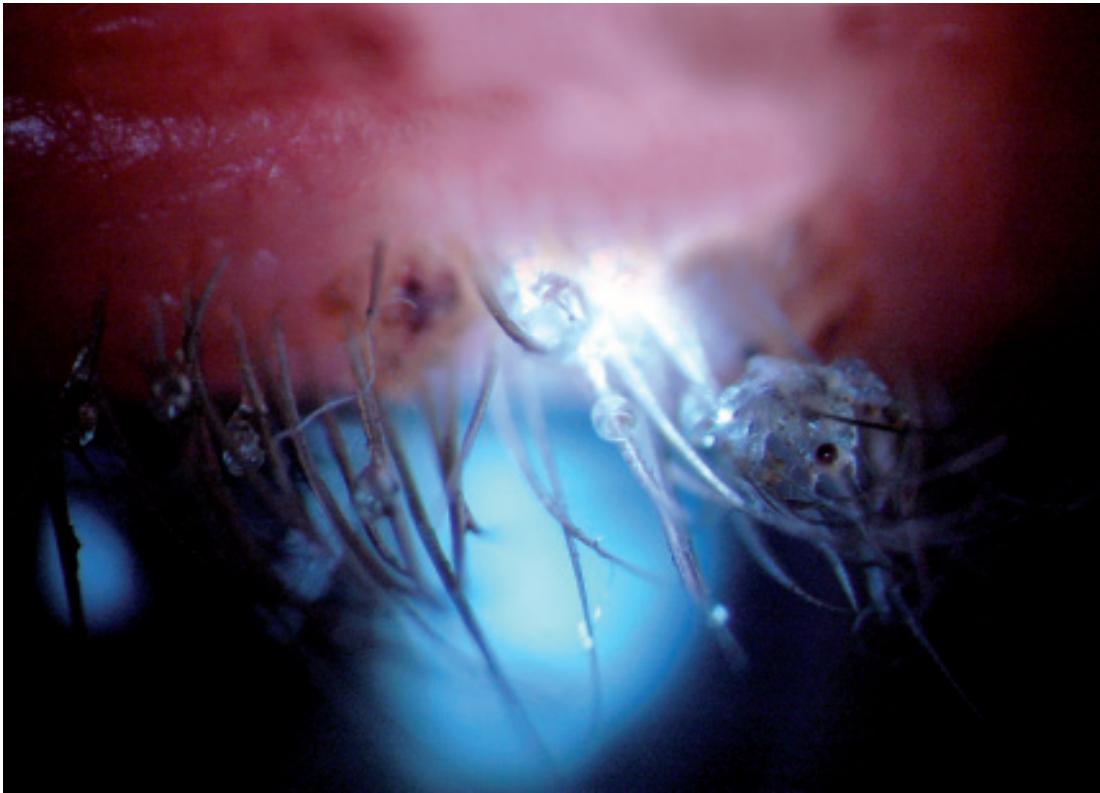


Fig 2. A few nits at the base of the cilia.

DISCUSSION

ETIOLOGY:

Phthiriasis palpebrarum is an infection of the eyelashes by phthirus pubis or crab louse.

Among humans, three kinds of lice can exist, all of them belonging to the anoplura or sucking louse. They are called so because they feed themselves with blood sucked from their hosts. These lice are host-specific which means that they only survive on humans and not on animals (2,8,11,12,17-19,28-30).

The pediculus capitis or head louse is especially found in schoolchildren and is spread by head to head contact.

The pediculus corporis or body louse is only found in people living in bad hygienic circumstances and belonging to a lower socio-economic background. The lice are found at the seams of their clothing and only pass on to the skin to feed themselves (19).

The phthirus pubis or crab louse typically appears on the level of the pubic hair. If numerous, they can also be found on the hair of armpit, breast, beard, moustache, eyelashes and eyebrows or, exceptionally, the head (1,2,5-8,12,15-17,19,21,24,25,29).

Phthiriasis pubis especially appears in cases of bad hygiene. It is mostly passed on by sexual contact or close physical contact but also by the common use of towels, bedlinnen and clothing (1,2,6,8,11,14-17,19,25,28-30).

Infestation with phthirus pubis mostly occurs among adults (7,16,25,28). Transmission to the adult eye lashes is caused by the hand, after touching the genital region.

In rare cases, a child could also be infected after close physical contact between family members. The infection could also reveal sexual abuse (1,8,11,14,16,17,19,25,29,30). Via PCR, the host DNA can be identified through the blood-meal of the louse. This can provide useful information in case of sexual abuse (8,11,17,20).

Children mostly have crab lice on the eyelashes and eyebrows, as they do not have armpit hair or pubic hair (1,6,7,11,19,21,29).

The crab louse resembles a crab, with a broad body, two short front paws and four broad hind legs with little claws (2,11,12,14,17,19,29). Sometimes it is possible to perceive dark pigmented digestive material near the abdomen (2,19).

The crab louse is, in contrast with its pediculus relatives, rather sedentary (2,19,28). It can not jump or fly, but it is able to walk at the rate of up to 10 cm a day (5,14,17,18). It is smaller (1-2mm) and rounder than its pediculus relatives, namely the head louse (2mm) and the body louse (2-4mm) (2,14,17-19,21,28,30). The predilection of the pubic lice for the pubic hair region is related to a lower density of hairs in that region. The space between the hairs is similar to the span of the hind legs of the crab louse, that moves by catching hold of its 4 hind legs to 2 neighbouring hairs (1,6,14,17,19,28).

After impregnation, a female louse lays about 3 eggs a day, strongly attached to the hairbase. Together with the eggs, the mother louse produces a kind of fast drying glue that is smeared around the egg and the hair. When the glue has dried up, a solid covering is made around the egg as well around the hair shaft. These coverings are the so-called nits, and have a lid or operculum at the end, through which the larva can breathe and can break out when it is full-grown. The nits appear as oval, white or dark little pearls and are attached to the basis of the cilia, near the skin where they find the right temperature to incubate (2,8,15,17-19,21,23,24,30). They are often very hard to remove. After 5 to 10 days, a nymph comes out of each egg. During the next 7 to 10 days, it runs through 3 nymphstadia before the louse develops itself into the adult shape (2,5,6,8,11,14,16-19,21). An adult louse lives for about a month. Without a host, on the other hand, it can not survive longer than one day (2,8,17,19,30).

CLINIC

An infestation with phthirus pubis can be asymptomatic in the beginning, although it of-

ten causes itching and a chronic irritation (2,6,8,11,12,14,15,18,19,25,29,30). The louse bites to feed itself with blood. At that moment it injects a small amount of saliva so that the blood clots more slowly. The itching is caused by an immunologic reaction to the saliva, and mostly appears a few days after contamination (18,19).

Scratching can cause a bacterial surinfection or eczema (1,2,8,12,18,19,25). Sometimes, small blue-grey spots (maculae caeruleae) are visible where the louse has bitten (deep dermal hemosiderine) or the red-brown faeces of lice are visible (17,19,25,28,29). Biomicroscopic examination often makes lice and nits visible at the eyelashes (1,2,6-9,11,14,16,17,21,24,25,28-30).

A final diagnosis can be made by microscopic examination of the removed lice (7,25,29).

An infestation often causes blepharitis, follicular conjunctivitis and in extreme cases marginal keratitis. Surinfection of the bites can cause preauricular lymphadenopathy (1,2,6,7,9,16,17,19,24,28,30).

Head lice and body lice cause ocular contamination even more infrequently, and then it is mostly a manifest contamination of the scalp (2,19,28-30).

TREATMENT

1. *near the cilia:*

The immediate treatment of phthiriasis palpebrarum consists of removing the lice and nits manually with tweezers, although this is sometimes difficult in children and patients who are not very cooperative. In this case, anaesthesia and sedation can be used (2,6,7,9,14,15,21,24,27-30).

If a complete mechanical removal is impossible, the patient could be treated with vaseline, twice a day during two weeks. The ointment chokes the lice and emerging nits (6-8,11,13,17-19,21,24,28,29). However, the ointment is not ovicide so that the treatment must be continued for 2 weeks.

In medical literature, other pediculocide regimens are described:

- yellow mercuric oxide 1% ointment (2,6,7,9,14-17,19,21,24,28-30),

- fluorescein 20% watery solution (6,7,11,17,19,21,22,29),
- 3% ammonium mercuric oxide (16,28),
- anticholinesterase agents (0,25% physostigmine ointment) (2,6,9,14,15,16,19,21,24,29).

Phthiriasis palpebrarum can also be treated with argon lasertherapy (beam magnitude 200 micron, 0.1sec.,200mW) or with cryotherapy. There is a rapid recovery and fewer controls are necessary. Yet, these methods are of little use for non-cooperative patients or for primary treatment (2,3,6,7,14,15,19,21,24,28-30).

2. skin treatment:

As the lice are spread all over the body, and in order to prevent reinfection, an examination and treatment of all hairy parts are necessary (1,2,6,8,18,19).

There are many treatment regimens, although there is no clear consensus on the best product for eradication (8,18,19).

When choosing a pediculocide it is important to consider the kind of insecticide, the concentration, the vehicle and the duration of application (16,18).

In Belgium the following insecticides are available:

- malathion
- permethrine
- pyrethroids (such as depallethrine)

Each brand has its own concentration. On top of this, several vehicles are available, such as shampoos, ointments, lotions and sprays (18,19).

It is advisable to use lotions because of the higher concentration of insecticides, the single application and the better penetration, but one should avoid eye contact (8,17,18,27). The use of sprays is discouraged for asthmatic patients or patients with breathing difficulties (8,18).

A safe and effective product is malathion 0,5% lotion (Prioderm lotion®, Radikal lotion®). This product must be applied once on dry hair and washed off after 12 hours (6-8,10-14,17-19,23,24,31).

It is an irreversible cholinesterase inhibitor that causes a respiratory paralysis of the louse.

Malathion is an insecticide as well as an ovicide and kills almost 100% of the lice and nits.

This lotion, however, is inflammable so that any sort of heat in the immediate neighbourhood should be avoided (e.g. hairdryer, cigarettes, boiler etc) (17,18).

Another possibility is a single application of permethrine 1% (Nix lotion®, Zalvor cream®) during 10 minutes. This product also kills the louse by respiratory paralysis. It is almost 100% pediculocide and 20 to 70% ovicide (5,6,8,11-14,17-19,30,31).

Depallethrine 0,66% and piperonylbutoxide 2,64% (Para spray®) in combination with a duration of application of 30 minutes could be 45 to 100% pediculocide and 20 to 70% ovicide, but it is also inflammable (18,31).

The use of lindane 1% is forbidden in Belgium because it is neurotoxic and can cause aplastic anaemia (8,11,13,17,19,28-30).

Lice could become resistant to these products (8,10,17-19). However, correct data on resistance patterns are unknown for Belgium.

3. Systemic oral treatment:

In the medical literature, a few systemic treatments of phthiriasis palpebrarum are mentioned, such as ivermectine (4-6,8,11,13,17-19) or cotrimoxazole (5,13,17,18). Their advantage is easiness in use, and the systemic protection. However, these products have serious side effects (5,18). Large scale randomized studies are missing, so the use of these products is discouraged in Belgium.

4. Supplementary measures:

As no treatment is 100% ovicide it is advisable to check after 7 days whether the treatment has been succesful. By that time, the living larvae have come out of the nits.

If nymphes or lice are still found, the treatment is regarded as unsuccessful. In that case a renewed treatment with the same product is necessary. If after the next seven days the situation of the patient is still infected, it is appropriate to switch to another skin treatment (8,18,28).

As the lice are often transmitted via sexual contact and the use of a condom is ineffective, all recent partners should be examined and, if positive, they should all be treated simultaneously (1,2,5,7-9,11,13,15-19,28,30).

It is appropriate to screen for other sexually transmittable diseases such as HIV, syphilis, gonorrhea, chlamydia, herpes genitalis and trichomonas. Up to 30% of the patients suffering from crablice have also another venereal disease (13,17).

Delousing clothes and bedlinen is appropriate in order to avoid reinfection. (2,8,9,11,13,15,17,18,26,28,30). Sheets should be washed warm (during 30 minutes at 50 °C), dried warm (70 °C) and ironed. Lice do not survive these temperatures. Blankets that are difficult to wash can be deloused by putting them separately in a plastic bag for two weeks so that the lice and nits die from lack of food.

CONCLUSION

Phthiriasis palpebrarum is an unusual cause of blepharoconjunctivitis.

On biomicroscopic examination, the lice and nits are visible at the cilia.

Transmission mostly occurs by sexual contact. The topical treatment on the cilia consists of manual removal of the lice and nits and of application of vaseline twice a day during two weeks. As the lice are mostly spread over the whole body, dermatologic examination and treatment of all infected parts of the body are necessary.

REFERENCES

- (1) ALEXANDER J.O. – Phthirus pubis infestation of the eyelashes. *JAMA* 1983; 250: 32-33.
- (2) ASHKENAZI I., DESATNIK H.R., ABRAHAM F.A. – Yellow mercuric oxide, a treatment of choice for phthiriasis palpebrarum. *Br J Ophthalmol* 1991; 75: 356-358.
- (3) AWAN K.J. – Argon laser phototherapy of phthiriasis palpebrarum. *Ophthalmic Surg* 1986; 17:813-814.
- (4) BARKWELL R., SHIELDS S. – Deaths associated with ivermectin treatment of scabies. *Lancet* 1997; 349: 1144-1145.
- (5) BURCKHART C.G., BURCKHART C.N. – Oral ivermectin for phthirus pubis. *J Am Acad Dermatol* 2004; 51: 1037-1038.
- (6) BURCKHART C.N., BURCKHART C.G. – Oral ivermectin therapy for phthiriasis palpebrarum. *Arch Ophthalmol* 2000; 118:134-135.
- (7) CHARFI F., ZINA Z.B., MAAZOUN M., KHARRAT W., SELLAMI D., MAKNI F., AYADI A., FEKI J. – Phthiriasis ciliaire de l'enfant. Diagnostic et traitement. *J Fr Ophtalmol* 2005; 28: 765-768.
- (8) CHOSIDOW O. – Scabies and pediculosis. *Lancet* 2000; 355: 819-826.
- (9) COUCH J.M., GREEN W.R., HIRST L.W., DE LA CRUZ Z.C. – Diagnosing and treating phthirus pubis palpebrarum. *Surv Ophthalmol* 1982; 26: 219-225.
- (10) DOWNS A.M., STAFFORD K.A., HARVEY I., COLES C.G. – Evidence for double resistance to permethrin and malathion in head lice. *Br J Dermatol* 1999; 41:508-511.
- (11) ELSTON D.M. – Lice. 2005 www.emedicine.com
- (12) GAWKRODGER D.J. – *Dermatology, an illustrated colour text*. Edinburgh: Churchill Livingstone 1998: 58-59.
- (13) HIPOLITO R.B., MALLORCA F.G., ZUNIGAMACARAIG Z.O., APOLINARIO P.C., WHEELER-SHERMAN J. – Head lice infestation: single drug versus combination therapy with one percent permethrin and trimethoprim/sulfamethoxazole. *Pediatrics* 2001; 107:1-5.
- (14) IKEDA N., NOMOTO H., HAYASAKA S., NAGAKI Y. – Phthirus pubis infestation of the eyelashes and scalp hairs in a girl. *Pediatr Dermatol* 2003; 20:356.
- (15) KANSKI J.J. – *Clinical Ophthalmology, a systematic approach*. Edinburgh: Butterworth Heinemann, 2003: 5.
- (16) KINCAID M.C. – Phthirus pubis infestation of the lashes. *JAMA* 1983; 249:590.
- (17) KO C.J., ELSTON D.M. – Pediculosis. *J Am Acad Dermatol* 2004; 50:1-12.
- (18) LAPEERE H., VANDER STICHELE R.H. – De aanpak van hoofdluizen. Dec 2003. www.wvcv/laanderen.be
- (19) LOPEZ G.J., GARCIA L.I., MARTINEZ G.J. – Phthiriasis palpebrarum: diagnosis and treatment. *Arch Soc Esp Oftalmol* 2003; 78:365-374.
- (20) LORD W.D., DIZINNO J.A., WILSON M.R., BUDOWLE B., TAPLIN D., MEINKING T.L. – Isolation, amplification and sequencing of human mitochondrial DNA obtained from human crab louse, phthirus pubis, blood meals. *J Forensic Sci* 1998; 43: 1097-1100.

- (21) MANSOUR A.M. – Photo essay: phthiriasis palpebrarum. Arch Ophthalmol 2000; 118:1458-1459.
- (22) MATHEW M., D'SOUZA P, MEHTA D.K. – A new treatment of phthiriasis palpebrarum. Ann Ophthalmol 1982; 14: 439-441.
- (23) POLLACK R.J., KISZWESKI A.E, SPIELMAN A. – Overdiagnosis and consequent mismanagement of head louse infestations in North America. Pediatr Infect Dis J 2000; 19:689-93.
- (24) RUNDLE P.A., HUGHES D.S. – Phthirus pubis infestation of the eyelids. Br J Ophthalmol 1993; 77:815-816.
- (25) SIGNORE R.J., LOVE J., BOUCREE M.C. – Scalp infestation with phthirus pubis. Arch Dermatol 1989; 125: 133-134.
- (26) SPEARE R., CAHILL C., THOMAS G. – Head lice on pillows, and strategies to make a small risk even less. Int J Dermatol 2003; 42:626-29.
- (27) SPEARE R., KOEHLER J.M. – A case of pubic lice resistant to pyrethrins. Aust Fam Physician 2001; 30: 572-4.
- (28) TAYLOR H.R., VAJAYEE R.B. – Pediculosis and phthiriasis. In: Easty DL, Sparrow JM. Oxford Textbook of Ophthalmology. Oxford: Oxford University Press 1999: 971-973.
- (29) THAPPA D.M., KARTHIKEYAN K., JEEVAN-KUMAR B. – Phthiriasis palpebrarum. Postgrad Med J 2003; 79:102.
- (30) TUROW V.D. – Phthiriasis palpebrarum: an unusual course of blepharitis. Arch Pediatr Adolesc Med 1995;149: 704-705.
- (31) VANDER STICHELE R.H., DEZEURE E.M., BOGAERT M. – Systematic review of clinical efficacy of topical treatments for head lice. BMJ 1995; 311:604-608.

Thanks to dr Blanckaert J., Dept. of Ophthalmology, UZ Leuven, for the biomicroscopic pictures.

.....

Correspondence and reprints:

*K VANDEWEGHE
Dept. of Ophthalmology
AZ Middelheim
Lindendreef 1
B-2020 ANTWERPEN
Belgium
Email: katrienweg@yahoo.co.uk*