

---

# CONFOCAL MICROSCOPY IN MULTIPLE MYELOMA ASSOCIATED CRYSTALLINE KERATOPATHY: CASE REPORT

Houben N.<sup>o</sup>, Foets B.<sup>o</sup>

---

## SUMMARY

We report on the confocal microscopical findings of both corneas of a patient presenting a multiple myeloma associated crystalline keratopathy and the response to treatment. Blurred vision was the first sign of progression of the multiple myeloma. Confocal microscopy images show needle-like structures in the epithelium and stroma of the cornea which regressed after treatment of the multiple myeloma.

## RÉSUMÉ

Nous rapportons le cas d'une patiente présentant une kératopathie cristalline objectivée au microscope confocal et associée à un myélome multiple, avant et après traitement. Une diminution de l'acuité visuelle était le premier signe de la progression de la maladie systémique. Les images par microscopie confocale montrent des structures aciculaires dans l'épithélium et le stroma de la cornée et présentent une nette régression après traitement de la maladie.

## SAMENVATTING

We bespreken de resultaten van het confocaal microscopisch onderzoek van de cornea's van een patiente met multipel myeloom en geassocieerde kristallijne keratopathie voor en na behandeling. Visusdaling was het eerste teken van progressie van het multipel myeloom. De confocale microscopie toont

naaldvormige kristallen in het epitheel en stroma van de cornea en een afname hiervan na algemene behandeling en regressie van de ziekte.

## KEY WORDS

Corneal crystals-Confocal microscopy-Multiple myeloma

## MOTS-CLÉS

Cristaux cornéens-Microscopie confocale-Myélome multiple

.....

<sup>o</sup> University Hospitals Leuven, Department of Ophthalmology

received: 03.02.06

accepted: 21.03.06

## INTRODUCTION

Multiple myeloma is a plasma cell dyscrasia due to an abnormal proliferation of B lymphocytes which are responsible for an abnormal production of a monoclonal immunoglobulin, most frequently IgG, but also IgA, IgE or IgD (2). In our case IgG was found highly increased. Immunoglobulin deposition may occur in the cornea (5,9,10) and cause a crystalline keratopathy (1,3,7,9) or vortex keratopathy (6) with visual impairment as a result.

Confocal microscopy enables high-magnification in vivo examination of the cornea and can be very useful to better identify and localize pathological structures in the cornea (3).

## CASE REPORT

We examined a 56-year-old woman complaining of blurred vision since 4 months. Best-corrected visual acuity was still 0.9 in both eyes. Her medical history was particular for multiple myeloma stage 1a. Slitlamp examination showed


numerous refringent white dots scattered throughout all layers of the cornea and a pigmented line centrally over the cornea (Fig. 1). The remainder of the ocular examination was normal. We referred the patient to the hematologist and a progression of her multiple myeloma to stage 2a was diagnosed. The patient received chemotherapy and a stemcell transplantation. After treatment of the general disease there was a normalisation of the IgG concentration. Her vision gradually improved.

## MATERIAL AND METHODS

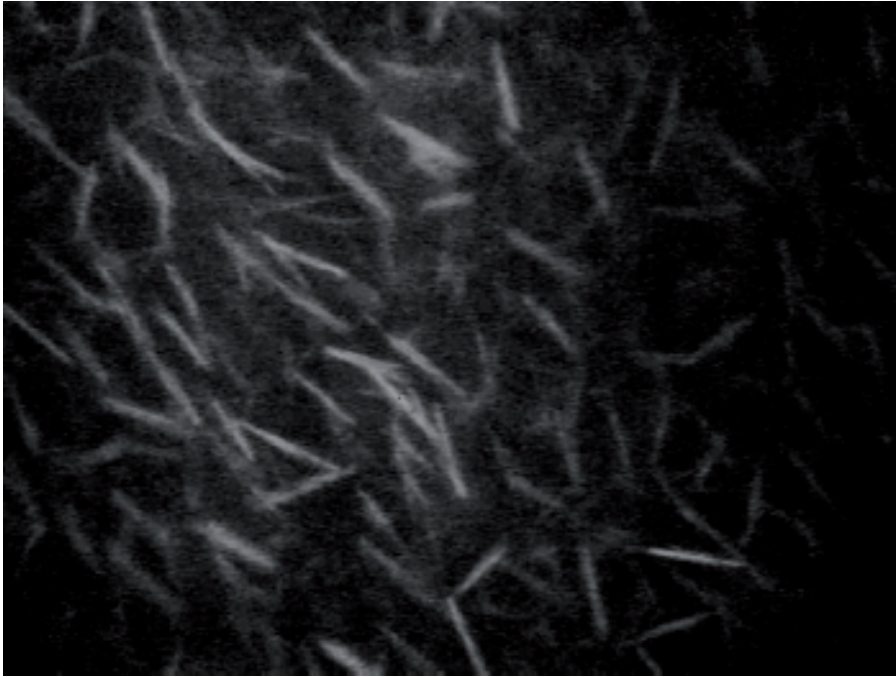
The Confo Commander Tomey Version V20 was used to obtain corneal images before and after treatment of the disease.

## RESULTS


Confocal microscopy images showed numerous hyperreflective needle-like structures ran-



*Fig. 1* Slitlamp photograph showing corneal crystals.



*Fig. 2* Confoscan image showing hyperreflective needle-like structures in the anterior stroma of the cornea before treatment of the multiple myeloma.



*Fig. 3* Confoscan image at the level of the corneal stroma showing regression of corneal crystals after treatment of the multiple myeloma.

domly distributed in the corneal epithelium and stroma (Fig. 2). Four months after treatment confocal microscopy images show an obvious decrease in number of the crystals (Fig. 3).

## DISCUSSION

Multiple myeloma associated crystalline keratopathy has first been described in 1958 by Burki (4) and is a rare condition. Corneal crystals are seen in only in 1% of the patients (2) with a monoclonal gammopathy. The rarity of such corneal changes is related to two conditions (13) : a gammopathy of IgG kappa light chain must be present and the disease must be chronic. Characteristics of the paraproteins, such as solubility, isoelectric point, susceptibility to proteolysis and other unknown properties, also play a part. Klintworth (9) demonstrated immunohistochemically that the corneal deposits correspond to the monoclonal protein produced by the plasmacell.

The precise etiology of corneal immunoglobulin deposition is not known. Klintworth (9) suggested a spontaneous crystallisation as the cause of the corneal deposits. Barr (1) found intracellular inclusions and proposed an abnormal production by the keratocytes, while Cherry (5) and Steuhl (13) found a double membrane around the intracellular particles and believed phagocytosis by the keratocytes was the cause. Hurley (8) found the crystals to be extracellularly located. Rodrigues (12) proposed a supply of crystals by the limbal vessels.

These crystals can have numerous morphologies. They have been described on specular microscopy as stick-like structures with rounded edges, irregularly arranged in the corneal stroma (6,8,10) while on histopathologic examination they correspond to rectangular or rhomboidal crystalline deposits (11). They have also been described as trapezoidal, pentagonal and hexagonal (7).

In contrast to the globular type of deposits described as by Buerk (3) we found the corneal depositions to be needle-like hyperreflective structures distributed randomly throughout the epithelium and stroma of the cornea (Fig. 2).

To our knowledge this is the first time this needle-like shaped type of corneal crystals has been documented by the confoscan in multiple myeloma. Moreover we documented a decrease in the number of these crystals after systemic treatment of the disease (Fig. 3). In accordance, an obvious regression of the crystals was observed on slitlamp examination and visual acuity improved subjectively.

## CONCLUSIONS

In our patient blurred vision was the first sign of progression of a systemic multiple myeloma from stage 1a to stage 2a.

Needle-like crystals in the cornea were documented by confoscan.

There was a marked decrease in number of crystals in the cornea after treatment of the multiple myeloma.

The confoscan is a useful tool to monitor the disease before and after treatment.

## REFERENCES

- (1) BARR C.C., GELENDER H., FONT R.L. – Corneal crystalline deposits associated with dysproteinemia. *Arch Ophthalmol* 1980; 98: 884-889.
- (2) BOURNE W.M., KYLE R.A., BRUBAKER R.F., GREIPP P.R. – Incidence of corneal crystals in the monoclonal gammopathies. *Am J Ophthalmol* 1989; 107: 192-193.
- (3) BUERK B.C., TU E. – Confocal microscopy in multiple myeloma crystalline keratopathy. *Cornea* 2002; 21: 619-620.
- (4) BURKI E. – Über Hornhautveränderungen bei einem Fall von multiplem Myelom(Plasmocytom). *Ophthalmologica* 1958; 135: 565-572.
- (5) CHERRY P.M.H., KRAFT S., MCGOWAN H., GHOSH M., SHENKEN E. – Corneal and conjunctival deposits in monoclonal gammopathy. *Can J Ophthalmol* 1983; 18: 142-149.
- (6) CHONG E., CAMPBELL R.J., BOURNE W.M. – Vortex keratopathy in a patient with multiple myeloma. *Cornea* 1997; 16: 592-594.
- (7) GARIBALDI D.C., GOTTSCH J., DE LA CRUZ Z., HAAS M., GREEN W.R. – Immunotactoid keratopathy: a clinicopathologic case report and a review of reports of corneal involvement in systemic paraproteinemias. *Surv Ophthalmol* 2005; 50: 61-80.
- (8) HURLEY I.W.J., BROOKS A.M.V., REINEHR D.P., GRANT G.B., GILLIES W.E. – Identifying

- anterior segment crystals. Br J Ophthalmol 1991; 75: 329-331.
- (9) KLINTWORTH G.K., BREDEHOEFT S.J., REED J.W. – Analysis of corneal crystalline deposits in multiple myeloma. Am J Ophthalmol 1978; 86: 303-313.
- (10) MILLER K.H., GREEN W.R., STARK W.J., WELLS H.A., MENDELSON G., KANHOFER H. – Immunoprotein deposition in the cornea. Ophthalmology 1980; 87: 944-950.
- (11) PERRY H.D., DONNENFELD E.D., FONT R.L. – Intraepithelial corneal immunoglobulin crystals in IgG-Kappa multiple myeloma. Cornea 1993; 12: 448-450.
- (12) RODRIGUES M.M., KRACHMER J.H., MILLER S.D., NEWSOME D.A. – Posterior corneal crystalline deposits in benign monoclonal gammopathy: a clinicopathologic case report. Arch Ophthalmol 1979; 97: 124-128.
- (13) STEUHL K.P., KNORR M., ROHRBACH J.M., LISCH W., KAISERLING E., THIEL H.J. – Paraproteinemic corneal deposits in plasma cell myeloma. Am J Ophthalmol 1991; 111: 312-318.

.....

*Correspondence and reprints:*

*Dr. N. HOUBEN  
Kattestaartstraat 37  
B-3690 ZUTENDAAL  
E-mail: nathaliehouben99@hotmail.com*