
PHOTODYNAMIC THERAPY WITH VERTEPORFIN IN BELGIAN PATIENTS WITH SUBFOVEAL CHOROIDAL NEOVASCULARIZATION SECONDARY TO AGE-RELATED MACULAR DEGENERATION

MORI R, KELKAR A**, DE LAEY J.J.****

SUMMARY

This is a retrospective, uncontrolled study of 55 patients (61 eyes) treated between January 2002 and January 2004 with Photodynamic Therapy with Verteporfin for subfoveal choroidal neovascularization (CNV) secondary to age-related macular degeneration. The eyes were divided into three groups: predominantly classic CNV (21 eyes), minimally classic CNV (7) and occult with no classic CNV (4 eyes). For 31 patients (32 eyes) the follow-up period was at least one year. The following parameters were studied: visual acuity, progression of the CNV, and activity of the CNV expressed as leakage on fluorescein angiography and edema on OCT. In the group of predominantly classic CNV at 12 month the treatment resulted in an inactive lesion in 43 % of the eyes, however in 48 % the visual acuity had decreased. For the group of minimally classic CNV, regression of activity was noted in 71 % but vision further decreased in 57 %. In the group of occult with no classic CNV one eye developed classic CNV, whereas the lesion regressed on 3 eyes. Two of the 4 eyes lost vision. These results suggest that although PDT is capable

of stabilizing the lesion, further visual loss is to be expected in a large number of patients.

SAMENVATTING

Het gaat hier om een retrospectieve, niet gecontroleerde studie bij 55 patiënten (61 ogen) die tussen januari 2002 en januari 2004 een fotodynamische behandeling ondergingen met Verteporfin wegens subfoveale chorioidale neovascularisatie (CNV) tengevolge van leeftijdsgebonden maculadegeneratie. De ogen werden in 3 groepen verdeeld: overwegend klassieke CNV (21 ogen), minimaal klassieke CNV (7 ogen) en occulte zonder klassieke component (4 ogen). Een en dertig patiënten (32 ogen) werden minstens 12 maanden gevolgd. De volgende parameters werden onderzocht: visus, toename van membraan en activiteit bepaald door middel van fluorescentie angiografie en met behulp van de OCT. Na 12 maanden vertoonden 43 % van de groep met predominerende klassieke CNV een inactief letsel, in 48 % van deze groep was de visus verder gedaald. Bij de minimaal klassieke membranen werd een objectieve stabilisatie van de membraan getoond in 71 % en verder visus verlies in 57 %. In de groep met occulte CNV ontwikkelde één oog een klassieke component terwijl de letsels in de 3 andere ogen gestabiliseerd waren. Twee van de 4 ogen verloren verder visus. Deze resultaten wijzen erop dat alhoewel een objectieve stabilisatie van de CNV kan bekomen worden, de visus in de meeste ogen verder zal dalen.

.....

* *Department of Ophthalmology, Nihon University School of medicine, Tokyo, Japan.*

** *National Institute of Ophthalmology, Puna, India.*

*** *Department of Ophthalmology, Ghent University Hospital, Belgium.*

Received: 09.01.06

Accepted: 14.02.06

RÉSUMÉ

Il s'agit d'une étude rétrospective et non contrôlée chez 55 patients (61 yeux) traités entre le 1 janvier 2002 et le 1 janvier 2004 par Thérapie Photodynamique à la Verteporfin (PDT) pour une membrane choroïdienne néovasculaire sous-fovéale dans le cadre d'une dégénérescence maculaire liée à l'âge. Les yeux ont été divisés en 3 groupes: néovascularisation de type prédominant classique (21 yeux); atteinte classique minimale (7 yeux) et occulte sans composante classique (4 yeux). Le suivi a été d'au moins douze mois pour 31 patients (32 yeux). Les paramètres suivants ont été étudiés: acuité visuelle, évolution de la taille de la lésion et activité de celle-ci déterminée par angiographie fluorescéinique et par OCT. Après 12 mois 43 % des membranes de type prédominant classique étaient inactives, tandis que la vision avait baissé dans 48 %. Dans le groupe avec atteinte classique minimale 71 % des membranes étaient stabilisées et une perte de vision était retrouvée dans 57 % des cas. Un oeil présentant une membrane néovasculaire de type occulte a progressé vers une membrane de type classique tandis que dans les 3 autres yeux une stabilisation de la membrane occulte était obtenue. Dans 2 de ces 4 yeux une perte de vision a été notée. Ces résultats indiquent que la PDT parvient dans de nombreux cas à contrôler l'évolution de la membrane néovasculaire sous-rétinienne mais que malgré tout la vision risque de se détériorer.

KEY WORDS

subretinal newvessels, age related macular degeneration, photodynamic therapy, Verteporfin.

MOTS-CLÉS

néovaisseaux sous-rétiniens, dégénérescence maculaire liée à l'âge, thérapie photodynamique, Verteporfin

INTRODUCTION

Subfoveal choroidal neovascularization (CNV) secondary to age-related macular degeneration (AMD) has usually a poor prognosis. In general subfoveal CNV is not an indication for laser coagulation treatment, because laser coagulation produces a central scotoma and a severe loss of visual acuity. Therefore, alternative treatments such as radiation therapy, feeder vessel photocoagulation, transpupillary thermotherapy, extraction of CNV, full or limited macular translocation have been advocated. Also new pharmacotherapies aimed at the suppression of growth factors have emerged. Recently photodynamic therapy (PDT) with Verteporfin (Visudyne; Novartis AG, Basel, Switzerland) has been approved in many countries for the treatment of CNV secondary to AMD. The aim of this study was to evaluate the outcome of PDT in a Belgian population.

PATIENTS AND METHODS

This study was designed as a retrospective, uncontrolled chart review. All charts and fundus fluorescein angiograms (FA) of patients with the diagnosis of AMD treated with PDT between January 2002 and January 2004 at the Ghent University Hospital were collected. The inclusion criteria were as follows: all patients had to have fluorescein angiographic evidence of active CNV secondary to AMD extending under the geometric center of the foveal avascular zone, a visual acuity of at least 1/10 in the affected eye in the case of a classic type of CNV and between 1/10 and 4/10 in predominantly occult subfoveal CNV. Evidence of retinal edema had to be present on optical coherence tomography (OCT) or stereoscopic imaging. Only patients with at least 12 months of follow-up were included.

All patients received a comprehensive ocular examination, including dilated fundus examination with a 90-D lens, followed by color fundus photography and a fluorescein angiography (FA) at baseline and at every 3-month visit. Best corrected visual acuity was measured with a standard Snellen chart. To quantify the

differences in vision, all Snellen best corrected visual acuities were converted to the logarithm of the minimum angle of resolution (LogMAR). Counting finger VA was considered equal to 1/200 or to logMAR visual acuity of 2.3. In this report, a stable visual acuity was defined as a gain or a loss of <0.2 logMAR, an increase in visual acuity was defined as a gain of ≥ 0.2 logMAR and a decreased visual acuity was defined as a loss of ≥ 0.2 logMAR.

We classified patients into three groups: predominantly classic CNV, minimally classic CNV and occult with no classic CNV. Predominantly classic CNV is a lesion in which the area of classic CNV occupies at least 50% of the area of the entire lesion. Minimally classic CNV is a lesion in which the area of classic CNV occupies <50% but >0% of the area of the entire lesion. Occult CNV with no classic CNV was defined according to the Macular Photocoagulation Study (6).

Verteporfin therapy was performed according to the standard protocol outlined in the treatment of age-related macular degeneration with photodynamic therapy (TAP) study, and Verteporfin in photodynamic therapy (VIP) study (1-3). Five minutes after the completion of a 10-minute infusion of Verteporfin at a dose of 6 mg/m² of body surface area, diode laser treatment (wavelength of 689nm: Coherent Opal; Santa Clara, CA, USA) with a dose of 50 J/cm² was applied for 83 seconds on the lesion. The spot size was determined by adding

1,000 μ m to the greatest linear dimension (GLD) of the lesion. After treatment, patients were instructed to protect the skin from bright light and to wear sunglasses for 48 hours.

Additional courses of therapy for eligible patients were recommended as often as every 3 months if fluorescein leakage from CNV and/or macular edema or retinal detachment on optical coherence tomography (OCT) was observed. The interval between two consecutive treatments was at least 3 months. If the visual acuity was less than 20/200 no retreatment was offered.

RESULTS

PATIENT CHARACTERISTICS

Fifty-nine patients (61 eyes) with subfoveal CNV secondary to AMD treated with PDT were collected and we obtained the 12 months follow-up data (visual acuity and FA) of thirty-one patients (32 eyes). The baseline characteristics of these patients are presented in Table 1. Of the 31 patients, 13 (42%) were women, 18 (58%) were men. Their mean age was 74.1 years (SD \pm 9.2, range 52-91 years). Twenty one eyes (65%) had a predominantly classic lesion, 7 eyes (22%) had a minimally classic lesion and 4 eyes (13%) had an occult with no classic CNV.

Table 1. *Baseline characteristics*
CNV = choroidal neovascularization

	<i>All patients</i>	<i>Predominantly Classic CNV</i>	<i>Minimally Classic CNV</i>	<i>Occult CNV with No Classic CNV</i>
	<i>32 eyes of 31 patients n=31 (%)</i>	<i>21 eyes of 20 patients n=20 (%)</i>	<i>7 eyes of 7 patients n=7 (%)</i>	<i>4 eyes of 3 patients n=4 (%)</i>
Gender				
Women	13 (42)	10 (50)	4 (57)	4 (100)
Men	18 (58)	10 (50)	3 (43)	0 (0)
Age (years)				
50 - 54	2 (7)	1 (5)	0 (0)	1 (25)
55 - 64	2 (7)	2 (10)	0 (0)	0 (0)
65 - 74	10 (31)	6 (30)	3 (43)	1 (25)
75 - 84	15 (48)	9 (45)	4 (57)	2 (50)
≥ 85	2 (7)	2 (10)	0 (0)	0 (0)
Mean	74.1 \pm 9.2	74.8 \pm 9.7	74.4 \pm 4.8	70.3 \pm 13.3

Table 2. Lesion size at baseline (1) and after 12 months (B)

Lesion size (MPS disc areas)	All patients n=32 (%)		Predominantly Classic CNV n=21 (%)		Minimally Classic CNV n=7 (%)		Occult CNV With No Classic CNV n=4 (%)	
	A	B	A	B	A	B	A	B
≤3	24 (75)	14 (44)	19 (90)	12 (57)	2 (29)	1 (14)	3 (75)	1 (25)
> 3 to ≤6	3 (9)	6 (19)	0 (0)	4 (19)	2 (29)	1 (14)	1 (25)	1 (25)
> 6 to ≤9	5 (16)	9 (28)	2 (10)	4 (19)	3 (42)	3 (43)	0 (0)	2 (50)
> 9	0 (0)	3 (9)	0 (0)	1 (5)	0 (0)	2 (29)	0 (0)	0 (0)

Baseline lesion size and greatest linear diameter (GLD) are presented in Table 2. In 24 of the 32 eyes (75 %) the baseline lesion size was equal or less than 3 MPD disc areas (1 MPS DA= 2,5mm²), whereas the GLD was equal or less than 3 MPS Disc Diameter (1 MPS DD = 1,83 mm) in 29 eyes (91 %). In the group of the predominantly classic CNV, 19 eyes (90%) had a baseline lesion size of ≤ 3 MPS DA, 20 eyes (95%) had a GLD of ≤ 3 MPS DD. Also in the group of the minimally classic CNV and of occult CNV with no classic CNV, respectively 2 eyes (29%) and 3 eyes (75%) had a baseline lesion size of ≤ 3 MPS DA, whereas respectively 6 eyes (86%) and 3 eyes (75%) had a GLD of ≤ 3 MPS DD.

Baseline visual acuity is presented in Table 3. The mean logMAR visual acuity was 0.53 (SD±0.29) in the total group, 0.60 (SD±0.23) in the group of the predominantly classic CNV, 0.51 (SD±0.24) in the group of the minimally classic CNV and 0.29 (SD±0.18) in the group of the occult CNV with no classic CNV. The vi-

sual outcome at 12 months is presented in Table 3 and Table 4. The mean logMAR visual acuity was 1.06 (SD±0.8) in the total group, 1.16 (SD±0.81) in the group of predominantly classic CNV, 1.14 (SD±0.87) in the group of minimally classic CNV and 0.38 (SD±0.30) in the group of occult CNV with no classic CNV. In the total group, 12 eyes (37%) ended with a visual acuity of <20/200. In the group of predominantly classic CNV and in the group of minimally classic CNV, respectively 9 eyes (43%) and 3 eyes (43%) had a visual acuity of < 20/200 at 12 months. In the group of occult with no classic CNV, no eyes had a visual acuity of < 20/200 at 12 months. In the total group, the visual acuity remained stable or increased ≥0.2 logMAR in 15 eyes (47%). In the group of predominantly classic CNV, minimally classic CNV and the occult CNV with no classic CNV, visual acuity remained stable or increased ≥ 0.2 logMAR in respectively 10 eyes (48%), 3 eyes (43%) and 2 eyes (50%).

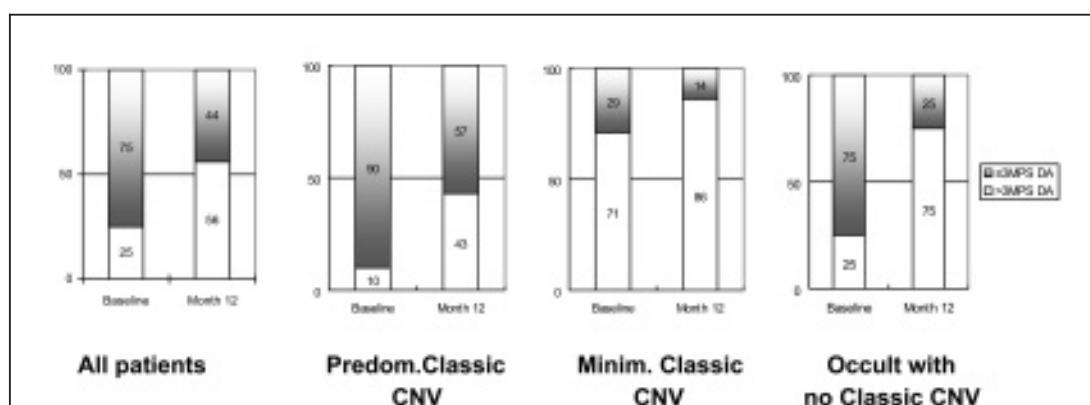


Figure 1. Lesion size by time
CNV = choroidal neovascularization • MPS = Macular Photocoagulation Study • DA = disc areas

Table 3. Visual acuity (VA) at baseline (A) and at 13 months follow-up (B)

	All patients		Predominantly Classic CNV		Minimally Classic CNV		Occult CNV With No Classic CNV	
	n=32 (%)		n=21 (%)		n=7 (%)		n=4 (%)	
	A	B	A	B	A	B	A	B
> 20/40	8 (25)	6 (19)	5(24)	4 (19)	1(14)	0 (0)	2(50)	2 (50)
20/40-20/80	9 (28)	5 (16)	3(14)	1 (5)	4(57)	3 (43)	2(50)	1 (25)
20/100-20/200	15 (47)	9 (28)	13(62)	7 (33)	2(29)	1 (14)	0 (0)	1 (25)
<20/200	0 (0)	12 (37)	0 (0)	9 (43)	0 (0)	3 (43)	0 (0)	0 (0)
Mean log MAR VA								
A	0.53±0.29		0.60±0.23		0.51±0.24		0.29±0.18	
B	1,06 ± 0,8		1,16±0,81		1,14±0,87		0,38±0,30	

Table 4. Visual acuity Outcome

	All patients		Predominantly Classic CNV		Minimally Classic CNV		Occult CNV With No Classic CNV	
	n=32 (%)		n=21 (%)		n=7 (%)		n=4 (%)	
Increase (≥ logMAR 0.2)	2(6)		1 (5)		1 (14)		0 (0)	
Stable (< logMAR 0.2)	13 (41)		9 (43)		2 (29)		2 (50)	
Decrease (≥ logMAR 0.2)	17 (53)		11 (52)		4 (57)		2 (50)	

CNV = choroidal neovascularization • logMar = logarithm of the minimum angle of resolution

The lesion size at month 12 is presented in Table 2 and in Figure 1. In the total group, 14 eyes (44%) had a lesion size of ≤ 3 MPS DA compared with 24 eyes (75%) at base line. In the group of predominantly classic CNV, 12 eyes (57%) had this size as compared to 19 eyes (90%) at base line. In the group of minimally classic CNV, only 1 eye (14%) had this size as compared to 2 eyes (29%) at base line. In the group of occult with no classic CNV, 1 eye (25%) had this size as compared to 3 eyes (75%) at base line.

For the primary efficacy variable, the proportion of patients with progression of classic CNV beyond the area of the lesion observed at baseline is shown in Figure 2. By the examination at month 12, in the total group, 12 eyes (38%) had progression of classic CNV compared with baseline and fluorescein leakage from classic CNV was absent in 13 eyes (41%). In the group of predominantly classic CNV and of minimally classic CNV, progression of classic CNV was noted in respectively 9 eyes(43%)and 2 eyes (29%) and absence of leakage from classic CNV

in 9 eyes (43%) and 1 eye (15%). In one patient with initially occult with no classic CNV, a classic component appeared during follow-up. The progression of occult CNV at the month 12 examination beyond the area of the lesion observed at baseline is shown in Figure 3. By the month 12 examination, in the total group, 2 eyes (6%) had progression of occult CNV compared with baseline and fluorescein leakage from occult CNV was absent in 28 eyes (88%). In the group of predominantly classic CNV, minimally classic CNV and occult with no classic CNV, progression of occult CNV was noted respectively in 1 eye (5%),no eye and 1 eye (25%) and absence of leakage from occult CNV in 20 eyes (95%), 5 eyes (71%) and 3 eyes (75%).

The number of treatment sessions is presented in Table 5. By the month 12 examination, patients had received a mean of 1.8 treatments in the total group, 1.8 sessions in the group of predominantly classic CNV, 2.0 sessions in the group of minimally classic CNV and 1.8 sessions in the group of occult with no classic CNV.

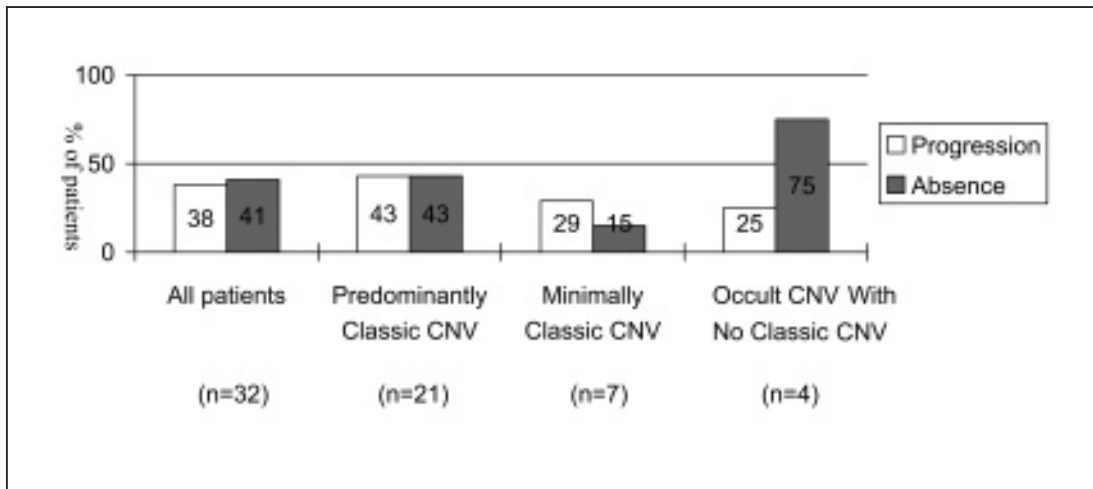


Figure 2. 12 month examination: Percentage of eyes with progression of classic choroidal neovascularization (CNV) beyond the baseline lesion border as evaluated from fluorescein angiography or absence of leakage from classic CNV for the study eye.

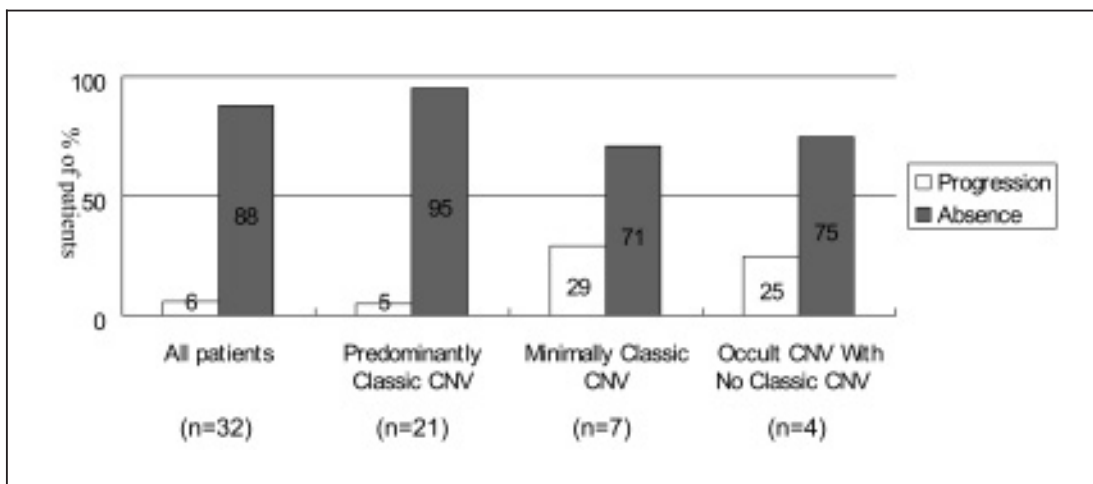


Figure 3. 12 month examination: Percentage of eyes with progression of occult choroidal neovascularization (CNV) beyond the baseline lesion border as evaluated from fluorescein angiography or absence of leakage from occult CNV for the study eye.

DISCUSSION

The purpose of this study was to evaluate the outcome of PDT in a Belgian population with subfoveal CNV secondary to AMD. Patients in this study had lesions that were more predominantly classic CNV and smaller on average as compared with those in the TAP Study. In our series, 21 eyes (66%) had a predominantly classic CNV as compared to 159 eyes (40%) in the TAP Study, and 19 eyes (90%) with a

predominantly classic CNV had a lesion size of ≤ 3 MPS DA as compared to 78 eyes (48%) in the TAP Study (4). In the study period many eyes with predominantly classic CNV of size ≥ 3 MPS had already a visual acuity of less than 20/200, and were thus not eligible for PDT.

When taking into account the FA outcomes: in the group of predominantly classic CNV, the rate of progression of leakage from classic CNV was 43% compared to 57% in the TAP Study

Table 5. Number of treatments

	<i>All patients</i>	<i>Predominantly Classic CNV</i>	<i>Minimally Classic CNV</i>	<i>Occult CNV With No Classic CNV</i>
	<i>n=32 (%)</i>	<i>n=21 (%)</i>	<i>n=7 (%)</i>	<i>n=4 (%)</i>
1	12 (38)	9 (43)	1 (14)	2 (50)
2	15 (47)	9 (43)	5 (72)	1 (25)
3	4 (12)	2 (9)	1 (14)	1 (25)
4	1 (3)	1 (5)	0 (0)	0 (0)
Mean	1.8	1.8	2.0	1.8

and the prevalence at final examination of absent leakage from classic CNV was 43% compared to 14% in the TAP Investigation (4). These results suggest that PDT is more effective in occluding classic CNV lesion and smaller lesions. As regards visual acuity outcomes, 48% had a moderate or severe visual acuity loss as compared to 33% in the TAP. This study defined a moderate visual acuity loss as a loss of ≥ 15 letters or approximately ≥ 3 lines and a severe visual acuity loss as ≥ 30 letters or approximately ≥ 6 lines (4). After 1 year, 4 eyes (19%) were able to keep a visual acuity of at least 20/40, but 9 eyes (43%) had a visual acuity of less than 20/200. In the group of the predominantly classic CNV, it is difficult for PDT to maintain baseline visual acuity.

In the group with minimally classic CNV, progression of classic CNV was observed in only 29% and occult CNV was absent in 71%. In the group of occult with no classic CNV, one eye (25%) developed classic CNV, and occult CNV was absent in 75%. These results suggest the usefulness of PDT for controlling choroidal new vessels in both groups. However, visual acuity decreased in 57% in the group with minimally classic CNV and in 50% in the group of occult with no classic CNV. This may be partly because the baseline visual acuity was $\geq 20/80$ in 71% and 100%, respectively. In the two groups, also, PDT was not useful for maintaining visual acuity. However, in the group with occult CNV with no classic CNV, no eye showed a visual acuity less than 20/200 after 1 year PDT. In the two groups, since the number of cases was only 7 and 4 eyes, respectively, direct comparison of results with the TAP or VIP study is impossible (4-5).

CONCLUSION

The data in this study show that in 50% of the total group, visual acuity decreased as compared to pretreatment visual acuity. In the groups with predominantly classic CNV or minimally classic CNV, visual acuity decreased to less than 20/200 in more than 50% of the cases. These results suggest that improvement in central vision for AMD is seldom obtained with PDT alone. In the future, the effects of PDT may increase when combining it with other treatment modalities.

REFERENCES

- (1) Treatment of age-related macular degeneration with photodynamic therapy (TAP) study group: Photodynamic therapy of subfoveal choroidal neovascularization in age-related macular degeneration with Verteporfin: one-year results of 2 randomized clinical trials-TAP report 1. *Arch Ophthalmol.* 1999, 117:1329-1345.
- (2) Treatment of age-related macular degeneration with photodynamic therapy (TAP) study group: Photodynamic therapy of subfoveal choroidal neovascularization in age-related macular degeneration with Verteporfin: two-year results of 2 randomized clinical trials-TAP report 2. *Arch Ophthalmol.* 2001, 119:198-207.
- (3) Verteporfin in photodynamic therapy study group: Photodynamic Verteporfin therapy of subfoveal choroidal neovascularization in pathologic myopia with verteporfin: 1 year results of a randomized clinical trial -VIP report NO.1. *Ophthalmology* 2001, 108:841-852.
- (4) Verteporfin in photodynamic therapy study group: Verteporfin therapy of subfoveal choroidal neovascularization in age-related macular degeneration: two-year results of a randomized clinical trial including lesions with occult with no classic choroidal neovascularization- Vertepor-

- fin in photodynamic therapy report 2. Am J Ophthalmol. 2001,131:541-560.
- (5) Treatment of age-related macular degeneration with photodynamic therapy (TAP) study group. Verteporfin therapy of subfoveal choroidal neovascularization in patients with age-related macular degeneration : additional information regarding baseline lesion composition's impact on vision outcomes- TAP report NO.3. Arch Ophthalmol. 2002, 120:1443-1454.
- (6) Verteporfin roundtable 2000 and 2001 participants, treatment of age-related macular degeneration with photodynamic therapy (TAP) study group principal investigators, and Verteporfin in photodynamic therapy (VIP) study group

principal investigators, Guidelines for using Verteporfin (Visudyne[®]) in photodynamic therapy to treat choroidal neovascularization due to age-related macular degeneration and other causes Retina 2002, 22:6-18.

.....

Correspondence and reprints:
Prof.J.J.DE LAEY
Department of Ophthalmology,
Ghent University Hospital,
de Pintelaan, 185,
B-9000 Ghent
e-mail: jean.delaey@ugent.be