

# LATE OPACIFICATION OF HYDROVIEW INTRAOCULAR LENSES: REPORT OF 11 CASES

MOESEN I.\*, MAUDGAL P.C.\*, FOETS B.\*

## SUMMARY

*Purpose:* To report on the clinical and light microscopic analyses of Hydroview intraocular lenses (IOLs) explanted for late postoperative IOL opacification.

*Material and Methods:* Retrospective study of all cases with secondary lens implantation performed at the University Hospital Leuven during a period of one year (2003-2004) for postoperative opacification of Hydroview IOLs. Further analyses on some of the explanted IOLs included gross and light microscopic evaluation.

*Results:* Lens exchange for late-onset IOL opacification was performed in eleven eyes of eight patients. IOL opacification became apparent between 12 and 24 months after uneventful phacoemulsification and lens implantation. Visual acuity varied from  $< 0.05$  to 0.6 before explantation. In 9 out of the 11 eyes postoperative visual acuity improved to the pre-opacification level. Light microscopic analyses showed a granular anterior lens surface morphology composed of calcium.

*Conclusion:* Late postoperative opacification of Hydroview IOLs may cause severe visual impairment, requiring explantation. Calcium is involved in the formation of these opacifications. Reporting on this type of complications is mandatory according to the Belgian and European directives for medical devices.

## RÉSUMÉ

*But:* Etude clinique et microscopique de lentilles intra-oculaires Hydroview, explantées pour opacification postopératoire tardive.

.....

\* *Department of Ophthalmology, University Hospitals Leuven, Belgium*

*Received:* 18.11.05

*Accepted:* 21.01.06

*Matériel et méthodes:* Etude rétrospective de tous les cas d'implantation secondaire effectués à l'Hôpital Universitaire de Louvain pendant un an (2003-2004), suite à l'opacification postopératoire de lentilles Hydroview. Des examens macroscopiques et microscopiques ont été pratiqués sur certaines lentilles explantées.

*Résultats:* Un échange de lentille a été exécuté dans onze yeux de huit patients. L'opacification est apparue 12 à 24 mois après une phaco-émulsification par ailleurs sans complications. L'acuité visuelle variait de  $< 0.05$  à 0.6 avant l'échange. Dans neuf des 11 yeux, l'acuité visuelle a récupéré le niveau pré-opacification. L'analyse microscopique a montré une opacification granulaire, située dans la partie antérieure de l'optique et composée de calcium.

*Conclusion:* L'opacification tardive de l'implant Hydroview cause une baisse sévère de l'acuité visuelle, nécessitant une explantation. Les opacifications sont formées de calcium. Il est obligatoire de rapporter ce genre de complication d'après les législations belges et européennes sur les dispositifs médicaux.

## SAMENVATTING

*Doel:* Beschrijving van de klinische en licht-microscopische analyse van Hydroview intraoculaire lenzen (IOL), die geëxplanteerd werden omwille van laattijdige postoperatieve IOL opacificatie.

*Materiaal en methoden:* Retrospectieve studie van alle gevallen van secundaire lensimplantatie, uitgevoerd aan de Universitaire Ziekenhuizen Leuven gedurende de periode van één jaar (2003-2004), voor postoperatieve opacificatie van Hydroview intraoculaire lenzen. Verdere analyse van een aantal geëxplanteerde lenzen omvatte macroscopische en licht-microscopische analyse.

*Resultaten:* Secundaire lensimplantatie naar aanleiding van laattijdige IOL opacificatie werd uitgevoerd in elf ogen van acht patiënten. De IOL opacificatie werd zichtbaar tussen 12 en 24 maanden na de initiële phaco-emulsificatie en lensimplantatie. De

visus voor explantatie varieerde tussen  $< 0.05$  en  $0,6$ . In 9 van de 11 ogen verbeterde de postoperatieve visus tot het niveau van voor de opacificatie. Licht-microscopische analyse toonde een korrelige neerslag van calcium in het voorste gedeelte van de IOL optiek.

Conclusie: Laattijdige postoperatieve opacificatie van Hydroview IOLs kan ernstig visusverlies veroorzaken waardoor lensexplantatie noodzakelijk is. Calcium is betrokken bij de vorming van deze opacificaties. Het rapporteren van dit type complicatie is verplicht volgens de Belgische en Europese richtlijnen voor medische hulpmiddelen.

#### KEY WORDS

Hydroview IOL, IOL opacification, IOL exchange

#### MOTS-CLÉS

lentilles intra-oculaires Hydroview, opacification tardive, explantation

## INTRODUCTION

Delayed postoperative calcification of implanted intraocular lenses (IOLs) has been reported to affect some hydrogel lenses (1,3,5,7,9,11-14). Opacification of the Hydroview hydrogel IOL causes progressive visual impairment and is resistant to treatment with Nd:YAG capsulotomy. Dorey and associates (2) have shown this opacification to be secondary to the postoperative deposition of calcium on the lens surface, associated with the Surefold packaging system. Explantation and IOL exchange is required for improvement of vision.

In this report, eight patients (eleven eyes) with visual loss due to IOL calcification were treated by IOL exchange.

## MATERIALS AND METHODS

We collected retrospectively all cases of IOL exchanges for late-onset postoperative Hydroview IOL opacification performed at the University Hospital Leuven between April 2003 and May 2004. Eleven Hydroview hydrogel lenses (model H60M), all of which were packaged with the Surefold system, were explanted from eight patients. All patients presented with decreasing visual acuities or quality of vision associated with a granular-appearing opacification of the lens optic.

In all patients histories were taken including sex, age, medical history and ophthalmic history. Surgical details of the initial IOL implantation (type of anesthesia, viscoelastic material used, intraoperative irrigation solution used and IOL model/power) were retrieved.

IOL exchange was performed under retrobulbar anesthesia by two surgeons, on average 33.4 months (range, 28-40 months) after uneventful phacoemulsification and IOL implantation into the capsular bag. The effect of the procedure, surgical techniques and difficulties encountered were evaluated.

Four explanted Hydroview IOLs were analysed by light microscopy.

## RESULTS

### PATIENT HISTORY AND HYDROVIEW IOL IMPLANTATION

The mean age of the 5 men and 3 women was 73 years (between 55 and 80 years). Most patients had some systemic disease: diabetes mellitus in 3 patients, hypertension in 3 patients and one patient had cardiovascular surgery for ischaemic heart disease in the past. One patient had COPD treated by corticosteroids; this patient also had a history of alcoholabusus. There was one patient with Guillain-Barré. In the ophthalmic history there were two patients with diabetic retinopathy for which one patient had received panretinal photocoagulation. One patient had idiopathic anterior uveitis and one patient was under topical treatment for POAG. All patients underwent cataract surgery by phacoemulsification with Hydroview IOL implantation between November 2000 and January 2001. Five surgeons in 5 regional hospitals in Belgium performed the initial IOL implantations. Local anesthesia was used in 5 patients, topical anesthesia in 2 and general anesthesia in 1. Balanced salt solution (BSS) was used in 3 eyes, BSS plus in 8 eyes. Healon GV was used in 6 eyes, Viscoat in 2 eyes, Provisc in 2 eyes and Duovisc in 1. Phacoemulsification and intracapsular implantation of a Hydroview IOL was uneventful in all cases.

Mean visual acuity improved from 0.4 (range 0.2 to 0.8) preoperatively to 0.8 (range 0.2 to 1.0) postoperatively. There were no significant postoperative complications.

### HYDROVIEW IOL OPACIFICATION

Opacification of the IOLs was noticed a mean of 20 months (range 12 to 24 months) after implantation. The right eye was affected in 4 cases and the left eye in 7 cases. Both eyes were affected in three patients. All patients complained of haze or foginness. The clinical appearance of all 11 lenses was similar, with the presence of confluent, granular, white deposits on the surface (*Fig 1*). Forceps marks were clearly visible on the IOL optic. Visual acuity decreased dramatically to values between 0.6 and < 0.05. In all but one patient, a Nd:Yag-

capsulotomy was performed in an attempt to clear the visual axis.

### IOL EXCHANGE

All IOL exchanges were performed at the University Hospital Leuven under retrobulbar anaesthesia by two surgeons between April 2003 and May 2004, 33.4 months (range 28-40 months) after the initial surgery.

Complete separation of the IOL from the capsular bag was achieved in 9 cases. Significant adhesions between the IOL haptics and the capsular bag were noted in most eyes. Attempts to dial the IOL resulted in significant stress to the zonules. In 3 cases, one IOL haptic was cut to avoid zonular stress. Six patients developed zonular dehiscence and one patient developed a posterior capsule rupture. All patients with zonular dehiscence or posterior capsule rupture were managed with a secondary sulcus-lens.

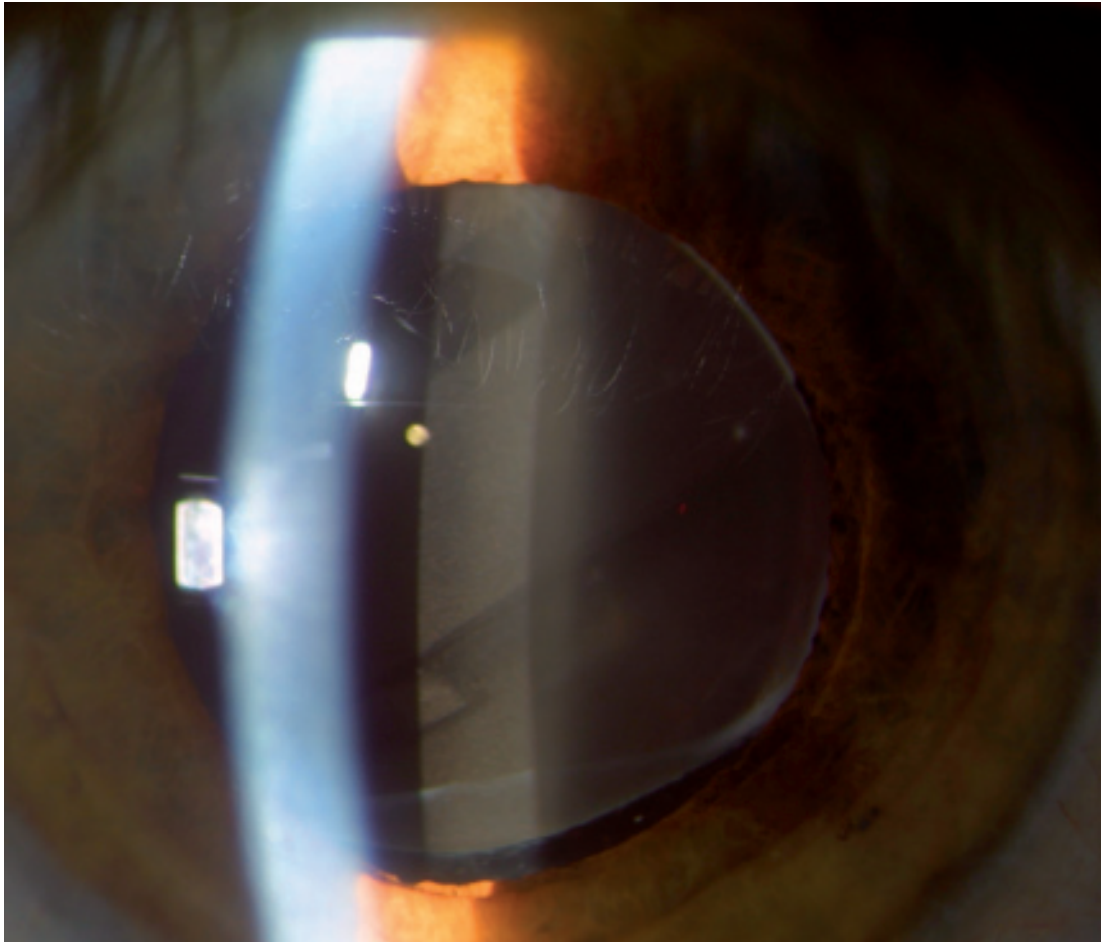
In 2 cases, the IOL could not be separated from the capsular bag and an irisclawlens was placed after removal of the IOL and capsular bag in toto.

In 1 patient, the IOL could be separated without zonular dehiscence or posterior capsule rupture; this patient had in-the-bag placement of the secondary IOL.

Best corrected visual acuity postoperatively increased to 0.8 (range 0.2-1.0). In nine of the eleven cases visual acuity of the pre-opacification level was reached. One patient lost 2 Snellen lines and one patient lost 1 Snellen line compared to the immediate visual acuity after primary cataract surgery.

### ANALYSIS OF THE EXPLANTED IOLS

In order to evaluate the composition of the IOL opacification, four explanted opacified Hydroview IOLs were subjected to analysis by light microscopy. At high magnification (50X), a granular lens surface topography with a white cloudy appearance could be demonstrated. A mixture of Alizarin Red S and ammonium hydroxide was prepared and adjusted to a pH of 6.3 using 1.0 sodium hydroxide. Each lens was cut into two pieces and one piece was soaked in Alizarin Red S mixture for 7 minutes. The



*Fig 1.* Hydroview IOL opacification with clear forceps marks

Alizarin Red S colored the grain-like surface morphology of the lenses, indicating that the grain-like areas were composed of calcium.

## DISCUSSION

The Hydroview intraocular lens ( Bausch and Lomb Surgical, Rochester, New York, USA) is a foldable hydrogel posterior chamber IOL, on the market since 1995. A silicone-gasket packaging system known as the Surefold system (Bausch and Lomb Surgical, Rochester, New York, USA) was introduced in 1997 and specifically designed for this IOL. Reports of fogging or clouding of this IOL months to years after implantation began to appear in 05/1999, with a final count of 354 of 790.000 lenses sold (Bausch and Lomb, internal data).

A high proportion of patients in this study had systemic disease, notably diabetes mellitus, hypertension and ischaemic heart disease. Hydroview IOL is more likely to calcify in patients with a compromised blood-retinal barrier (2). In these patients, the aqueous is readily exposed to serum molecules, including fatty acids that are more abundant in patients with an altered lipid metabolism. In vitro studies support the conclusion that fatty acids are necessary for calcium phosphate to nucleate onto the IOL, with silicone molecules as the anchor point (4). However, Hydroview IOL opacification has also been described in patients without medical history (5,13,15).

In our series, the initial implantation of the Hydroview IOL was uneventful in all cases, as in almost all reported series (3,5-7,9,11-15). Two

different types of irrigation solutions and four types of viscoelastic were used. Intraoperative crystallization on intraocular lens surfaces associated with the use of Healon GV has been reported (8,10).

Hydroview IOL opacification has been observed the earliest 4 months and the latest 29 months postoperatively (2,11,13,15). In our series, IOL opacification became obvious between 12 and 24 months after initial surgery. Late opacification causes progressive visual impairment. Most patients complained of haze or fogging. Visual acuity dropped below 0.05 Snellen lines in 2 cases. Similar reports exist (5,11-15). Slit-lamp examination showed a granular-appearing opacification in the superficial substance of the optic, with clear forcepsmarks. Yu and associates (15) observed clear forcepsmarks in 96% of their cases. They are thought to represent two linear areas with a different opacification density, caused by squeezing some of the silicone compounds out of the porous hydrogel optic when applying the forceps during surgery. Treatment with Nd:Yag laser is unsuccessful (3,12). In our series, all but one patient received Nd:Yag laser in an attempt to clear the visual axis or to remove the deposit. Intraocular lens exchange is the only treatment in patients with calcified hydrogel IOLs (13). Because of the late-onset of the opacification, adhesion to the capsular bag and in a few cases capsulophimosis developed. We noticed that the capsule adhered to the IOL haptic, but not the optic. As a result, in most cases the optic could be separated from the capsule by viscodissection, but the haptic had to be cut for IOL removal in 3 eyes. This difference between optic and haptic adhesion can be explained by the difference in material (14). In 2 cases the IOL could not be separated from the capsule and IOL and lenscapsule were removed in toto. The Hydroview IOL is a foldable IOL. It is possible to fold it in the eye and remove it through a 3.0mm to 4.0mm incision, as we performed in one case. Some authors describe bisecting foldable IOLs inside the eye before removal (15). This technique was applied in one case. In the majority of cases however, the calcified lenses were removed through 6.0mm incisions without folding or cutting them to minimize endothelial damage.

After IOL exchange, visual acuity improved up to the preopacification level in most but not all cases (5,15). In our series, one patient lost 2 Snellen lines, partially related to a progression of his diabetic retinopathy. One patient developed a retinal detachment and was treated by vitrectomy with silicone tamponade. After removal of the silicone oil, visual acuity improved to 0.7.

The grain-like surface topography found by light microscopic evaluation of the explanted Hydroview IOLs, coupled with the discovery of calcium at the grain-like locations is consistent with previous analyses performed on calcified IOLs (2,3,11). Spectroscopic analysis has shown the opacification to be located in the anterior portion of the IOL optic as a layer of irregular granular deposits composed of calcium phosphate (11).

## CONCLUSION

Late postoperative opacification of Hydroview IOLs causes progressive visual impairment, necessitating intraocular lens exchange. Aetiology seems to be multifactorial, related to silicone derived from the Surefold packaging system. After changing the packaging system in March 2001 with a newer system that does not utilize a silicone gasket, no reports on Hydroview IOL opacification have been published. As new materials are increasingly used, it is important to highlight such complications.

## REFERENCES

- (1) APPLE J.D., WERNER L., ESCOBAR-GOMEZ, PANDEY S.K. – Deposits on the optical surfaces of Hydroview intraocular lenses. *J. Cataract Refract. Surg.* 2000, 26, 796-797.
- (2) DOREY M.W., BROWNSTEIN S., HILL V.E., MATHEW B., BOTTON G., KERTES P.J., ELDEFRAWY S. – Proposed pathogenesis for the delayed postoperative opacification of the Hydroview hydrogel intraocular lens. *Am. J. Ophthalmol.* 2003, 135, 591-598.
- (3) FERNANDO G.T., CRAYFORD B.B. - Visually significant calcification of hydrogel intraocular lenses necessitating explantation. *Clin. Exp. Ophthalmol.* 2000, 28, 280-286.
- (4) GREEN F.G., WERNER L., APPLE D.J., LEVY B. – The Hydroview intraocular lens: develop-

- ment, early reports of calcification and subsequent actions, Bausch & Lomb, internal data.
- (5) GROH M.J., SCHLOTZER-SCHREHARDT U., RUMMELT C., VON BELOW H. – Postoperative opacification of 12 hydrogel foldable lenses. *Klin. Monatsbl. Augenheilkd.* 2001, 218, 645-648.
  - (6) HABIB N.E., FREEGARD T.J., GOCK G., NEWMAN P.L., MOATE R.M. – Late surface opacification of Hydroview intraocular lenses. *Eye* 2002, 16, 9-74.
  - (7) IZAK A.M., WERNER L., PANDEY S.K., APPLE D.J. – Calcification of modern foldable hydrogel intraocular lens designs. *Eye* 2003, 17, 393-406.
  - (8) JENSEN M.K., CRANDALL A.S., MAMALIS N., OLSON R.J. – Crystallization on intraocular lens surfaces associated with the use of Healon GV. *Arch. Ophthalmol.* 1994, 112, 1037-1042.
  - (9) LEE D-H., SEOL., JOO C-K. – Progressive opacification of hydrophilic acrylic intraocular lenses in diabetic patients. *J. Cataract Refract. Surg.* 2002, 28, 1271-1275.
  - (10) OLSON R.J., CALDWELL K.D., CRANDALL A.S., JENSEN M.K., HUANG S-C. – Intraoperative crystallization on the intraocular lens surface. *Am. J. Ophthalmol.* 1998, 126, 177-184.
  - (11) VAN LOOVEREN J., TASSIGNON M.J. – Intraocular lens exchange for late-onset opacification. *Bull Soc Belge Ophtalmol.* 2004, 293, 61-8.
  - (12) WERNER L., APPLE D.J., ESCOBAR-GOMEZ M., ÖHRSTRÖM A., CRAYFORD B.B., BIANCHI R., PANDEY S.K. – Postoperative deposition of calcium on the surfaces of a hydrogel intraocular lens. *Ophthalmology.* 2000, 107, 2179-2185.
  - (13) YU A.K.F., KWAN K.Y.W., CHAN D.H.Y. – Clinical features of 46 eyes with calcified hydrogel intraocular lenses. *J. Cataract Refract. Surg.* 2001, 27, 1596-1606.
  - (14) YU A.K.F., SHEK T.W.H. – Hydroxyapatite formation on implanted hydrogel intraocular lenses. *Arch. Ophthalmol.* 2001, 119, 611-614.
  - (15) YU A.K.F. – Complications and clinical outcomes of intraocular lens exchange in patients with calcified hydrogel lenses. *J. Cataract Refract. Surg.* 2002, 28, 1217-1222.
- .....
- Correspondence and reprints:*  
 Dr. MOESEN Ingemarie  
 University Hospitals Leuven  
 Department of Ophthalmology  
 Kapucijnenvoer 33  
 B-3000 Leuven  
 BELGIUM  
 Tel 016/332370  
 Fax 016/332367  
 e-mail: [ingemarie.moesen@uz.kuleuven.ac.be](mailto:ingemarie.moesen@uz.kuleuven.ac.be)