
A CASE OF SECONDARY FROSTED BRANCH ANGIITIS IN BEHÇET'S DISEASE

REYNDERS S., ^(*,**); DEWACHTER A., ^(*);
DE VRIESE A.S., ^(***)

SUMMARY

We report a case of Behçet's disease in a pregnant woman associated with secondary Frosted Branch Angiitis (FBA). FBA is a rare entity characterized by a florid translucent retinal perivascular sheathing of both arterioles and venules, with variable uveitis, retinal oedema and visual loss. To our knowledge, this is the first published report of FBA secondary to Behçet's disease in pregnancy.

KEY WORDS

Behçet, frosted branch angiitis, retinal vasculitis, uveitis

MOTS-CLÉS

Behçet, frosted branch angiitis, vasculite rétinienne, uvéite

RÉSUMÉ

Nous rapportons le cas d'une femme enceinte, atteinte de la maladie de Behçet en association avec un tableau clinique de Frosted Branch Angiitis (FBA) secondaire. FBA est une maladie rare qui se caractérise par un engainement périvasculaire translucide des vaisseaux rétiniens en association avec une uvéite variable, un œdème rétinien et une perte visuelle. A notre connaissance ce cas clinique est le premier cas publié de FBA dans la maladie de Behçet, se manifestant pendant la grossesse.

.....

* AZ St-Jan, Ophthalmology Department, Bruges, Belgium

** University Hospital Ghent, Ophthalmology Department, Ghent, Belgium

*** AZ St-Jan AV, Department of internal medicine, Bruges, Belgium

received: 01.09.05

accepted: 20.10.05

INTRODUCTION

Behçet's disease is a chronic relapsing systemic inflammatory vasculitis of unknown origin (1). The disease has a worldwide distribution with a prevalence ranging from 1:10000 in Japan to 1:500000 in Western countries. Typical clinical features include oral and genital ulcers, uveitis and skin lesions (erythema nodosum, papulopustular lesions and acneiform eruptions), although virtually every organ system can be involved. Recurrent uveitis, which occurs in approximately 50 %, is a principal cause of major morbidity. Here we describe the, to our knowledge, first published report of frosted branch angiitis secondary to Behçet's disease.

MATERIAL AND METHODS

We performed a conductive search on Medline withholding only peer review articles and using the keywords: Frosted Branch Angiitis, Behçet, Uveitis, Vasculitis, Herpes.

CASE REPORT

A 26 weeks pregnant 31-year-old woman (G8P5A2) consulted with low back pain and high-grade fever (39 °C) since a few days. Clinical examination showed polygonal confluent surinfected ulcerations of the vulva, cervix and vagina. Papulopustular skin lesions were present in the abdominal region and on both feet. Underneath her dental prosthesis a large oral ulceration was visible. There was no significant medical history, except for recurrent oral aphthosis. Echography of the foetus showed normal growth and vital signs.

Peripheral blood count showed marked leucocytosis with 81 % neutrophils. Sedimentation rate and C-reactive protein were markedly elevated. ACE, immunoglobulins, auto-immune parameters and liver function tests were normal. There was no evidence of cellular or humeral immune deficiency. Blood cultures grew no organisms and serology for HSV, HIV and syphilis was negative. Biopsy of the lesions showed non-specific ulcers. Antigen detection and PCR were negative for Herpes simplex.

Based on the clinical signs, the diagnosis of a primary surinfected Herpes simplex with sepsis was suspected and intravenous aciclovir and ceftriaxone were given.

During the acute phase of her illness, the patient started complaining of blurred vision in both eyes. At presentation her visual acuity was 1/20 in the right eye and counting fingers in the left eye. *Biomicroscopy* showed a normal anterior segment without any signs of anterior uveitis. Pupillary reaction was normal. *Intraocular pressure* was 13mmHg at both eyes. *Fundus examination* (Figure A & B) showed symmetrical retinal vasculitis with perimacular oedema, scattered intraretinal haemorrhages, cotton wool spots and perivascular sheathing of both arterioles and venules. There was no vitritis or disk oedema. *Fluorescein angiography* (figure C & D) confirmed vasculitis with partial occlusion of venous and some arteriolar branches, vascular leakage and areas of retinal ischemia with intraretinal haemorrhages. *Electrophysiological tests* were not performed.

During the next few days the fever and skin lesions gradually improved. She had an uncomplicated vaginal delivery of a healthy child at 37 weeks of gestation. Repeated serology after 6 weeks for HSV (IgM, IgG) remained negative. Some months later she subsequently developed an oral ulceration that could not be attributed to pressure of the dental prosthesis.

Since the criteria for Behçet's disease (1) were met and alternative diagnoses were excluded, the presumptive diagnosis of Behçet's disease with associated secondary frosted branch angiitis was made. A positive HLA-B51 further supported the diagnosis.

In the absence of firm recommendations for treatment and taking into account the pregnancy and infectious complications, no oral steroids were given in the acute phase of her illness. As her general and ophthalmological condition improved after the delivery, no additional treatment was given at that time. The fundus lesions gradually resolved and at day 19 vision had improved to right eye: 6/10 and left eye: 2/10. Perimetry showed a partial central scotoma at the right eye and a complete central

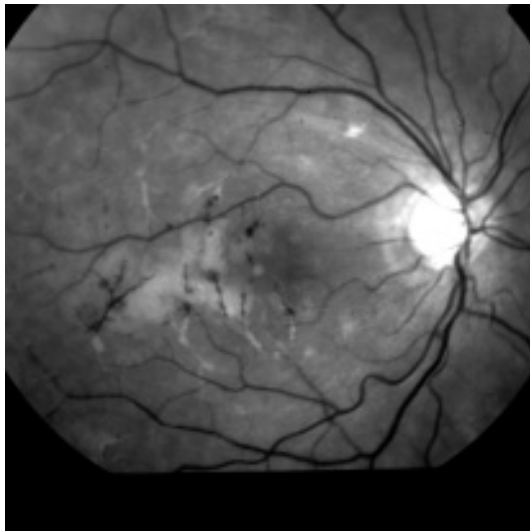


Figure A: Red-free picture of the right fundus

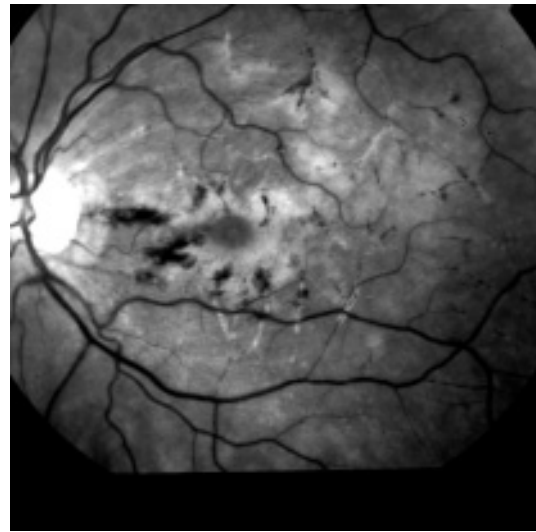


Figure B: Red-free picture of the left fundus

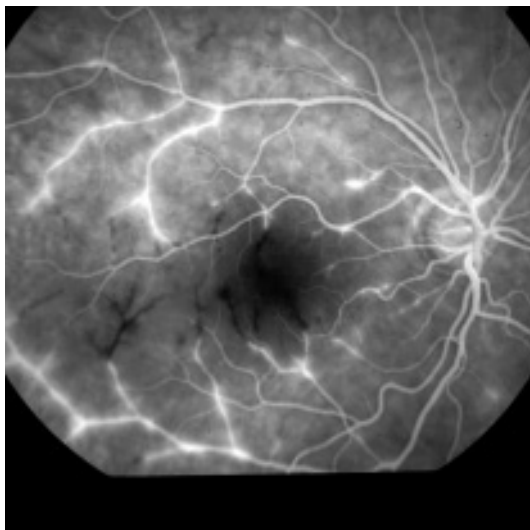


Figure C: Fluorescein Angiography of the right fundus

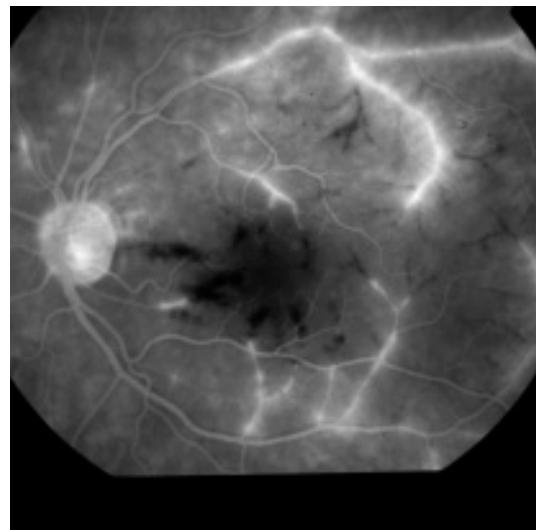


Figure D: Fluorescein Angiography of the left fundus

scotoma at the left eye. Repeated fluorescein angiography 3 weeks after delivery (14 weeks post-onset) revealed scattered retinal haemorrhages, alterations of the capillaries but no zones of manifest ischemia. There was no active inflammation. Vision had slightly dropped to right eye: 5/10 and left eye: <1/10. Six months later the fundus had the same appearance without any sign of neovascularisation.

DISCUSSION

The term "Frosted branch Angiitis" (FBA) was first described in 1976 by Ito *et al.* (2) in a child presenting with severe sheathing of all retinal vessels producing the appearance of frosted branches of a tree. It represents an acute panuveitis with severe vasculitis affecting the whole retina. Veins are usually slightly more involved than arteries. It is a rare disease with around 60 (5) cases reported in literature. The

entity usually affects young patients and is typical bilateral, although unilateral cases have been described. Women are slightly more involved than men. As proposed by Kleiner (3), the entity can be divided in 'primary idiopathic' and 'secondary' FBA.

The characteristic features of *primary idiopathic FBA* are (1) the severe sheathing of retinal vessels appearing like frosted branches of a tree in one or both eyes; (2) acute visual disturbance associated with signs of (mild) anterior chamber and (severe) vitreous inflammation; (3) fundus fluorescein angiography that demonstrates no occlusion or stasis of the sheathed vessels, but late staining and/or leakage along the vessels. Nevertheless, vessel narrowing or dilatation, areas of capillary non-perfusion and arteriovenous anastomoses can be noted in the angiogram; (4) otherwise healthy patients; (5) prompt response to corticosteroids; (6) typically no recurrence. It is now considered to be an immunological process in response to various infective antigens and responds well to corticosteroid treatment with an excellent recovery of visual acuity.

Secondary FBA is seen in patients with similar retinal appearances but with underlying diseases. They were classified into two subgroups. The first group includes patients with lymphoma or leukaemia where infiltration of malignant cells in retinal vessels can give a 'frosted branch-like appearance'. The second group is characterized by associated viral infections (HIV, CMV, Herpes⁽⁴⁾,...) or autoimmune diseases (SLE, Crohn's disease, Sarcoidosis,...) where FBA is thought to be a clinical sign due to immune complex deposition. This form is more resistant to treatment with worsening of the symptoms due to the underlying condition.

Capillary non-perfusion and neovascular glaucoma, macular scarring, retinal detachment and retinal neovascularization are the most severe complications in both subgroups. Nevertheless the prognosis is generally good with

prompt recovery of visual acuity after corticoid treatment in primary cases.

In conclusion, we report a case of secondary FBA to Behçet's disease. Initially we considered the retinal manifestations to be secondary to HSV2 and treated the patient as such. The diagnosis of HSV in this patient could not be confirmed by serology or PCR. The definite diagnosis was made some months after the acute illness when the patient developed a new oral ulceration. A positive HLA B5 supported the diagnosis. Our case confirms that FBA can be an acute manifestation of an underlying systemic disease. Exhaustive general investigation is mandatory before the FBA is considered to be idiopathic.

REFERENCES

1. INTERNATIONAL STUDY GROUP FOR BEHÇET'S DISEASE. Criteria for diagnosis of Behçet's disease. *Lancet* 1990; 335: 1078-80.
2. ITO Y., NAKONA M., KYU N., TAKEUCHI M. – FROSTED BRANCH ANGIITIS IN A CHILD. *JPN J CLIN OPHTHALMOL* 1976; 30: 797-803.
3. KLEINER R.C. – Frosted branch angiitis: clinical syndrome or clinical sign? *Retina*. 1997;17:370-1.
4. MARKOMICHELAKIS N.N., BARAMPOUTI F., ZAFIRAKIS P., CHALKIADAKIS I., KOURIS T., EKONOMOPOULOS N. – Retinal vasculitis with a frosted branch angiitis-like response due to herpes simplex virus type 2. *Retina*. 1999;19:455-7.
5. WALKER S., IGUCHI A., JONES N.P. – Frosted branch angiitis: a review. *Eye*. 2004 May;18:527-33.

.....

Adress for correspondence and reprints:

Dr. REYNDERS Stefaan
Department of Ophthalmology
UZ Ghent
De Pintelaan 185
B-9000 Ghent
Belgium
Email: dr.reynders@gmail.com