

ONE YEAR OF INTRAVITREAL INJECTIONS OF STEROIDS

DECKERS V., * PRIEM H. *,
VERBRAEKEN H.*

ABSTRACT¹

Purpose: Chronic macular oedema sometimes does not respond to classic treatment such as laserphotocoagulation, periocular and systemic steroids or carbonic anhydrase inhibitors. High dose intravitreal injection of steroids can be a valuable alternative in these patients.

Methods: Sixty-four eyes of 51 patients with chronic macular oedema, refractory to conventional treatments, received an intravitreal injection of 4 mg Kenacort® (triamcinolone acetonide). At postoperative controls (1 day, 1 month, 3 months, 6 months, 1 year), the visual acuity, intraocular pressure, central retinal thickness on OCT II were analyzed retrospectively.

Results: In the diabetic group, but also in cases of chronic uveitis, retinal vein thrombosis, birdshot chorioretinopathy, Irvine Gass syndrome, cellophane maculopathy and age-related macular degeneration with classic subfoveal neovascular membrane, dramatic decrease of the oedema was observed on funduscopy and OCT. A statistically significant reduction of mean central foveal thickness of 61% at 1 week and 49% at 3 months post-injection was demonstrated on OCT. Considerable gain in visual acuity was noted. The highest benefit in post-operative visual acuity was achieved after 3 months and averaged a gain of +3.55 Snellen lines (n=39). In 17% of eyes a rise in intraocular pressure was noted. Unfortunately we had one case of endophthalmitis in a poorly regulated diabetic woman. Six eyes were retreated because of recurrence of macular oedema.

Conclusion: Intravitreal injection of steroids can dramatically help in some cases of chronic macular oedema, not reacting to classic treatment. The injection should be performed under sterile conditions

since endophthalmitis is a potential risk. The most frequent complication seems to be a rise in intraocular pressure in cortisone responders.

RÉSUMÉ

Introduction: L'oedème maculaire chronique est souvent résistant aux traitements conventionnels tels que la photocoagulation au laser, les injections péribulbaires, l'administration systémique de stéroïdes ou d'inhibiteurs anhydrotiques d'acide carbonique (acétazolamide). L'injection intravitréenne de stéroïdes à haute dose peut être une alternative thérapeutique valable chez certains patients.

Méthodes: Dans cette étude rétrospective 64 yeux de 51 patients avec un oedème maculaire de longue durée ont été injectés avec 4 mg de Kenacort® (acétonide de triamcinolone). Aux contrôles post-opératoires (un jour, 1 mois, 3 mois, 6 mois et 1 an), l'acuité visuelle, la tension intra-oculaire, et l'épaisseur fovéolaire sur OCT II ont été étudiés.

Résultats: Une amélioration importante de l'oedème maculaire a été observée tant à l'examen du fond d'oeil qu'à l'OCT chez les patients diabétiques, ainsi que chez les patients atteints de thrombose de la veine centrale de la rétine, d'uvéite chronique, de retinohoroidopathie de type birdshot, de syndrome d'Irvine-Gass, de maculopathie cellophane ou de DMLA avec membrane néovasculaire sous-fovéale du type classique. L'épaisseur fovéolaire moyenne évaluée par OCT montre une diminution significative de 61% à 1 semaine et de 49% à 3 mois après injection. Un gain considérable d'acuité visuelle est obtenu. Le gain en acuité visuelle le plus important est vu à 3 mois après injection et s'élève à environs +3.55 lignes Snellen (n=39). Certains yeux (17%) ont présenté une élévation de la tension intra-oculaire. Malheureusement, une patiente avec un diabète difficile à contrôler, a développé une endophthalmie. La réapparition de l'oedème maculaire a nécessité une seconde injection à 6 yeux.

Conclusion: Les injections intravitréennes de corticoïdes peuvent améliorer considérablement l'oedème maculaire chronique résistant aux traitements classiques. L'injection doit être faite dans des condi-

.....

* Department of Ophthalmology, Ghent University Hospital, Ghent, Belgium

tions stériles car le risque d'endophtalmie est réel. La complication la plus fréquente semble être l'hypertonie oculaire.

SAMENVATTING

Doel: Klassieke therapieën voor chronisch maculair oedeem zoals laserfotocoagulatie, peri-oculaire en systemische steroïden of koolzuuranhydrase inhibitoren, geven niet altijd een bevredigend resultaat. Intravitreale toediening van een hoge dosis steroïden kan een waardevol alternatief zijn.

Methoden: In deze retrospectieve studie kregen 64 ogen van 51 patiënten met chronisch maculair oedeem een intravitreale injectie van 4 mg Kenacort® (triamcinolone acetonide). Bij de postoperatieve controles (1 dag, 1 maand, 3 maand, 6 maand en 1 jaar) werden visus, oogdruk en centrale retinadikte op OCT II gemeten.

Resultaten: Een drastische vermindering van het maculair oedeem werd opgemerkt zowel fundoscopisch als op OCT bij diabetici, alsook bij patiënten met een centrale veneuze occlusie, chronische uveïtis, birdshot chorioretinopathie, Irvine Gass syndroom, cellofaanmaculopathie, en leeftijdsgebonden maculaire degeneratie met klassieke subfoveale neovascularisatie. OCT toonde een statistisch significante vermindering van de gemiddelde centrale foveolaire dikte van 61% 1 week en 49% 3 maand na injectie. We zagen een aanzienlijke visusverbetering. De hoogste visuele winst werd bekomen 3 maand na injectie en bedroeg gemiddeld +3.55 Snellen lijnen (n=39). Enkele ogen (17%) vertoonden een verhoogde oogdruk. Spijtig genoeg ontwikkelde een moeilijk te regelen diabetica een endoftalmitis. Zes ogen kregen een tweede intravitreale injectie na recidief van het maculair oedeem.

Besluit: Intravitreale steroïdinjecties kunnen een drastische verbetering geven van het chronisch maculair oedeem in gevallen die niet reageren op klassieke therapie. De injectie dient te worden toegediend in steriele omstandigheden gezien het risico van endoftalmitis. De voornaamste complicatie lijkt een verhoogde oogdruk te zijn bij corticoïd responders.

KEY WORDS

macular oedema, triamcinolone, retinal thickness, endophthalmitis, increased intraocular pressure

MOTS-CLÉS

oedème maculaire, triamcinolone, épaisseur fovéolaire, endophtalmie, élévation de la tension intra-oculaire

INTRODUCTION

Chronic macular oedema in diabetes, retinal vein thrombosis and chronic uveitis sometimes does not respond to conventional treatment such as laserphotocoagulation, periocular and systemic steroids or carbonic anhydrase inhibitors. A damaged blood-retinal barrier can cause the capillary leakage in macular oedema (6). It has been known for many years that corticosteroids can suppress intraocular inflammation by reducing the traffic of inflammatory cells and exudation and by inhibiting proliferation of fibroblasts (5). The efficacy of intravitreal triamcinolone injection might be explained by the significant reduction in blood-retinal barrier breakdown and the decrease of VEGF production, a known vascular permeability factor (2, 11). High-dose intravitreal injection of steroids could be a valuable alternative in patients with chronic macular oedema. We present the results of one year of intravitreal triamcinolone injections in our department.

MATERIAL AND METHODS

We conducted a retrospective study. Fifty-one patients with chronic macular oedema were included: 26 men and 25 women received one or two intravitreal injections of 4 mg triamcinolone (Kenacort®) in one or both eyes. Sixty-four injections were performed.

The mean age of the patients was 63,8 years at the time of injection. The majority of eyes were phakic. The ratio phakic/pseudophakic eyes was 43:8. The mean follow-up was 4.5 months. Indication for treatment was diabetic retinopathy with chronic macular oedema in almost half of our group of patients (49%, 25 patients). The other main group of patients had chronic macular oedema caused by central or branch retinal vein occlusion (29%, 15 patients). The others had chronic uveitis (10%, 5 patients), birdshot chorioretinopathy (6%, 3 patients), Irvine-Gass syndrome (2%, 1 patient) or age-related macular degeneration with a subfoveolar choroidal neovascularisation-classic type (2%, 1 patient). One patient had a cellophane maculopathy (2%)(Fig 1). Six eyes received a second injection at different inter-

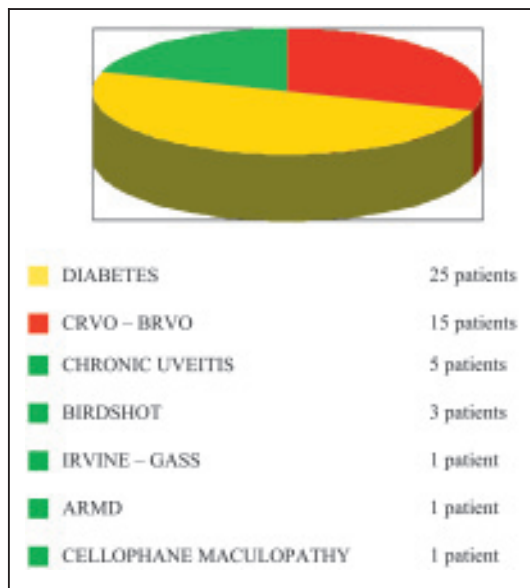


Fig. 1: Indications for treatment and number of patients included.

vals after the first one (two patients after 7-months, two after 10-, and two after 11-months).

PREVIOUS TREATMENT

All patients previously had maximal conventional treatment for macular oedema. In 32 patients laser photocoagulation had been performed (63%). Three patients had received topical steroids before the injection (6%). Six patients have had a subconjunctival or subtenon-al steroid-injection (12%). Some patients needed systemic drugs for their ocular and /or systemic disease: methylprednisolone was taken on a chronic base by 4 patients (8%), cyclosporine by 3 patients (6%). Three other patients used acetazolamide (6%).

PROCEDURE

The injection was performed under strict sterile conditions in the operating theatre. After skin disinfection with povidone-iodine, sterile draping, instillation of povidone-iodine in the fornices for 3 minutes, lid speculum positioning and topical anesthesia with Xylocaine 2%®, 4 mg of Kenacort®(triamcinolone acetonide) were injected intravitreally at 3 mm from the limbus

(in pseudophakia) or 3.5 mm (in phakic patients). Patency of the arteria centralis retinae was controlled by indirect ophthalmoscopy. An anterior chamber tap was performed in 2 eyes. No tap was performed in the patient that developed endophthalmitis. After injection, patients had to respect 2 hours of bedrest. All patients were outpatients and left the hospital after a routine clinical examination (including measurement of the intraocular pressure). During 5 days post-injection the patients were instructed to use topical quinolone collyrium (Ciloxan®) 4 times a day.

FOLLOW-UP

Patients were seen on a regular base (at 1 week, 1 month, 3 months, 6 months, 9 months and 1 year). Fifty-six patients have had a control after 1 week, 48 patients after 1 month, 39 patients were seen after 3 months, 25 patients had a follow-up of 6 months, 16 patients of 9 months, and 11 patients have had a control up to 1 year (5 patients with only one and 6 with a first and second injection included). At each control a complete ophthalmological examination was performed including visual acuity measurement, slitlamp biomicroscopy, Goldmann applanation tonometry and ophthalmoscopy. An OCT II was also performed. We measured the changes in retinal thickness at the level of the central foveal depression.

STATISTIC ANALYSIS OF RESULTS

Mean visual acuity was calculated using the logarithmic transformation of decimal visual acuity data into LogMAR units (decimal logarithm of the Minimum Angle Resolution). We used the Bonferroni post hoc test for the analyses of the reduction in mean retinal thickness found by OCT.

RESULTS

The response to treatment was monitored functionally by visual acuity assessment and anatomically by OCT measurement of macular thickness.

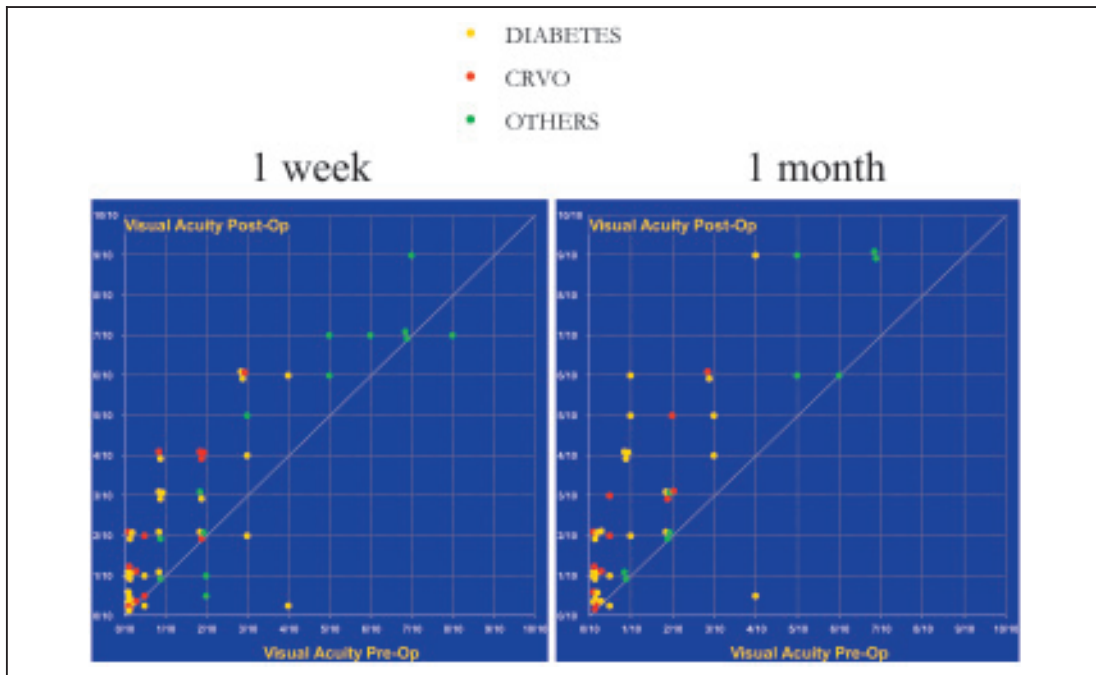


Fig. 2: Compares the pre-injection visual acuity with visual acuity after respectively 1 week and 1 month. Points above the line indicate improvement, while points below indicate deterioration. Each point represents one eye.

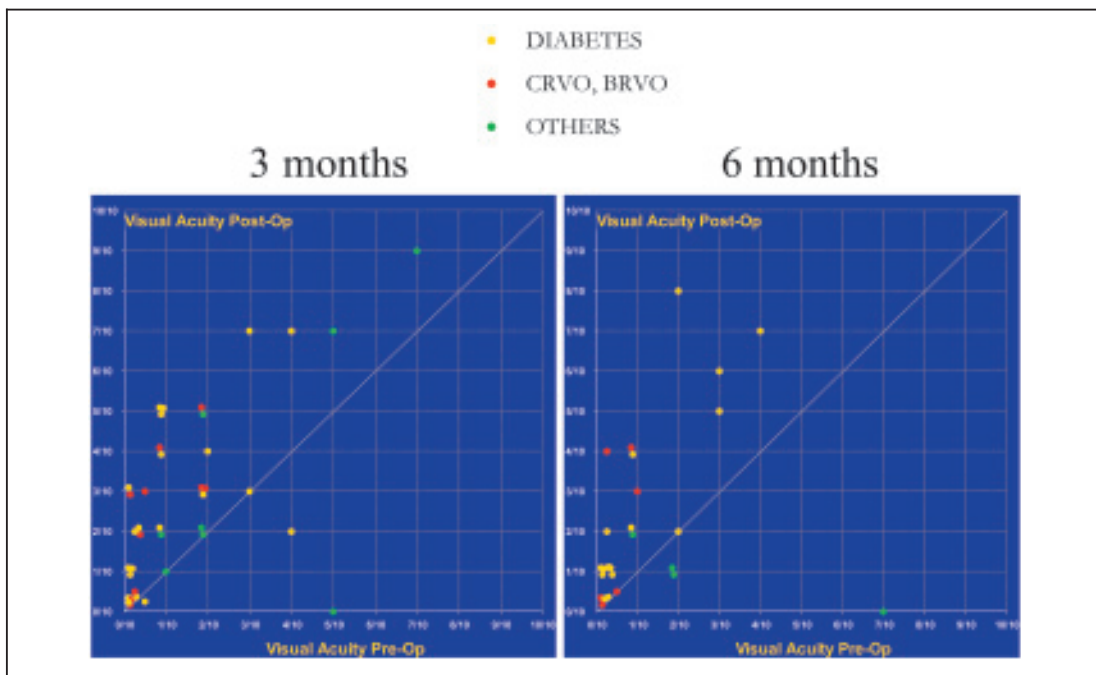


Fig. 3: Compares pre-op visual acuity with visual acuity at respectively 3 month and 6 month. Points above the line indicate improvement, while points below indicate deterioration.

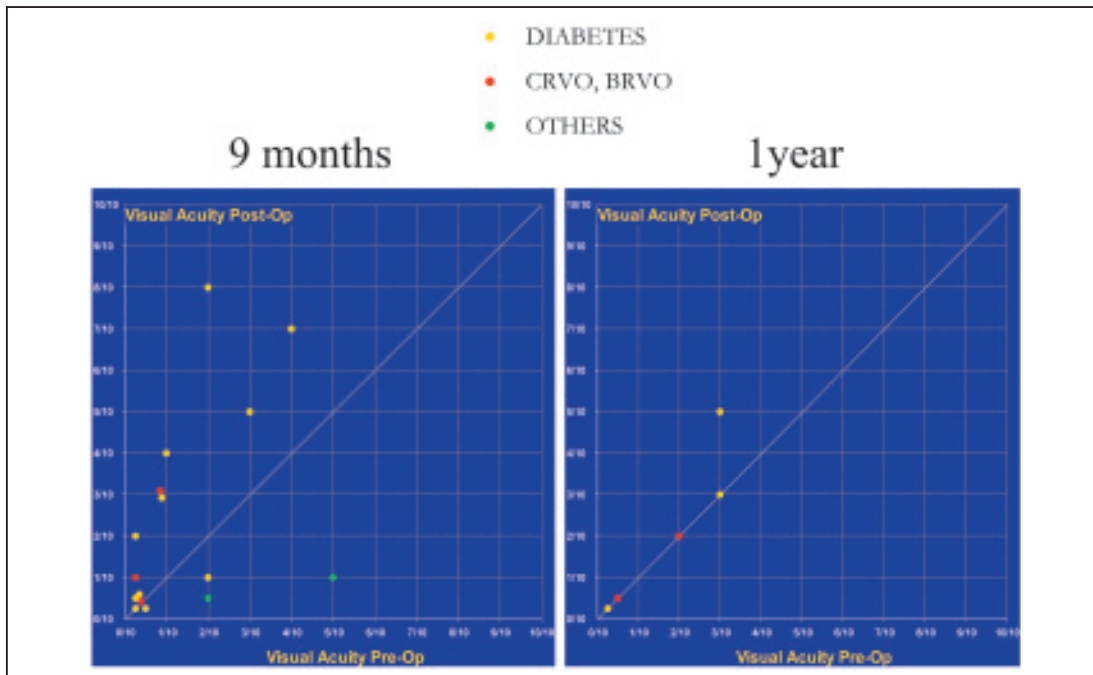


Fig. 4: Visual acuity at 9 month and 1-year examination is compared to visual acuity pre-injection. Points above the line indicate improvement, while points below indicate deterioration.

VISUAL ACUITY

We compared the initial visual acuity and the visual acuity at 1 week, 1 month, 3 months, 6 months, 9 months and 1 year post-injection of triamcinolone. Often a considerable gain in visual acuity was seen. Even within the first week post-injection (Fig 2) an important number of eyes had an average gain of +2.19 Snellen lines ($n = 56$). This beneficial trend persisted 1 month, 3 months and 6 months post-injection (Fig 2,3). An average improvement in visual acuity of +3.39 Snellen lines ($n = 48$) was noted after 1 month. The visual acuity gain averaged +3.55 Snellen lines at 3 month ($n = 39$). A gain of +2.93 Snellen lines was noticed at 6 month ($n = 25$). After 6 months, (Fig 4) visual acuity dropped slowly to the pre-injection level: at 9 month the visual acuity gain averaged +1.28 Snellen lines ($n=16$), at one year the average gain was +0.4 Snellen line ($n=5$). However, we have to emphasize that we have only small number of eyes who have had a follow-up of 1 year (5 eyes, second injection not included). Only one eye had a loss of visu-

al acuity at the end of follow-up. Six eyes received a second injection on different intervals after the first one (two eyes after 7-months, two other ones after 10-, and two 11-months after the first treatment).

OPTICAL COHERENCE TOMOGRAPHY

Reduction of the intensity of oedema and decrease of the central retinal thickness is seen on OCT in all eyes (Fig 5). We confronted the average retinal thickness on OCT in the central fovea towards the time post-injection. Only for the 3 first months we noticed statistically significant differences (Fig 6a). When we analyse only these statistical significant data of the 3 first months we remarked that even 1 week after treatment mean retinal thickness was diminished (from $588.8 \pm 31.61 \mu\text{m}$ ($n = 27$) preoperatively to $361.0 \pm 17.35 \mu\text{m}$ ($n = 27$) after 1 week ($p < 0.001$)). Retinal thickness further significantly decreased to $289.6 \pm 13.91 \mu\text{m}$ at 3 months ($n = 27$, $p > 0.05$ one week towards 3 months after injection). At no time a significant difference between the pre-

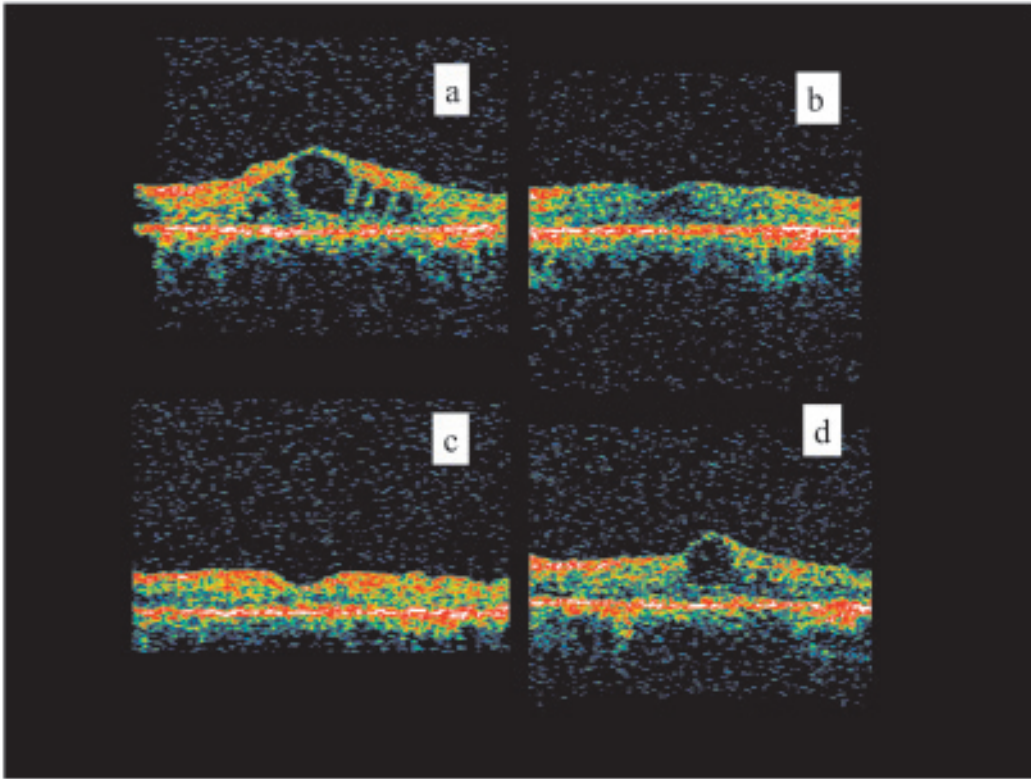


Fig. 5: Specific case example. a) OCT cross-section before intravitreal injection of triamcinolone acetonide showing macular oedema with development of large cystoid spaces. b) OCT cross-section 1 week and c) 3 month post-treatment. Chronic macular thickening and cystoid spaces resolved completely. Macular oedema remains controlled and vision remains stable. d) OCT cross-section 1 year after treatment showing relapse.

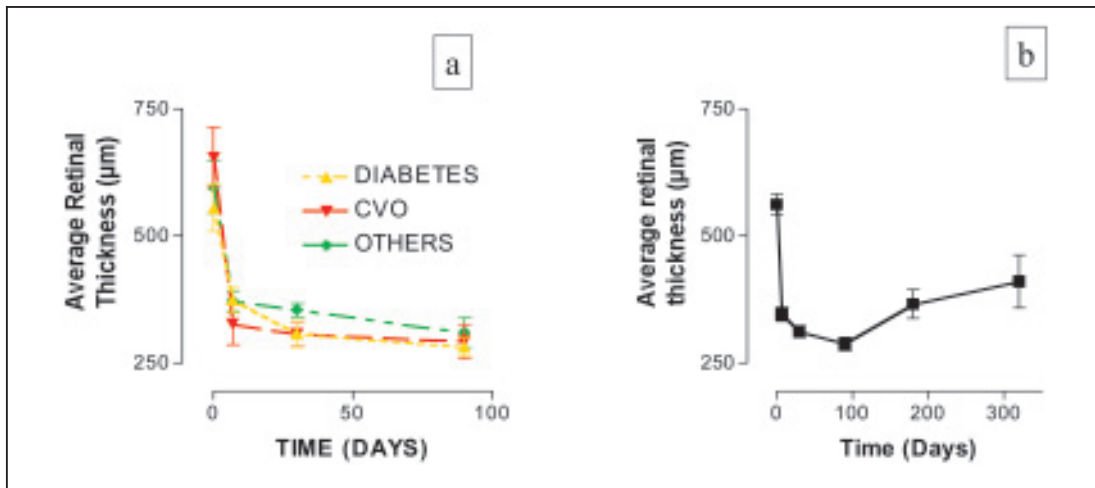


Fig. 6a: Evolution of mean central retinal thickness measured on OCT II in the first 3 month post-injection. Significant reduction is seen even after 1 week and further diminished till 3 month. No significant difference is found between the subpopulations (diabetes, vein occlusion and others).

6b: Evolution of mean central retinal thickness measured on OCT II when studying all the data post-injection.

mentioned subpopulations (diabetes, retinal vein occlusions and others) was observed. When we study all the data from 1 week to 1 year post-injection (Fig 6b) we also observed a clear decrease of the mean retinal thickness from $562.2 \pm 20.45 \mu\text{m}$ ($n = 49$) after 1 week to $346.3 \pm 12.89 \mu\text{m}$ ($n = 53$) after 1 month. The average retinal thickness diminished gradually till 3 months after injection ($287 \pm 12.38 \mu\text{m}$ ($n = 31$)) but then slowly increased again.

Recurrence of macular oedema was seen in 15 eyes (23%) in the present study and occurred at a mean time of 7,3 months.

INTRAOCULAR PRESSURE

Eleven eyes experienced an intraocular pressure rise after injection of triamcinolone acetonide (17%). Ten eyes were treated with anti-glaucomatous collyria and intraocular pressure returned to a normotensive level. One eye needed a diode laser cyclodestruction because of an intraocular pressure of 40 mmHg.

CATARACT

In one eye we suspected a progression of cataract after intravitreal injection of triamcinolone.

ENDOPHTHALMITIS

Unfortunately a diabetic woman with a glycaemia difficult to control developed an endophthalmitis after a second triamcinolone-injection (7 months after the first injection). We performed a diagnostic vitrectomy and *Staphylococcus aureus* was cultured from the vitreous sample. Patient recovered and we could save the eye.

DISCUSSION

Macular oedema is a major cause of severe visual impairment in patients with intraocular inflammatory disease (15). To suppress intraocular proliferation of cells Machemer (5) suggested the use of intravitreal injections of crystalline cortisone. The known antiphlogistic and antiangiogenic effects of triamcinolone were experienced in previous studies. The present study confirms the results of previous investigations (1,2,5,7-13) on the use and side effects of tri-

amcinolone for treatment of chronic macular oedema resulting from conditions such as diabetic retinopathy, central or branch retinal vein occlusion, chronic uveitis, birdshot chorioretinopathy, Irvine-Gass syndrome, cellophane maculopathy or age-related macular degeneration with classic subfoveal choroidal neovascularisation. Positive anatomic and functional results are universally apparent at the first month posttreatment interval and persist through three months of follow-up (11). The highest benefit in post-op visual acuity is achieved 3 months after injection. Beer et al (1) suggested that, assuming that the entire drug will be gone after 5 half-life's, measurable triamcinolone concentration in the vitreous should persist for 3 months in eyes who had not undergone vitrectomy. They also emphasized a considerable intrasubject variation among peak concentration and elimination half-lives. In the study of Jonas et al (9) postoperative visual acuity was highest 1-3 months after injection. Visual acuity significantly decreased towards 6 months of the follow-up period parallel with the disappearance of the triamcinolone acetonide crystals out of the vitreous cavity; however in this study 25 milligram of triamcinolone acetonide was injected intravitreally instead of 4 milligram in the current study group.

Optical Coherence Tomography (OCT) permits an objective and quantitative anatomic evaluation. In the present study statistically significant reduction of mean retinal thickness in the central fovea is found for the first 3 months after injection. A 61.3 % reduction in foveal thickness is noticed after 1 week. The retinal thickness further decreases to 49 % at 3 months. After 3 months a gain of retinal thickness is seen. These findings fit with data found in the study of Martidis (11) where respectively 55%, 57.5% and 38% reduction of central macular thickness was measured by OCT at 1-, 3- and 6- months. In all but one eye, we could correlate the OCT findings with gain in visual acuity. Reduction of the intensity of oedema and decrease of the central retinal thickness was, however, seen on OCT in all eyes.

Martidis et al (11) reported a recurrence of oedema after 6 months and reinjection was performed in 3 of the 8 eyes. In the current study 6 eyes were reinjected (10%). The anatomic benefit seen on OCT after the first injection

seems to be the same after a second injection. However, the functional effect of reinjection is not conclusive. We could not deduce any statement because of the too short follow-up and the relative small sample size in this category of patients. Jonas et al.(9) showed a re-increase in visual acuity in 50% about 1 month after the reinjection. After about 3 months visual acuity declined again. In the same study one patient received a third injection 5.7 months after the second injection. After initial improvement in visual acuity, visual performance slightly deteriorated again. The authors bring up for discussion one of the main questions in that matter, namely whether and how many applications of triamcinolone acetonide can be tolerated by the eye (9). Based on data of Mc Gillies et al (4), it would appear that increased risk of adverse events is not found if a second injection is given 8 or more months after the first. Potential corticosteroid-induced and injection-related complications are observed. The major ocular side effects attributed to corticosteroids include glaucoma and cataract (11). Secondary ocular hypertension after intravitreal injection of corticosteroids is reported in about 30-50% of the eyes treated (6,7,14). The rise of intraocular pressure is reversible at about 6 months after injection. In all but one of the 75 eyes enrolled in the study by Jonas et al(6) no glaucomatous changes of the optic disc were found. The authors conclude that steroid induced hypertension may not be a major contraindication against the use of triamcinolone as treatment of macular oedema. However, repeated intravitreal injections may lead to steroid-induced secondary open-angle glaucoma necessitating trabeculectomy (8). Cataract as treatable complication is suggested not to be a contraindication for the use of intravitreal steroid-injection in patients not reacting to conventional therapy (9). Potential injection-related complications include retinal detachment, vitreous hemorrhage, lens touch and endophthalmitis. Endophthalmitis after intravitreal injection is unusual. A case of endophthalmitis after intravitreal injection of triamcinolone is reported (3). Here also it concerned a diabetic patient. Endophthalmitis was caused by *Mycobacterium chelonae* abscessus. The patient underwent enucleation of the involved eye. This dramatic case illustrates

the deleterious effect of corticosteroids on mycobacterial infections. The authors advise close follow-up in these patients with a immunosuppressed intraocular status (3). Other potential injection-related complications were fortunately not seen in the current study group.

CONCLUSION

The promising but temporary benefit of intravitreal injections of triamcinolone is confirmed in the present study. They dramatically help in cases of chronic macular oedema not responding to classic treatment. Results showed prompt resolution of oedema with corresponding improvement in visual acuity.

The potential side effects of intravitreal corticosteroids may be acceptable given the risk of irreversible visual loss from untreated chronic macular oedema. The injection should be performed under strict sterile conditions since endophthalmitis is a possible risk. Another major complication seems to be the rise in intraocular pressure in steroid responders. Because of this, we must remain very careful in the selection and follow-up of patients when we consider this kind of treatment.

ACKNOWLEDGEMENTS

The authors wish to acknowledge Prof. Dr. J.J. De Laey, Prof.Dr. C. Delaey, Dr. M. Van Lint, Dr. B. Leroy and last but not least Miss. C. Reynaert for the expert assistance and help in bringing this study to a good end.

This study was supported by a grant of "Les Amis des Aveugles" (Ghlin, Belgium).

REFERENCES

- (1) BEER P.M., BAKRI S.J., SINGH R.J. – Intraocular concentration and pharmacokinetics of triamcinolone acetonide after a single intravitreal injection. *Ophthalmology*.2003; 110: 681-6.
- (2) BENHAMOU N., MASSIN P., HAOUCHINE B. – Intravitreal triamcinolone for refractory pseudophakic macular edema. *Am J Ophthalmol*.2003; 135:246-9.
- (3) BENZ M.S., MURRAY T.G., DUBOVY S.R. – Endophthalmitis caused by *Mycobacterium chelonae* abscess after intravitreal injection of triam-

- cinolone. Arch Ophthalmol. 2003; 121:271-3.
- (4) CHALLA J.K., GILLIES M.C., PENFOLD P.L. – Exudative macular degeneration and intravitreal triamcinolone 18 month follow-up. Aust N Z J Ophthalmol. 1998; 26:277-81.
 - (5) JONAS J.B., HAYLER J.K., SOFKER A. – Intravitreal injection of crystalline cortisone as adjunctive treatment of proliferative diabetic retinopathy. Am J Ophthalmol. 2001; 131:468-71.
 - (6) JONAS J.B., KREISSIG I., DEGENRING R. – Intraocular pressure after intravitreal injection of triamcinolone acetonide. Br J Ophthalmol. 2003; 87:24-7.
 - (7) JONAS J.B., KREISSIG I., DEGENRING R.F. – Intravitreal triamcinolone acetonide for pseudophakic cystoid macular edema. Am J Ophthalmol. 2003; 136:384-6.
 - (8) JONAS J.B., KREISSIG I., DEGENRING R. – Secondary chronic open-angle glaucoma after intravitreal triamcinolone acetonide. Arch Ophthalmol. 2003; 121:729-30.
 - (9) JONAS J.B., KREISSIG I., HUGGER P. – Intravitreal triamcinolone acetonide for exudative age related macular degeneration. Br J Ophthalmol. 2003; 87:462-8
 - (10) JONAS J.B., SOFKER A., DEGENRING R. – Intravitreal triamcinolone acetonide as an additional tool in pars plana vitrectomy for proliferative diabetic retinopathy. Eur J Ophthalmol. 2003; 13:468-73.
 - (11) MARTIDIS A., DUKER J.S., GREENBERG P.B. – Intravitreal triamcinolone for refractory diabetic macular edema. Ophthalmology. 2002; 109:920-7.
 - (12) MARTIDIS A., DUKER J.S., PULIAFITO C.A. – Intravitreal triamcinolone for refractory cystoid macular edema secondary to birdshot retinochoroidopathy. Arch Ophthalmol. 2001; 119:1380-3.
 - (13) NELSON M.L., MARTIDIS A. – Managing cystoid macular edema after cataract surgery. Curr Opin Ophthalmol. 2003; 14:39-43.
 - (14) WINGATE R.G., BEAUMONT P.E. – Intravitreal triamcinolone and elevated intraocular pressure. Aust N Z J Ophthalmol. 1999; 27:431-2.
 - (15) YOUNG S., LARKIN G., BRANLEY M. – Safety and efficacy of intravitreal triamcinolone for cystoid macular oedema in uveitis. Clin Experiment Ophthalmol. 2001; 29:2-6.

*Address for correspondence and reprints:
Dr.V.DECKERS,
Dienst Oogheelkunde, UZ Gent,
De Pintelaan 185, B-9000 Gent*