

NEEDLING-REVISION OF FAILED FILTERING BLEBS

JACOBS S. *, GILLIS A. **,
VAN MALDEREN L. *, ZEYEN T. *

ABSTRACT:

Purpose: To investigate the efficacy and safety of needling-revision of failed blebs after trabeculectomy.

Methods: A retrospective chart review of 28 eyes of 28 patients who underwent a trabeculectomy with subsequent needling-revision between January 2002 and December 2003.

The mean follow-up was 15 months after the first needling-revision. All interventions were conducted by the same surgeon. Absolute success was defined as an IOP <18 mmHg without medication or as an IOP reduction >20% **without** medication if the preoperative IOP was \leq 21 mmHg. Relative success was defined as meeting these criteria **with or without** medication.

Results: The mean interval between trabeculectomy and the first needling-revision was 5 months. Repeated needling-revision (up to 3 times) was performed as clinically necessary. In 90% of the needling-revisions 5-FU was used to prevent postoperative fibrosis.

The mean \pm SD IOP before needling-revision and at the last follow-up was respectively 24.7 ± 6 and 15.7 ± 3 mmHg ($p < 0.001$)

Needling-revision was an absolute success in 39% (11/28) and a relative success in 68% (19/28).

Minor complications attributed to needling-revision occurred in 32% including self reabsorbing subconjunctival bleeding (1), filamental (1) and punctate keratitis (1), transient choroidal effusion (3), wound leak (4) and hyphaema (2). Progression of cataract occurred in 1 patient. A serious complication occurred in 1 case (hypotony with persistent macular oedema).

.....

* Department of Ophthalmology, University Hospital, Leuven

** Department of Ophthalmology, Middelheim Hospital, Antwerp

received: 03.06.05
accepted: 22.08.05

Conclusions: Bleb needling-revision can prevent more invasive intervention in a significant number of patients with failed trabeculectomy blebs. Complications are similar to those seen after trabeculectomy.

RÉSUMÉ:

Propos: Investiguer l'efficacité et la sécurité d'une révision par needling de bulles de filtration non-fonctionnelles après trabéculéctomie.

Méthodes: Une étude rétrospective de 28 yeux de 28 patients ayant subi une trabéculéctomie et suivie par une révision par needling entre janvier 2002 et décembre 2003. Le suivi moyen était de 15 mois après la première révision. Toutes les interventions ont été effectuées par le même chirurgien. Un succès absolu était défini comme une PIO < 18 mmHg sans médicaments ou une réduction >20% si la PIO préopératoire était \leq 21 mmHg **sans** médicaments. Un succès relatif était défini selon les mêmes critères **avec ou sans** médicaments.

Résultats: L'intervalle moyen entre la trabéculéctomie et la première révision par needling était de 5 mois. Une révision par needling fut répétée si nécessaire (jusqu'à trois fois). Du 5-FU était utilisé dans 90% des révisions par needling. La PIO moyenne avant la révision par needling était de 24.7 ± 6 mmHg et lors du dernier contrôle postopératoire de 15.7 ± 3 mmHg ($p < 0.001$). La révision par needling était un succès absolu dans 39% (11/28) et un succès relatif dans 68% (19/28).

Des complications mineures attribuées aux révisions par needling sont apparues dans 32% des cas, incluant une hémorragie sous-conjonctivale (1), une kératite filamenteuse (1) et ponctuée (1), un décollement choroïdien temporaire (3), un Seidel positif (4) et un hyphéma (2). On a observé une progression de la cataracte chez un patient. Une complication sérieuse (hypotonie avec persistance d'œdème maculaire) est également survenue.

Conclusion: Une révision par needling d'une bulle de filtration non-fonctionnelle après trabéculéctomie peut éviter une intervention plus invasive chez un

grand nombre de patients. Les complications sont les mêmes qu'après une trabéculéctomie

SAMENVATTING

Doel: De efficiëntie en veiligheid van needling-revisie van falende blebs na trabéculéctomie nagaan.

Methode: Een retrospectieve studie van 28 ogen van 28 patiënten die een trabéculéctomie met daaropvolgende needling-revisie ondergingen tussen januari 2002 en december 2003. De gemiddelde follow-up was 15 maanden na de eerste needling-revisie. Alle operaties werden door dezelfde chirurg uitgevoerd. Absoluut succes werd gedefinieerd als een intra-oculaire druk < 18 mmHg zonder medicatie of als een drukverlaging van >20% als de pre-operatieve intra-oculaire druk \leq 21 mmHg was, en als deze druk bereikt werd **zonder** medicatie. Relatief succes werd gedefinieerd volgens dezelfde criteria en als de druk bereikt werd **met of zonder** medicatie.

Resultaten: Het gemiddelde interval tussen trabéculéctomie en de eerste needling-revisie was 5 maanden. De needling-revisie werd herhaald (tot drie keer) wanneer dit klinisch nodig werd geacht. In 90% van de needling-revisies werd 5-FU gebruikt om de ontwikkeling van postoperatieve fibrose te voorkomen. De gemiddelde intra-oculaire oogdruk \pm SD voor de needling-revisie en bij de laatste contole was respectievelijk 24.7 ± 6 en 15.7 ± 3 mmHg ($p < 0.001$). Needling-revisie was een absoluut succes bij 39% (11/28) en een relatief succes bij 68% (19/28).

Kleine complicaties te wijten aan de needling-revisie kwamen voor bij 32% onder meer zelfresorbende subconjunctivale bloeding (1), filamenteuze (1) en punctata keratitis (1), transiënte choroidale effusie (3), wondlekkage (4) en hyfema (2). In 1 patiënt was er progressie van de cataract. Er was 1 ernstige complicatie (hypotonie met persisterend maculair oedeem).

Conclusie: Bleb needling-revisie kan een meer invasieve interventie voorkomen in een significant aantal patiënten met falende trabéculéctomie blebs. De complicaties zijn te vergelijken met de complicaties gezien na trabéculéctomie.

KEY WORDS

Glaucoma, Trabéculéctomy, Intraocular pressure, Needling-revision, Failed filtering bleb, 5-Fluorouracil

MOTS-CLÉS

Glaucome, Trabéculéctomie, Pression intra-oculaire, Révision par needling, Bulles de filtration non-fonctionnelles, 5-Fluorouracil

INTRODUCTION

Despite good bleb management between 2.1% and 6.2% (2,8,9,12) of the trabéculéctomy blebs fail.

A failed bleb is a bleb that shows suboptimal filtration because of scarring of the subconjunctival and intrascleral passage with insufficient lowering of the intraocular pressure (IOP) (1,12-14). It appears typically a few weeks after the operation after initial good function. A failed bleb is to be differentiated from an encapsulated or cystic bleb where the conjunctiva forms a dome-shaped fibrotic wall with cavities that entrap aqueous humour. An encapsulated bleb can contain sufficient functional areas of filtration thus the IOP is not always elevated (3).

Many patients who underwent filtering eye surgery already showed insufficient response to IOP lowering topical medications; this is why increasing the surgical success rate is so important. A careful management of the postoperative period increases the success rate (4,6,8,10). A failed bleb can be treated in two ways: a surgical bleb revision or a needling-revision. Surgical bleb revision gives more scarring than needling-revision and usually the effects are short-term (1,10). Needling-revision is less traumatic and only minimal scar formation is triggered (13).

With a needling-revision one performs a surgical section of the scar tissue formed at the filtering site. Additional injection of 5-Fluorouracil (5-FU) may prevent formation of new scar tissue (4,10,13-15). The concept of this technique was first introduced in 1985 (11) and showed variable success; the exact method varies from surgeon to surgeon (4,7,10,11,14). The attempt is to re-open the filtering site and cut the subconjunctival and intrascleral scar tissue.

METHODS

PATIENTS

A retrospective chart review of patients who underwent a needling revision procedure between January 2002 and December 2003 was conducted. All operations were performed by the same surgeon. The mean follow-up was 15 months. In patients in whom both eyes had un-

dergone a bleb needling-revision procedure, only one eye was randomly included. The past ophthalmic history was obtained with all previous surgery and laser treatments and current topical treatment being documented; the past surgical ocular history is summarized in Table 1. A failed bleb was defined by applanation tonometry and on the base of the morphologic features at slit-lamp examination. Gonioscopic examination excluded mechanical blockage of the trabeculectomy channel.

SURGICAL TECHNIQUE

The surgery was conducted in the operation room as an out-patient procedure. Repeated applications of a topical anaesthetic (Oxybutyprocaine 1%) were instilled to achieve local anaesthesia. Apraclonidine Hydrochloride 1% (Iopidine®) was used to blanch the conjunctival and episcleral blood vessels. The Hoskins lens was used to locate the borders of the scleral flap when necessary. The conjunctiva was entered with a 23 gauge 45° angulated MVR knife (BD Edgehead™ stiletto) superolateral to the bleb, at 10mm from the limbus. While advancing towards the scleral flap the knife with his cutting edge was moved very carefully towards the edge of the scleral flap, carefully avoiding perforation of the overlying tissues or laceration of blood vessels. The remaining sutures were cut (if present). The scleral flap was lifted with the knife until an effusion of aqueous humour was observed. If no effusion was seen the knife was further moved to enter the anterior chamber. The knife was withdrawn slowly. A different entry site was used to inject 0.1cc 5-fluorouracil (5-FU, 50mg/ml). The conjunctiva was not sutured. Postoperatively a combination of steroids and antibiotics were given (Tobradex®) for 3 weeks.

FOLLOW-UP PERIOD

At each post-needling visit the Snellen visual acuity was recorded and applanation tonometry, slitlamp examination and funduscopy with a 90D lens were performed. All complications considered to be a direct consequence of the needling procedure were recorded. Repeated needling was performed as clinically necessary and again based on the morphologic fea-

Table 1: 5-FU: 5-fluorouracil, MMC: Mitomycin-C

<i>Filtrating surgery</i>	<i>Number of patients</i>
Trabeculectomy	13
Trabeculectomy with 5-FU	4
Trabeculectomy with MMC	3
Phacotrabeculectomy	1
Phacotrabeculectomy with MMC	1
Trabeculectomy, second trabeculectomy with MMC	4
Phacotrabeculectomy, second trabeculectomy with 5-FU	1
Trabeculectomy with MMC, second trabeculectomy with MMC	1

tures of the bleb and applanation tonometry. The procedure was carried out in the same manner as the initial procedure. IOP lowering topical medications were given when repeated needling was not effective enough to obtain the target pressure.

OUTCOME MEASURES

The IOP and the number of topical glaucoma medications were compared before and at the last control after the needling revision procedure. The mean follow-up period was 15 months.

We determined the absolute and relative success rate. Success was defined as an IOP less than 18 mmHg or as an IOP-reduction of more than 20% if the preoperative pressure was 21 mmHg or less. Absolute success was defined as meeting these criteria without medication; relative success was defined as meeting these criteria with or without medication.

RESULTS

The study consisted of 28 eyes of 28 Caucasian patients with mean age of 61 years (range 33- 82). The mean follow-up period was 15 months (range 8-26). The mean follow-up period of the group which needed one needling revision was 14 months (range 8-26). The mean follow-up period of the group which needed multiple needling-revisions was 6.5 months after the last needling-revision (range 1-16). The mean interval between the trabeculectomy and the first needling-revision was 5 months (range 1-48) (Figure 1).

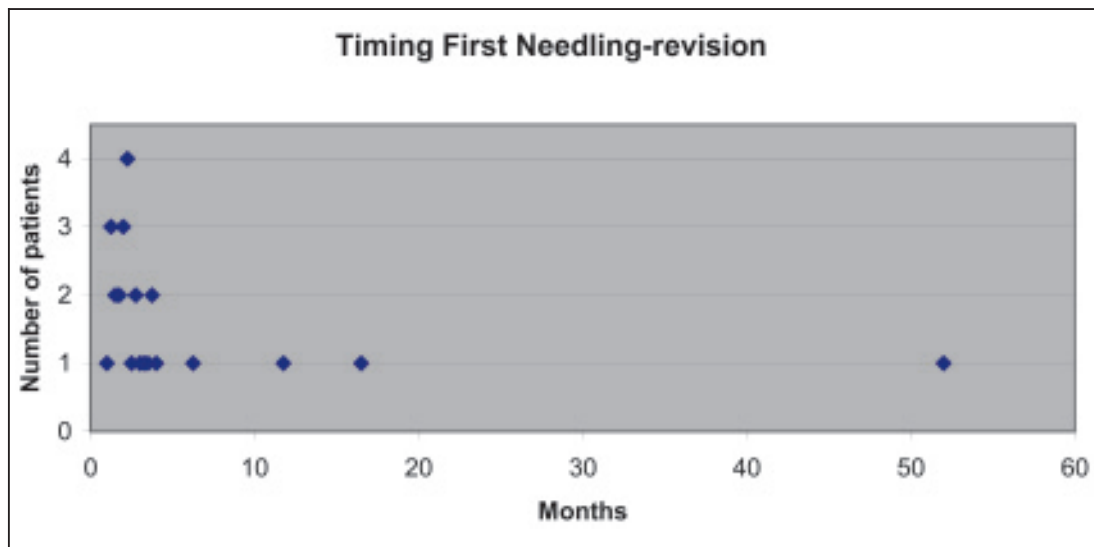


Figure 1: Time between trabeculectomy and first needling-revision

Repeated needling-revision was performed as clinically necessary; 5 patients needed a second needling-revision within 25 weeks (range 1-108) after the first needling-revision, 4 patients needed up to 3 needling-revisions within 6.25 weeks (range 3-11) after the second needling-revision.

Two patients underwent a needling-revision without additional 5-FU because of previous toxic keratitis to this anti-metabolite.

The mean IOP pre- and post-needling-revision was respectively 24.7 ± 6 mmHg and 15 ± 3 mmHg ($p < 0.01$ two tailed paired t-test).

The absolute success rate was 39% (11/28). The relative success rate was 68% (19/28). (Figure 2) In the subgroup of 5 patients who underwent a needling-revision more than 4 months after the trabeculectomy 3/5 (60%) were an absolute success, 4/5 (80%) were a relative success, 1/5 failed (20%) and needed a second trabeculectomy.

The mean number of glaucoma medications given before needling revision and at the last control was 0.5 and 0.8 respectively ($p = 0.3$ two tailed paired t-test)

Minor complications occurred in 32 % of the needling-revisions including a self reabsorbing subconjunctival bleeding (1/28), filamental keratitis (1/28), punctate keratitis (1/28), transient choroidal effusion (3/28), wound leak (4/28) and hyphaema (2/28).

Two more serious complications occurred (7%); one patient showed progression of cataract. Another patient developed hypotony with a flat anterior chamber and persistent macular oedema. This patient had twice a repair of the anterior chamber with viscoelastics and a bandage contact lens. There was a visual deterioration from 2/10 to light perception. In this study there were no patients who developed endophthalmitis.

DISCUSSION

Many methods for needling-revision of failed blebs have been described (1,4,5,7,10,13,14). We chose to use the 23 gauge angled MVR knife (BD Edgehead™ stiletto angled 45°) because there are no sutures required using this knife and the angle of the knife gives an easy approach to the subconjunctival and subscleral space. Other types of needles and knives are described (1,3-5,7,8,10) without additional benefits. The type of knife is the surgeons' choice. 5-FU was used in all cases (except in the two patients with previous adverse events to 5-FU) although some studies do not show additional effect using 5-FU (7).

Reported success rates for needling-revision procedures have been variable. Not all authors differentiate between needling and needling-revision procedures (needling is specifically used

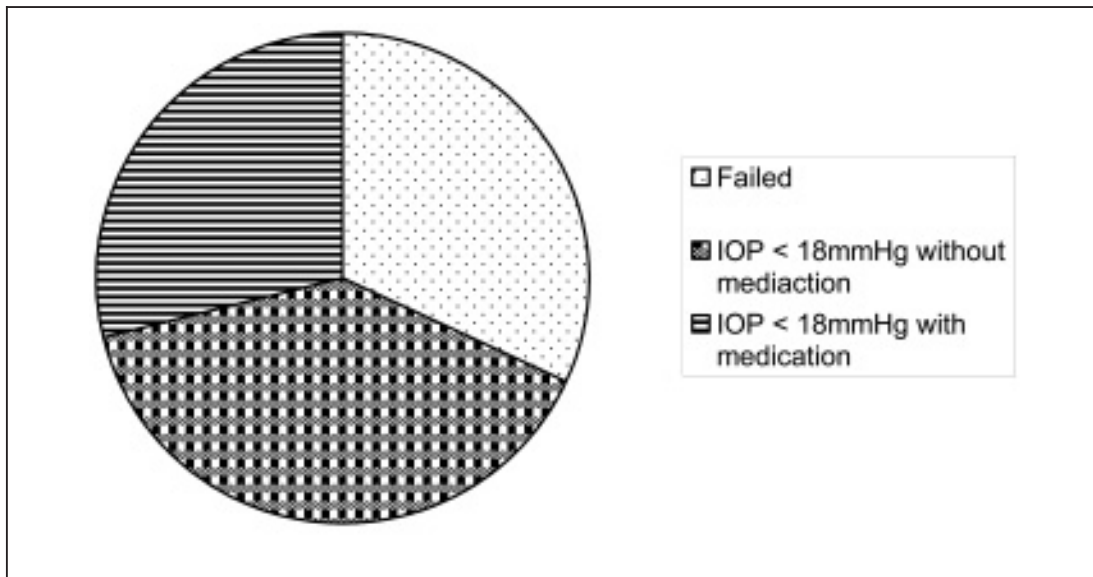


Figure 2: Success rates of needling-revision

in case of encapsulated blebs) and definitions of success vary. Overall success rates vary between 60 % and 80% (11,13,14). This is in accordance to our relative success rate of 68%. The success rate in the subgroup of patients who underwent a needling-revision more than 4 months after the trabeculectomy is comparable with the success rates of the whole group, the group is too small for statistical analysis. The length of the period where you can try a needling revision with significant chance for success, is unknown and needs to be further examined.

Factors of importance for failure of the needling-revision procedure previously reported include early post-trabeculectomy bleb failure, pseudophakia, previous surgery using a conjunctival incision, no use of anti-metabolites during the previous filtering eye surgery and a higher pre-needling IOP (13) Some of these risk factors were not statistically significant in a longer follow-up period (14). In this study the group of patients was too small to identify additional risk factors for needling-revision failure.

Most of the reported complications have been minor; the incidence of complications reported vary between 20% and 38% (1,14) and is comparable to our findings. Major complica-

tions reported include persistent significant hypotony, suprachoroidal haemorrhage, malignant glaucoma and endophthalmitis (4,10). We encountered one patient with severe persistent hypotony and macular oedema unresponsive to surgical repair.

CONCLUSION

Bleb needling-revision is an easy and repeatable procedure that can prevent a more invasive intervention in a significant number of patients with failed trabeculectomy blebs. However the complications are the same than those seen after trabeculectomy. The operation is performed at the same site of the trabeculectomy and thus preserves conjunctiva for a possible subsequent trabeculectomy if the needling-revision fails.

REFERENCES

- (1) BROADWAY, D., BLOOM, Ph., BUNCE, C., THIAGARAJAN, M., KHAW, P. – Needle revision of failing and failed trabeculectomy blebs with adjunctive 5-fluorouracil. *Ophthalmology* 2004; 111:665-673
- (2) BLONDEAU, P., PHELPS, C.D. – Trabeculectomy vs. thermosclerostomy. A randomized pros-

- pective clinical trial. Arch Ophthalmol 1981 99:810-816
- (3) FEYI WABOSO, A., EJERE HOD – Needling for encapsulated trabeculectomy filtering blebs. The Cochrane Database of systematic reviews 2004, issue 1. Art. No.: CD003658.pub2.DOI; 10.1002/14651858.
 - (4) GILLIES, W.E., BROOKS, A.M. – Restoring the function of the failed bleb. Aust N Z J Ophthalmol 1991; 19:49-51
 - (5) GREENFIELD, D.S., MILLER, M.P., SUNER, I.J., PALMBERG, P.F. – Needle elevation of the scleral flap for failing filtration blebs after trabeculectomy with mitomycin C. Am J Ophthalmol. 1996; 122:195-204
 - (6) HOSKINS, H.D. Jr, MIGLIAZZO, C. – Management of failing filtering blebs with Argon laser. Ophthalmic Surg 1984; 15:731-3
 - (7) MARIT FAGERLI, KJELL T., LOFORS, TOR EL-SAS – Needling revision of failed filtering blebs after trabeculectomy: a retrospective study. Acta Ophthalmol. Scand. 2003; 81:577-582
 - (8) MEYER, J.H., GUHLMANN, M., FUNK, J. – How successful is the filtering bleb “needling”? Klin Monatsbl Augenheilkd. 1997; 210:192-6.
 - (9) MILLS, K.B. – Trabeculectomy: a retrospective long-term follow-up of 444 cases. Br J Ophthalmol 1981 65:790-795
 - (10) PARIS, W., ZHAO, M., SPONSEL, W.E. – Operative revision of non-functioning filtering blebs with 5-fluorouracil to regain intraocular pressure control. Clin Exp Ophthalmol 2004; 32:378-382
 - (11) PEDERSON, J.E., SMITH, S.G. – Surgical management of encapsulated filtering blebs. Ophthalmology 1985; 92:955-8
 - (12) SKUTA, G.L., PARRISH, R.K. 2nd – Wound healing in glaucoma filtering surgery. Surv Ophthalmol. 1987; 32:149-70
 - (13) SHIN, D.H., JUZYCH, M.S., KHATANA, A.K., SWENDRIS, R.R., PARROW, K.A. – Needling revision of failed filtering blebs with adjunctive 5-Fluorouracil. Ophthalmic Surgery April 1993, 24, NO4 P 242-248
 - (14) SHIN, D.H., KIM, Y.Y., GINDE, S.Y., KIM, P.H., ELIASSIS-RAD, B., KHATANA, A.K., KEOLE, N.S. – Risk factors for failure of 5-fluorouracil needling revision for failed conjunctival filtration blebs. Am J Ophthalmol 2001; 132:875-80
 - (15) THE FLUOROURACIL FILTERING SURGERY STUDY GROUP – Fluorouracil Filtering Surgery Study one year follow-up. Am J Ophthalmol 1989 15; 108:625-35
-
- Reprints and Correspondence:*
Dr. JACOBS Sigrid
Prof. Dr. ZEYEN Thierry
Dept. of Ophthalmology
UZ Leuven campus Sint-Raphaël
Kapucijnenvoer 33
B-3000 Leuven
e-mail: Thierry.zeyen@uz.kuleuven.ac.be