

CLINICAL AND GENETIC SIGNIFICANCE OF UNILATERAL LISCH NODULES

CEUTERICK S.D.*; VAN DEN ENDE J.J.**;
SMETS R.M.E.*

ABSTRACT

Purpose: Bilateral Lisch nodules are highly characteristic for neurofibromatosis type 1 (NF1). We wished to study the clinical and genetic implications of unilateral Lisch nodules.

Methods: Retrospective study of the clinical data of 59 patients who received genetic counselling for neurofibromatosis type 1 (NF1) or type 2 (NF2) and were examined at the department of ophthalmology.

Results: Unilateral Lisch nodules were observed in 4 cases: one child with NF1 initially presented unilateral Lisch nodules but developed bilateral Lisch nodules by the age of 9. In 2 cases segmental NF1 was the most probable diagnosis and in one case isolated Lisch nodules were observed. Of the 35 NF1 patients 28 ultimately developed bilateral Lisch nodules. Seven NF1 patients did not demonstrate the nodules. At follow-up no Lisch nodules were detected in 2 neurofibromatosis type 2 patients, in 4 patients in whom the diagnosis of NF1 remained doubtful and in 15 patients without NF1.

Conclusion: Because isolated Lisch nodules are very rare, their presence warrants a thorough patient history and clinical examination to either confirm or exclude generalised or segmental neurofibromatosis type 1.

RÉSUMÉ

But: Les nodules de Lisch bilatéraux sont considérés comme caractéristiques de la neurofibromatose

.....

* Department of Ophthalmology, University Hospital Antwerp.

** Department of Medical Genetics, University Hospital Antwerp.

received: 31.12.04

accepted: 11.02.05

de type 1 (NF1). Toutefois il nous a paru utile d'analyser la signification clinique des nodules de Lisch unilatéraux.

Méthode: Etude rétrospective concernant 59 patients ayant subi un examen génétique relatif à une neurofibromatose de type 1 (NF1) ou de type 2 (NF2) et un examen ophtalmologique.

Résultats: Des nodules de Lisch unilatéraux ont été observés chez 4 patients. Un enfant atteint de NF1 a présenté des nodules de Lisch unilatéraux à l'âge de 7 ans, et a ensuite développé des nodules de Lisch bilatéraux à l'âge de 9 ans. Un diagnostic de NF1 segmentaire était probable dans 2 autres cas et enfin, les nodules de Lisch étaient une observation sporadique dans un seul cas. Sur 35 patients atteints de NF1, 28 avaient des nodules bilatéraux. Les nodules de Lisch n'ont pas été observés dans 7 patients atteints de NF1, 2 patients atteints de la neurofibromatose de type 2, 4 cas où le diagnostic de NF1 n'était pas certain et 15 patients sans NF1.

Conclusion: L'existence de nodules de Lisch unilatéraux est une observation rare, et nécessite une anamnèse et un examen clinique pour la NF1 segmentaire et la NF1.

SAMENVATTING

Doel: Bilaterale Lisch nodules zijn typisch voor neurofibromatosis type 1 (NF1). We wilden het klinisch belang nagaan van unilaterale Lisch nodules.

Methode: Retrospectieve studie van 59 patiënten die genetisch onderzoek voor neurofibromatosis type 1 (NF1) of type 2 (NF2) ondergingen en onderzocht werden op de dienst oogheelkunde.

Resultaten: Unilaterale Lisch nodules werden bij 4 patiënten vastgesteld: 1 kind met NF1 had aanvankelijk unilaterale Lisch nodules, maar evolueerde naar bilaterale Lisch nodules op de leeftijd van 9; in 2 gevallen werd de mogelijke diagnose van segmentaire NF1 gesteld en bij 1 patiënt waren de Lisch nodules een geïsoleerde bevinding.

Van de 35 NF1 patiënten, hadden 28 patiënten bilaterale Lisch nodules. Er werden geen Lisch nodules gevonden bij 7 NF1 patiënten, 2 patiënten met neurofibromatosis type 2, 4 patiënten waarbij de diagnose van NF1 niet met zekerheid gesteld kon worden en bij 15 patiënten waarbij de diagnose van NF1 kon uitgesloten worden.

Conclusie: Omdat unilaterale Lisch nodules zelden geïsoleerd voorkomen, zijn klinisch onderzoek en anamnese voor segmentaire NF1 en NF1 noodzakelijk.

KEY WORDS

Lisch nodules, neurofibromatosis, unilateral.

MOTS-CLÉS

Nodules de Lisch, neurofibromatose, unilatéraux.

INTRODUCTION

Neurofibromatosis type 1 (NF1) is an autosomal dominant disease which affects 1 in 3000 individuals and is caused by a mutation in a tumour-suppressor gene, which has been mapped to chromosome 17q11.2 (1). Early diagnosis of neurofibromatosis is important for detection of associated complications and genetic counselling of family members (1). Mutation analysis is now possible, although it is complex and time consuming due to the large size of the gene. Diagnosis can be based on the clinical criteria established by the National Institutes of Health Consensus Development Conference on Neurofibromatosis in 1987 (Table 1) (6,12).

Neurofibromatosis type 2 (NF2), localized on chromosome 22q12, is less common than NF1 and affects only 1 in 40.000 individuals. The main manifestations (Table 2) are bilateral NVIII neuromas and other tumours of the central nervous system (CNS).

Lisch nodules are highly characteristic for NF1 and have an important diagnostic value. In NF1 they typically occur bilaterally (9, 21) and only

Table 1: *NIH diagnostic criteria for NF1: at least two of the following features must be present to make the diagnosis*

-
- Six or more café-au-lait spots of greatest diameter >5mm in the prepubertal and >15mm in postpubertal individuals
 - Two or more neurofibromas of any type or one plexiform neurofibroma
 - Axillary or inguinal freckling
 - Optic glioma
 - Two or more Lisch nodules
 - Distinctive osseous lesion such as sphenoid dysplasia or thinning of the long bone cortex with or without pseudoarthrosis
 - First degree relative with NF1
-

Table 2: *Diagnostic Criteria for NF2*

Individuals with the following clinical features have confirmed (definite) NF2:

- Bilateral NVIII schwannomas
 - Or
 - Family history of NF2 (first-degree family relative) plus
 1. Unilateral NVIII schwannoma <30 y or
 2. Any 2 of the following: meningioma, glioma, schwannoma, juvenile posterior subcapsular lenticular opacities/ juvenile cortical cataract
-

a few cases of unilateral Lisch nodules have been reported (2, 3, 5, 7, 8, 9, 19). Lisch nodules are melanocytic hamartomas and are well-defined, dome-shaped elevations (Figure 1) that vary in colour, size and number (14). Although they have a typical appearance, they can be confused with other iris conditions (Table 3) (14). They are predominantly located inferiorly on the iris (13). Lisch nodules are histologically identical to iris naevi but are located more anteriorly (20). They develop during childhood and their prevalence increases with age (13, 10). Lisch nodules are asymptomatic and are not related with visual impairment or clinical severity of NF1 (10).

PATIENTS AND METHODS

During a routine eye control of a 19-year-old boy at the Department of Ophthalmology of the Antwerp University Hospital, unilateral Lisch nodules were observed. This patient had no other features and no family history of NF1. Based on these findings, further research was conducted with regard to the significance of unilateral Lisch nodules. Between January 1995 and December 2003, 116 patients received genetic counselling for NF1 or NF2 at the Department of Medical Genetics of the Antwerp University Hospital, 59 of them were examined at the Department of Ophthalmology of the Antwerp University Hospital. The clinical data of

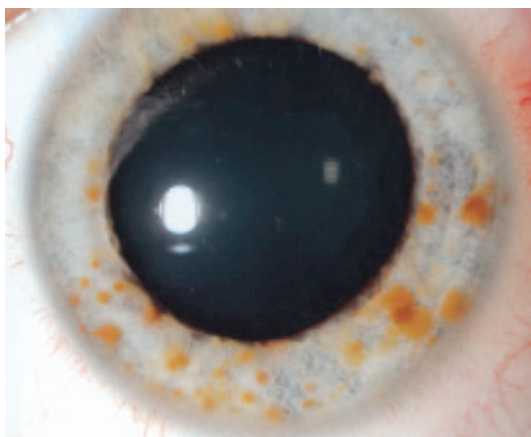


Fig 1. Lisch nodules

these 59 patients were reviewed retrospectively.

The diagnosis of NF1 was either made when a mutation was found in the NF1 gene (by sequencing of the total coding region of the NF1 gene, by Protein Truncation Test or by FISH analysis), or when the patient fulfilled the clinical criteria for NF1 (NIH diagnostic criteria, Table 1).

The diagnosis of NF2 was made in case of bilateral acoustic neurinoma, unilateral acoustic neurinoma together with another brain tumour (like a meningioma), or when a mutation was found in the NF2 gene (by DGGE of the total coding region of the NF2 gene).

The occurrence of Lisch nodules and the age of the patient were recorded.

RESULTS

Four cases of unilateral Lisch nodules were observed (Table 4).

One case had unilateral Lisch nodules without any features or family history of NF1. One child with NF1, initially diagnosed with unilateral Lisch nodules at the age of 7, developed bilateral Lisch nodules by the age of 9.

Table 3: *Differential diagnosis of Lisch Nodules*

- Multiple iris naevi
- Cogan-Reese (ICE) syndrome
- Iris mammillations associated with melanosis oculi
- Granulomatous iritis: e.g. sarcoidosis, tuberculosis, syphilis, leprosy
- Iris (tapioca) melanoma
- Iris cyst
- Retinoblastoma
- Brushfield flecks
- Malformations: Rieger-dysgenesis e.g.

Table 4: *Results.*

Lisch nodules	Patients	Mean age (years)	Diagnosis
Bilateral	27	25.8	NF 1
Progression unilat to bilat	1	9	NF1
Unilateral	2	22	Segmental NF1
Unilateral	1	19	No NF1
None	7	9	NF 1
None	2	44	NF 2
None	4	14.7	Doubtful
None	15	24.5	None

In 2 cases segmental NF1 was the most probable diagnosis. The first case was a 12-year-old boy without any family history of NF1. He had multiple café-au-lait spots in his chest region, some axillary freckles, multiple hamartomata, a plexiform neurofibroma around the aorta and unilateral Lisch nodules. All the NF1 features were limited to the chest region. Blood analysis revealed a somatic mosaicism of the NF1 gene.

Second case was a 32 year-old woman with some neurofibroma in her chest region, multiple café-au-lait spots, a plexiform neurofibroma on her skull and unilateral Lisch nodules. No mutation was found on blood analysis.

In both cases there was no DNA analysis performed on the affected tissues, but the NF1 features were limited to a specific region of the body. They were suspected for segmental NF1. In 35 cases NF1 was diagnosed, 2 of them had a history of surgical removal of optic glioma. Twenty-three of 25 (92%) NF1 patients of 6 years or older ultimately presented bilateral Lisch nodules. No Lisch nodules were detected in 7 NF1 patients.

No Lisch nodules were detected in the 2 NF2 patients.

In 4 cases the diagnosis remained doubtful. They had been referred to the department of medical genetics because of some suspected clinical features for NF1 (learning disabilities, café-au-lait spots, scoliosis and/or attention deficit) but none of them met the diagnostic criteria for NF1. None of them had Lisch nodules and mutation analysis was negative in all 4 cases.

Fifteen patients had been referred to the department of medical genetics because of some suspected features for NF1 or familial NF1. NF1 was excluded in all 15 patients and none of them had any Lisch nodules.

DISCUSSION

Until recently the uni- or bilateral occurrence of Lisch nodules received little attention. In most studies on the prevalence of Lisch nodules their uni- or bilaterality is not specified.

In this study no Lisch nodules were detected in 7 NF1 patients. Five of these 7 patients were children: 3 were 2 years old and 2 were 4 years

old at examination. However, as Lisch nodules appear during childhood and their prevalence increases with age (13, 10), they still could develop Lisch nodules. One child with NF1 initially presented unilateral Lisch nodules at the age of 7 years but developed bilateral Lisch nodules by the age of 9. Children with NF1 occasionally present unilateral Lisch nodules and presumably develop bilateral Lisch nodules over years (19).

Twenty-three of 25 (92%) NF1 patients older than 6 years, ultimately presented bilateral Lisch nodules. The prevalence of Lisch nodules in NF1 patients is reported in 73% to 100% (7, 9, 10, 13, 14, 21).

In 2 cases segmental NF1 was the most probable diagnosis. Segmental NF1 is a rare form of NF1 in which the typical NF1 features, i.e. neurofibromas and/or café-au-lait spots, are limited to one or a few adjacent dermatomes. It occurs 10 times less than generalized NF1, but is probably underdiagnosed and is reported with increasing frequency (15). Segmental NF1 is thought to arise from a postzygotic NF1 gene mutation, leading to a somatic mosaicism (17,18). Segmental NF1 does not carry the same risk for affected offspring. Only when the germinal cell line carries the mutation the risk for the offspring will be 50%, if not it is not increased. Unilateral Lisch nodules have been reported in cases of segmental NF1 and were mostly ipsilateral to the side of the NF1 manifestations (11, 16, 19).

No Lisch nodules were detected in the NF2 patients. Lisch nodules are not included in the diagnostic criteria of NF2 and have been reported in only 2 cases (3,4).

In one case unilateral Lisch nodules were observed without any features or family history of NF1. The prevalence of Lisch nodules in the general population is not well documented and unilateral Lisch nodules are rarely reported (2, 3, 5, 7, 8, 9, 19). In a study of 1037 unselected patients, 3 patients were found with solitary Lisch nodules without NF1 (5). In another prevalence study of Lisch nodules, among a group of 150 general ophthalmology outpatients, one patient had unilateral Lisch nodules without any other features of NF1 (7).

In patients without any other features of NF1 and without family history, unilateral Lisch nodules could be explained by a somatic mutation in the NF1 gene with a very limited mosaicism.

CONCLUSION

Unilateral Lisch nodules have been reported in prepubertal NF1, segmental NF1 and in isolated cases. Because isolated unilateral Lisch nodules are very rare, clinical examination and history taking to exclude generalized or segmental NF1 are mandatory.

REFERENCES

- (1) ARUN D., GUTMANN D.H. – Recent advances in neurofibromatosis type1. *Curr Opin Neurol* 2004; 17:101-105.
- (2) BOUZAS E.A., MASTORAKOS G., CHROUSOS G.P., KAISER-KUPFER M.I. – Lisch nodules in Cushing's Disease. *Arch Ophthalmol* 1993; 11:439-440.
- (3) CHARLES S.J., MOORE A.T., YATES J.R.W., FERGUSON-SMITH M.A. – Lisch nodules in neurofibromatosis type 2. *Arch Ophthalmol* 1989; 107:1571-2.
- (4) GARRETTO N.S., AMERISO S., MOLINA H.A., ARBERAS C., SALVAT J., MONTEVERDE D., SICA R.E.P. – Type 2 neurofibromatosis with Lisch nodules. *Neurofibromatosis* 1989; 2:315-21.
- (5) GREENE C., MALE W., ORLICK M., GORDON R. – Lisch nodules: prevalence and specificity for neurofibromatosis. *Am J Hum Genet Suppl* 1987; 41A:189.
- (6) GUTMANN D.H., AYLSWORTH A., CAREY J.C., KORF B., MARKS J., PYERITZ R.E., RUBENSTEIN A., VISKOCHIL D. – The diagnostic evaluation and multidisciplinary management of neurofibromatosis 1 and neurofibromatosis 2. *JAMA* 1997; 278:51-7.
- (7) HUSON S., JONES D., BECK L. – Ophthalmic manifestations of neurofibromatosis. *Br J Ophthalmol* 1987, 71, 235-238.
- (8) LAL G., LEAVITT J.A., LINDOR N.M., MAHR M.A. – Unilateral Lisch nodules in the absence of other features of neurofibromatosis type 1. *Am J Ophthalmol* 2003; 135:567-8.
- (9) LEWIS R.A., RICCARDI V.M. – Von Recklinghausen neurofibromatosis. Incidence of iris hamartomata. *Ophthalmology* 1981; 88:348-54.
- (10) LUBS M.L., BAUER M.S., FORMAS M.E., DJOKIC B. – Lisch nodules in neurofibromatosis type 1. *N Engl J Med* 1991; 324:1264-6.
- (11) MOSS C., GREEN S.H. – What is segmental neurofibromatosis? *Br J Dermatol* 1994; 130:106-110.
- (12) NATIONAL INSTITUTES OF HEALTH CONSENSUS DEVELOPMENT CONFERENCE – Neurofibromatosis: conference statement. *Arch Neurol* 1988; 45:575-8.
- (13) NICHOLS J.C., AMATO J.E., CHUNG S.M. – Characteristics of Lisch nodules in patients with neurofibromatosis type1. *J Pediatr Ophthalmol Strabismus* 2003; 40:293-6.
- (14) RAGGE N.K., FALK R.E., COHEN W.E., MURPHREE A.L. – Images of Lisch nodules across the spectrum. *Eye* 1993; 7:95-101.
- (15) RUGGIERI M., PAVONE P., POLIZZI A., DI PIETRO M., SCUDERI A., GABRIELE A., SPALIZE A., IANNETTI P. – Ophthalmological manifestations in segmental neurofibromatosis type 1. *Br J Ophthalmol* 2004; 88:1429-33.
- (16) SLOAN J.B., FRETZIN D.F., BOVENMEYER D.A. – Genetic counseling in segmental neurofibromatosis. *J Am Acad Dermatol* 1990; 22, 461-467.
- (17) TINSCHERT S., NAUMANN I., STEGMANN E., BUSKE A., KAUFMANN D., THIEL G., JENNE D.E. – Segmental neurofibromatosis is caused by a somatic mutation of the neurofibromatosis type1(NF1) gene. *Eur J Hum Genet* 2000; 8:455-459.
- (18) VAN DEN BROUCKE I., VAN DOORN R., CALLENS T., COBBEN J.M., STARINK T.M., MESSIAEN L. – Genetic and clinical mosaicism in a patient with neurofibromatosis type1. *Hum Genet* 2004; 114:284-290.
- (19) WELEBER R.G., ZONANA J. – Iris hamartomas (Lisch Nodules) in a case of segmental neurofibromatosis. *Am J Ophthalmol* 1983; 96,740-743.
- (20) WILLIAMSON T.H., GARNER A., MOORE A.T. – Structure of Lisch nodules in neurofibromatosis type1. *Ophthalmic Paediatr Genet* 1991; 12:11-17.
- (21) ZEHAZI C., ROMANO A., GOODMAN R.M. – Iris (Lisch) nodules in neurofibromatosis. *Clin Genetics* 1986; 29:51-59.

.....

Adress for correspondance
 Dr. S.D. CEUTERICK, Dr. R.M.E. SMETS
 University Hospital of Antwerp
 Department of Ophthalmology
 Wilrijkstraat 10
 B-2650 Edegem
 Belgium
 Tel.: (03) 821.33.72
 Fax: (03) 825.19.26