

BILATERAL COATS' DISEASE WITH UNUSUAL PRESENTATION - A CASE REPORT

DE BLAUWE A. *, VAN GINDERDEUREN R. *,
CASTEELS I. *

ABSTRACT

Coats' disease is a well-known ocular disorder, characterized by idiopathic retinal telangiectasia, retinal exudation and retinal detachment.

We report on a boy who first presented at the age of 2 years with Coats' disease and secondary neovascular glaucoma. The differential diagnosis with retinoblastoma could not be made clinically or with the help of imaging studies, such as ultrasonography or computed tomography scanning (CT-scan). The right eye was consequently enucleated for diagnostic and therapeutical purposes. Histopathologic examination confirmed the diagnosis of Coats' disease.

Five years later the same boy consulted again with profound visual loss in his only functional left eye. Fundoscopy revealed lesions typical for Coats' disease.

Coats' disease can present in very different ways and bilateral disease is possible, even after several years.

RÉSUMÉ

La maladie de Coats est une maladie oculaire bien connue associant télangiectasies rétinienne idiopathiques, exsudats rétiens et décollement de rétine.

Nous rapportons ici l'histoire d'un garçon, âgé de deux ans qui présentait un tableau atypique de maladie de Coats avec glaucome néovasculaire secondaire de l'œil droit.

Le diagnostic différentiel avec un rétinoblastome n'a pas pu être établi sur base de l'examen clinique, de l'échographie ou du CT-scan. Par conséquent, l'œil

.....

* *Department of Ophthalmology, University Hospitals Leuven, Belgium*

received: 01.12.04

accepted: 01.02.05

droit a été énucléé pour des raisons diagnostiques et thérapeutiques. L'examen histopathologique a confirmé le diagnostic de maladie de Coats.

Cinq ans plus tard, ce jeune garçon s'est présenté suite à une baisse importante de l'acuité visuelle de son œil gauche. L'examen du fond d'œil montrait des lésions typiques de maladie de Coats.

Ce cas clinique indique que la maladie de Coats peut se présenter de différentes façons. Une atteinte bilatérale est possible, même après plusieurs années.

SAMENVATTING

De ziekte van Coats is een bekende oftalmologische aandoening, die gekenmerkt wordt door idiopathische retinale teleangiectasieën, retinale exsudaten en retinaloslating.

Een tweejarig jongetje vertoonde de ziekte van Coats en secundair neovasculair glaucoom in het rechter oog. De differentiële diagnose met een retinoblastoma kon noch klinisch, noch met behulp van echografie of CT-scan worden gemaakt. Het rechter oog werd vervolgens geënucléëerd, zowel voor diagnostische als voor therapeutische doeleinden. Histopathologisch onderzoek bevestigde de diagnose van de ziekte van Coats.

Vijf jaar nadien consulteerde deze jongen opnieuw omwille van een forse visusdaling in zijn enige functionele linker oog. Fundoscopie toonde letsels, typisch voor de ziekte van Coats. Dit geval illustreert dat de ziekte van Coats zich zeer verscheiden kan presenteren en dat bilaterale aantasting mogelijk is, zelfs na meerdere jaren.

KEY WORDS

Coats' disease, secondary neovascular glaucoma, bilateral.

MOTS-CLÉS

Maladie de Coats, glaucome néovasculaire secondaire, bilatéral.

INTRODUCTION

In 1908 Coats described an ophthalmologic disease, characterized by unilateral retinal vascular abnormalities and retinal exudation, which usually occurred in young males (3). In 1912 Leber reported on a condition with multiple retinal aneurysms, later known as Leber miliary aneurysms (8). In 1955 Reese considered as first Coats' disease and Leber miliary aneurysms as a spectrum of the same disease (11). Today Coats' disease is a well-known ocular disorder, defined by Shields et al. as idiopathic retinal telangiectasia with intraretinal or subretinal exudation, without appreciable signs of retinal or vitreal traction (14). If untreated it can lead to total retinal detachment and secondary glaucoma, sometimes requiring enucleation (2, 7, 10, 14, 15, 18). It typically affects young males who present with unilateral visual loss, strabismus or leukocoria. The differential diagnosis with retinoblastoma can be difficult but is often possible by clinical examination only (5, 13, 16, 17).

We report on a boy with bilateral Coats' disease and a very unusual presentation.

CASE REPORT

A 2 year old black boy was referred to us from Kigali with high suspicion of a retinoblastoma in the right eye. He presented with a 5-month history of divergent strabismus, a 1-month history of leukocoria and a very recent onset of an extremely painful, red right eye. He was generally unwell with loss of appetite, lethargy and fever. His family history was negative for retinoblastoma.

Prompt examination under general anaesthesia revealed a rock-hard, chemotic right eye with clear cornea but a very flat anterior chamber and a pseudohypopyon. Fundus examination through a very hazy vitreous showed a bilobular mass. Fundoscopy with indentation of the left eye was unremarkable.

Ultrasonography of the right eye confirmed the presence of a dense intraocular mass without calcifications.

A CT-scan of the orbits demonstrated an increased density and volume of the right globe

with anterior displacement of the lens and orbital cellulitis. No calcifications were seen.

A sample of blood, anterior chamber fluid, cerebrospinal fluid and bone marrow aspiration were examined.

As a retinoblastoma could still not be excluded, as there was no hope for visual recovery and as the child would suffer from a blind, painful eye requiring long-term medication, the parents agreed with enucleation.

Histopathologic examination of the enucleated eye showed a necrotic and detached retina, telangiectatic vessels and massive eosinophilic subretinal fluid with lipid laden macrophages and cholesterol clefts. All these findings were consistent with the diagnosis of Coats' disease (fig. 1). There was no evidence for tumoral pathology.

Five years later the same boy was again referred to us because of profoundly decreased vision in his only functional left eye. Visual acuity on Snellen chart was 0.1. Biomicroscopy of the anterior segment showed no abnormalities. Fundoscopy revealed a subretinal yellow exudation at the posterior pole, including the fovea, with glistening yellow cholesterol crystals and telangiectatic vessels superotemporally, compatible with the diagnosis of Coats' disease (fig. 2). Retinal indirect diodelaser was performed to the left eye in two sessions in order to salvage as much vision as possible.

DISCUSSION

The diagnosis of Coats' disease and differential diagnosis with retinoblastoma can often be made by clinical examination only. Both diseases occur mainly in young children and can produce retinal detachment, leukocoria and secondary glaucoma, but differ with regard to demographics, clinical findings on ocular examination and results of imaging studies, such as ultrasonography, CT-scan and magnetic resonance imaging (5, 13, 16, 17).

In our case, however, although the mother mentioned a history of strabismus and leukocoria, the boy presented to us in a very late stage of the disease with secondary neovascular glaucoma. Clinical examination and even imaging studies couldn't exclude a retinoblastoma.

Mainly an exophytic retinoblastoma with subretinal fluid accumulation can mimic the ap-

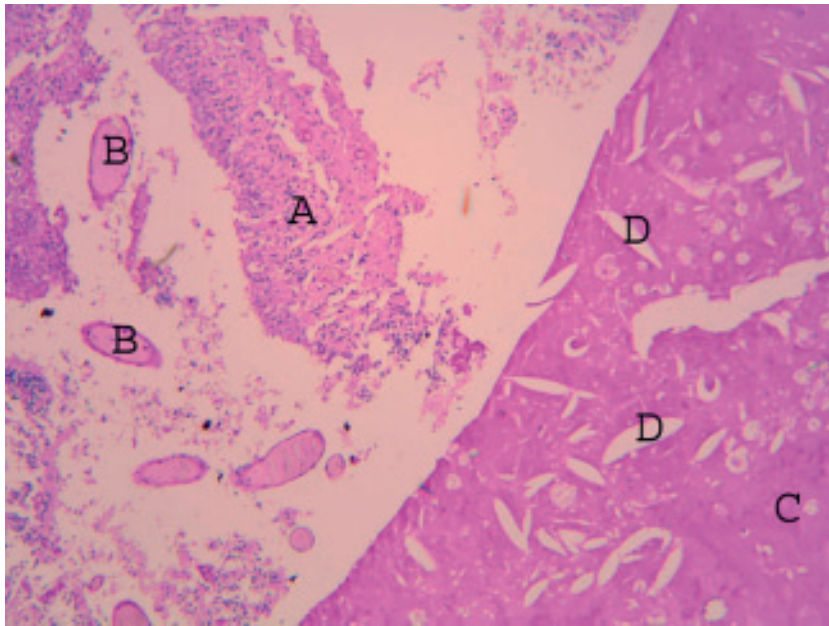


Fig 1. Histopathologic slide of the enucleated right eye, showing typical findings for Coats' disease: A: necrotic and detached retina; B: telangiectatic vessel; C: massive eosinophilic exudate; D: cholesterol clefts.

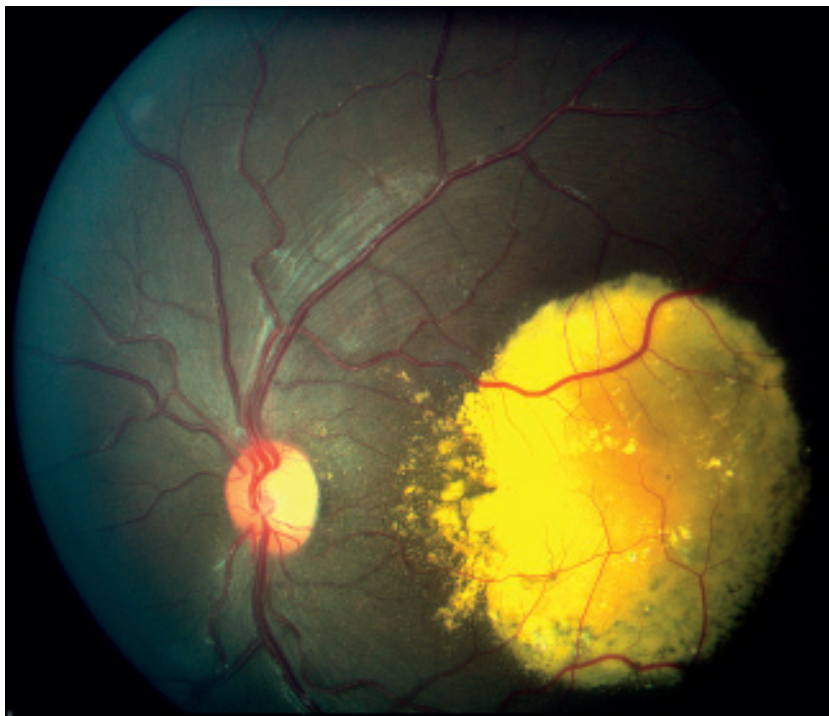

Fig 2. Fundus photograph of the left eye with typical findings for Coats' disease: subretinal yellow exudation at the posterior pole with glistening yellow cholesterol crystals. Telangiectatic vessels, localized more in the periphery, are not visualized on this picture.

pearance of an exudative retinal detachment, suggestive for advanced Coats' disease. In our patient, however, the pseudohypopyon, the hazy fundoscopic appearance of a bilobular mass and the orbital inflammation, were suggestive for an endophytic retinoblastoma with vitreous seeding.

The extent and severity of Coats' disease are known to be worse in young children, particularly in those under three years of age. Secondary neovascular glaucoma and orbital cellulitis are possible presenting signs in young children or infants with Coats' disease (6). As usual, a young child doesn't notice or report unilateral gradual visual deterioration. The delay in diagnosis in our patient contributed to the advanced stage of Coats' disease with secondary neovascular glaucoma and orbital cellulitis (2, 7, 10, 18).

Enucleation of the right eye was necessary for both diagnostic and therapeutical purposes. Only after histopathologic examination, the diagnosis of retinoblastoma could be excluded and the diagnosis of Coats' disease confirmed. Enucleation in young children with secondary neovascular glaucoma is justified to spare the child chronic pain and the chronic use of oral and topical medication (7, 10, 15).

Coats' disease usually occurs unilaterally (4, 12, 19, 20). In his series of 150 consecutive patients (158 eyes), Shields et al. reported that both eyes were affected in only 8 patients (5%). They also stated that many reported bilateral cases of Coats' disease represent other conditions that do not meet criteria for diagnosis, for example Cornelia de Lange syndrome, Senior-Loken syndrome, muscular dystrophy, retinitis pigmentosa and many others (14).

In bilateral cases of Coats' disease reported by Shields, the secondly affected eye was usually asymptomatic and contained only subtle peripheral telangiectasia (14). In our patient, however, fundoscopy showed retinal telangiectasia superotemporally, associated with massive intraretinal exudation at the posterior pole including the fovea. Visual acuity in this eye was consequently profoundly decreased to 0.1 on Snellen chart.

Moreover, histopathologic examination of the enucleated eye and typical ophthalmoscopic findings in the fellow eye produced convincing

evidence of the diagnosis of Coats' disease, meeting the criteria Shields proposed.

Long term follow-up is necessary in children with Coats' disease. In the first place, there can be reactivation of apparently burnt-out lesions (1, 20). Moreover, as in our patient, the fellow eye is at risk for Coats' disease as well. Reports in the literature on the interval of presentation and diagnosis of the secondly affected eye are rare. In most patients with bilateral disease, the diagnosis is made on the occasion of routine fundoscopy when the first eye is diagnosed with Coats' disease (1, 9, 14). Our patient, however, showed an unremarkable fundoscopy with indentation of the left eye initially, but he presented five years later with extensive Coats' disease.

Long term follow-up, prompt diagnosis and accurate treatment in an early stage are very important to save as much vision as possible in these already visually impaired children.

REFERENCES

- (1) ALEXANDRIDOU A., STAVROU P. – Bilateral Coats' disease: long term follow-up. *Acta Ophthalmol Scand* 2002; 80: 98 - 100.
- (2) CHAR D.H. – Coats' syndrome: long term follow-up. *Br J Ophthalmol* 2000; 84: 37 - 39.
- (3) COATS G. – Forms of retinal disease with massive exudation. *Roy Lond Ophthalmol Hosp Rep* 1908; 17: 440 - 525.
- (4) EGERER I., TASMAN W.S., TOMER T.T. – Coats' disease. *Arch Ophthalmol* 1974; 92: 109 - 112.
- (5) HOWARD G.M., ELLSWORTH R.M. – Differential diagnosis of retinoblastoma. A statistical survey of 500 children. I. Relative frequency of the lesions which simulate retinoblastoma. *Am J Ophthalmol* 1965; 60: 610 - 618.
- (6) JUDISCH G.F., APPLE D.J. – Orbital cellulitis in an infant secondary to Coats' disease. *Arch Ophthalmol* 1980; 98: 2004 - 6.
- (7) KOGAN L., BONIUK M. – Causes for enucleation in childhood with special reference to pseudogliomas and unsuspected retinoblastoma. *Int Ophthalmol Clin* 1962; 2: 507 - 524.
- (8) LEBER T. – Ueber eine durch Vorkommen multipler Miliaraneurysmen charakterisierte Form von Retinaldegeneration. *Graefes Arch Klin Ophthalmol* 1912; 81: 1 - 14.
- (9) MCGETTRICK P.M., LOEFFLER K.U. – Bilateral Coats' disease in an infant (a clinical, an-

- giographic, light and electron microscopy study). *Eye* 1987; 1: 136 - 145.
- (10) MORALES A.G. – Coats' disease. Natural history and results of treatment. *Am J Ophthalmol* 1965; 60: 855 - 65.
- (11) REESE A.B. – Teleangiectasis of the retina and Coats' disease. *Am J Ophthalmol* 1956; 42: 1 - 8.
- (12) RIDLEY M.E., SHIELDS J.A., BROWN G.C., TASMAN W. – Coats' disease. Evaluation of management. *Ophthalmology* 1982; 89: 1381 - 1387.
- (13) SHIELDS J.A., SHIELDS C.L. – Differentiation of Coats' disease and retinoblastoma. *J Pediatr Ophthalmol Strabismus* 2001; 38: 262 - 266.
- (14) SHIELDS J.A., SHIELDS C.L., HONAVAR S.G., DEMIRCI H. – Clinical variations and complications of Coats' disease in 150 cases: the 2000 Sanford Gifford Memorial Lecture. *Am J Ophthalmol* 2001; 131: 561 - 571.
- (15) SHIELDS J.A., SHIELDS C.L., HONAVAR S.G., DEMIRCI H., CATER J. – Classification and management of Coats' disease: the 2000 Proctor Lecture. *Am J Ophthalmol* 2001; 131: 572 - 583.
- (16) SHIELDS J.A., SHIELDS C.L., PARSONS H.M. – Review. Differential diagnosis of retinoblastoma. *Retina* 1991; 11: 232 - 243.
- (17) SHIELDS J.A., PARSONS H., SHIELDS C.L., SHAH P. – Lesions simulating retinoblastoma. *J Pediatr Ophthalmol Strabismus* 1991; 28: 338 - 340.
- (18) SILODOR S.W., AUGSBURGER J.J., SHIELDS J.A., TASMAN W.S. – Natural history and management of advanced Coats' disease. *Ophthalmic Surg* 1988; 19: 89 - 93.
- (19) SPITZNAS M., JOUSSEN F., WESSING A., MEYER-SCHWICKERATH G. – Coats' disease. An epidemiologic and fluorescein angiographic study. *Graefe's Arch Klin Exp Ophthalmol* 1975; 195: 241 - 259.
- (20) TARKKANEN A., LAATIKAINEN L. – Coats' disease: clinical, angiographic, histopathologic findings and clinical management. *Br J Ophthalmol* 1983; 67: 766 - 776.

.....

REQUEST FOR REPRINTS
Dr. An E. DE BLAUWE
U.Z. St.Rafaël.
Department of Ophthalmology
Kapucijnenvoer 33
3000 Leuven
Belgium
Tel.016/33 23 70
Fax.016/33 23 67
annelies_de_blauwe@hotmail.com