
EXTERNAL OPHTHALMOMYIASIS: A CASE REPORT

VERSTRYNGE K. *, FOETS B. *

SUMMARY

Many dipteran flies can cause ophthalmomyiasis, a potentially severe and vision threatening disease. We report a case of ophthalmomyiasis caused by *Oestrus ovis*. Larvae of *Oestrus ovis* are confined to the surface of the eye and cause external ophthalmomyiasis. The presentation is similar to a viral conjunctivitis, with tearing, itching, hyperaemia and foreign body sensation. The disease is self-limiting and removal of the larvae is the most effective therapy. Identification of the species is important to estimate the risk of penetration of the globe.

RÉSUMÉ

De nombreuses mouches diptères peuvent causer l'ophtalmomyiase, qui peut être sévère et menaçante pour la vue. Nous rapportons un cas d'ophtalmomyiase causé par l'*Oestrus ovis*. Les larves d'*Oestrus ovis* sont circonscrites à la surface oculaire et provoquent l'ophtalmomyiase externe. La présentation est similaire à une conjonctivite virale, avec larmoiement, démangeaison, hyperémie et sensation de corps étranger. La maladie est circonscrite et l'enlèvement des larves est la thérapie la plus efficace. L'identification de l'espèce est importante pour estimer le danger de pénétration dans le globe.

SAMENVATTING

Vele diptere vliegen kunnen oftalmomyiasis, een potentieel ernstige en visusbedreigende aandoening, veroorzaken. Wij beschrijven een geval van oftalmomyiasis veroorzaakt door de vlieg *Oestrus ovis*. De larven van de *Oestrus ovis* blijven gelimiteerd tot het oogoppervlak en leiden tot externe oftalmomyia-

sis. De patiënt meldt zich met symptomen van een virale conjunctivitis, zoals tranen, jeuk, hyperemie en vreemd-voorwerpgevoel. De aandoening is zelflimiterend en verwijdering van de larven is de meest efficiënte behandeling. Identificatie van het specimen is belangrijk om gevaar voor penetratie in de oogbol in te schatten.

KEY WORDS

External ophthalmomyiasis, *Oestrus ovis*

MOTS-CLÉS

Ophtalmomyiase externe, *Oestrus ovis*

.....

* *University Hospitals Leuven, Department of Ophthalmology.*

received: 21.09.04

accepted: 08.11.04

INTRODUCTION

Myiasis is the infestation of live human and vertebrate animals with dipterous larvae, which, at least for a certain period, feed on the host's dead or living tissue, liquid body-substances or ingested food (11) and subsequently may cause different clinical pictures. *Oestrus ovis* (sheep nasal botfly) is one of the most common causes of human myiasis. The normal hosts for the larvae are sheep and goats. Occasionally, humans are the intermediate hosts, with the eye as the site of infestation. The clinical picture is that of a viral or allergic conjunctivitis with tearing, foreign body sensation and itching of the eye. This is the first report of an imported case of external ophthalmomyiasis in Belgium.

CASE REPORT

A 26-year-old woman was referred to the Casualty Department of the University Hospitals in Leuven with foreign body sensation, irritation and tearing of the right eye. The symptoms began 24 hours earlier, on returning from a holiday to Crete. She did not remember being struck in the eye or face by any insects. Her ophthalmologic history was negative.

On examination we found a slightly congested conjunctiva, but otherwise quiet anterior segment with five small (1mm), transparent, moving maggots in the fornix, on the plica interna and under the upper eyelid (fig 1a). The maggots avoided the slitlamp beam, as they were photophobic. They stuck to the conjunctiva and were very difficult to remove using a cotton

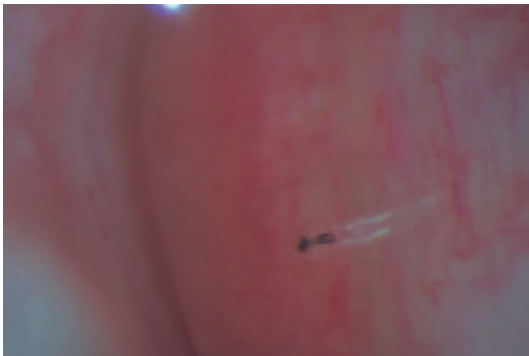

Fig. 1a: maggot on the conjunctiva near the plica interna

swab, with one maggot causing a small conjunctival bleeding on attempt of removal. Their mobility did not slow after instillation of oxybuprocaine. After photographic documentation, we removed the maggots with a forceps. A conjunctival sac washout with saline solution was performed. In order to kill possibly remaining maggots by dehydration, hypertonic saline ointment was administered. The otorhinolaryngologist performed an endoscopy of the nose and sinuses, because the patient also complained of watery nasal discharge. This examination revealed a congested nasal mucosa. On follow-up examination two days later, no residual maggots could be found and the patient was free of symptoms.

The maggots were identified as fly larvae by means of the slitlamp pictures by the Department of Microbiology of the University of Leuven and by the Institute of Tropical Medicine of Antwerp. They were segmented and had two large dark oral hooks, connected to a white cephalopharyngeal skeleton. The body was translucent (fig 1b). A more definitive identification was not possible because the larvae were dead and had not been properly preserved.

DISCUSSION

Ophthalmomyiasis is classified as orbital, external or internal, based on the site of larval invasion. Large numbers of larvae invading and destroying orbital contents cause orbital myiasis. External ophthalmomyiasis refers to superficial infestation of ocular tissue, including the conjunctiva. Internal ophthalmomyiasis occurs

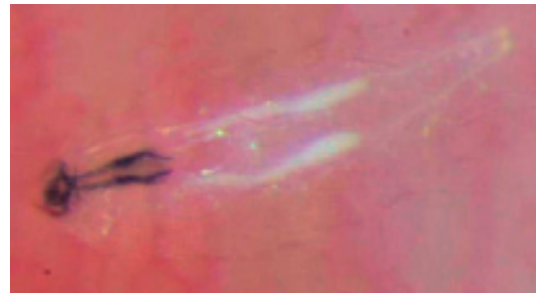

Fig. 1b: maggot with translucent and segmented body and two large dark oral hooks connected to a white cephalopharyngeal skeleton



Fig. 2: *Oestrus ovis*: adult insect

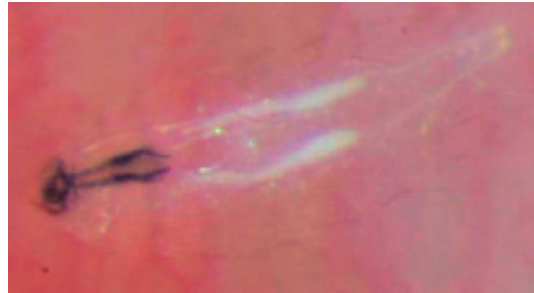


Fig. 3: life cycle of *Oestrus ovis*

when the larvae penetrate the sclera and burrow in the subretinal space.

Three dipteran families are considered as the main causes of myiasis in humans. These families include Oestridae, Calliphoridae and Sarcophagidae (9). External ophthalmomyiasis is often a benign self-limiting disease (1, 2, 3, 7, 8, 14, 17, 18), in contrast with internal ophthalmomyiasis which can lead to severe loss of vision or even loss of the eye. If the infestation is caused by larvae with burrowing habits, they can give rise to very destructive forms of ophthalmomyiasis, especially in debilitated patients (3, 4, 6, 10, 16, 19). Fly species of the genera *Calliphora*, *Lucilia*, *Sarcophaga*, *Gasterophilus*, *Hypoderma* (5), *Musca*, *Callitroga*, *Cuterebra* (4, 12, 13), *Dermatobia*, *Chrysomyia*, *Wohlfahrtia* and *Oedemagena* (6) are known to cause internal ophthalmomyiasis in humans. *Oestrus ovis* (sheep nasal botfly) (class: Insecta, order: Diptera and family: Oestridae) is the most common cause of human myiasis (14). The adult insect is slightly smaller than a honeybee (fig 2). Its mouthparts are vestigial. The fly is ubiquitous, but most common in shepherding areas. The normal hosts of the larvae include sheep and goats. Occasionally, due to an aberration in the life cycle (7), man is the intermediate host of which the eye is the site of infestation. Poor health of sheep and farmer, close contact between animals and man, and generally poor living conditions may be contributing factors to the likelihood of human infestation. The gravid adult female fly swarms around the head of the animals and ejects the first-instar larvae, which have previously hatched from the eggs in the fly vagina, in a stream of

milky fluid onto the nostrils of the host. Direct contact between the fly and its host is not necessary for the infestation (7). The larvae of *Oestrus ovis* mature in the mucus membrane of the nasal cavities. Ultimately, they are sneezed onto the soil where they pupate to become an imago (fig 3). The *Oestrus ovis* larvae have no bite organisms and are unable to secrete proteolytic enzymes, so that they are mostly confined to the outer membranes of the eye (3). However, small conjunctival hemorrhages may be apparent at sites where the larva clings with its mouth claws. In man the larvae cannot survive beyond the first larval stage and are believed to die within ten days if not removed (11). In the human conjunctiva they can cause a great deal of irritation, lacrimation, pain and inflammation, which should be differentiated from an allergic reaction or viral conjunctivitis. As the larvae are small, translucent and quickly avoiding the slitlamp beam, they can be easily overlooked. Grammer et al. summarized numerous cases of external ophthalmomyiasis due to *Oestrus ovis* (7).

Exact taxonomic classification of dipterous larvae that have been removed from superficial parts of the eye is important for estimating the potential risk of intraocular penetration of possibly remaining larvae not found during slitlamp examination. Removed larvae should be preserved in 70% alcohol and sent to specialists for examination. Especially the caudal portion (posterior spiracles) and the cephalopharyngeal skeleton of the larva are important for exact identification (11). However, in emergency situations it is not always easy to estimate the probable danger of a rare disease and know-

ledge of microbiologic preserving and culturing techniques is not evident. Our experience showed that larvae quickly die and dry out once removed from the eye. We could not immediately find specialists to help us preserving the species in a good way. We therefore tempted to identify the larva as *Oestrus ovis* based only on biomicroscopic appearance (translucent body, segmentation, large dark oral hooks connected to a white cephalopharyngeal skeleton) and extended study of the literature. Arguments strongly in favour of infestation with larvae of *Oestrus ovis* are the region of infestation, the season, clinical manifestation and microscopic characteristics of the larvae.

Except for mechanical removal, there is no other therapy described. In contrast to our experience, topical anaesthetics are said to paralyse the larvae (15). Topical steroids relieve symptoms. Topical antibiotics are useful in preventing secondary infection by bacteria. Follow-up examination by an ophthalmologist is recommended to avoid the possible complication of internal ophthalmomyiasis.

CONCLUSION

This is by our knowledge the first report of an imported case of external ophthalmomyiasis by *Oestrus ovis* in Belgium. We describe a typical case of external ophthalmomyiasis most likely due to *Oestrus Ovis*. Although external ophthalmomyiasis is an uncommon condition in northern Europe, one should be cautious for imported cases in travellers from Mediterranean areas or elsewhere. Some fly species are capable of penetrating the globe, causing internal ophthalmomyiasis, which is sight-threatening. Therefore, taxonomic differentiation is important.

REFERENCES

- (1) CAMERON J.A., SHOUKREY N.M., AL-GARNI A.A. – Conjunctival Ophthalmomyiasis caused by the sheep nasal botfly (*oestrus ovis*). *Am J Ophthalmol* 1991; 112: 331-334.
- (2) CHODOSH J., CLARRIDGE J.E., MATOBA A. – Nosocomial conjunctival ophthalmomyiasis with *Cochliomyia macellaria*. *Am J Ophthalmol* 1991; 111: 520-521.
- (3) DE VRIES L.A.M., VAN BIJSTERVELD O.P. – Ophthalmomyiasis conjunctivae. *Ophthalmologica* 1986; 192: 193-197.
- (4) DIXON J.M., WINKLER C.H., NELSON J.H. – Ophthalmomyiasis interna caused by *Cuterebra* larva. *Am J Ophthalmol* 1971; 1: 415-416.
- (5) EDWARDS K.M., MEREDITH T.A., HAGLER W.S., HEALY G.R. – Ophthalmomyiasis interna causing visual loss. *Am J Ophthalmol* 1984; 97: 605-610.
- (6) GJOTTERBERG M., INGEMANSSON S.O. – Intraocular infestation by the reindeer warble fly larva: an unusual indication for acute vitrectomy. *Br J Ophthalmol* 1988; 72: 420-423.
- (7) GRAMMER J., ERB C., KAMIN G., WILD M., RIEDINGER C., KOSMIDIS P., PLEYER U., THIEL H. – Ophthalmomyiasis externa due to the sheep botfly *Oestrus ovis* (Diptera: Oestridae) in southwest Germany. *Germ J Ophthalmol* 1995; 4: 188-195.
- (8) GROH M.J.M., JUNEMANN A., ZILCH R. – Ophthalmomyiasis externa durch *Oestrus ovis* in Franken. *Klin Monatsbl Augenheilkd* 1998; 213: 60-62.
- (9) HAKIMI R., YAZDI I. – Oral mucosa myiasis caused by *Oestrus Ovis*. *Arch Iranian Med* 2002; 5: 194-196.
- (10) JAKOBS E.M., ADELBERG D.A., LEWIS J.M., TRPIS M., GREEN R. – Ophthalmomyiasis interna posterior. *Retina* 1997; 17: 310-314.
- (11) LANE R.P., CROSSKEY R.W. – Medical insects and arachnids. London: Chapman & Hall. Textbook: 1993; 429-469.
- (12) NEWMAN P.E., BEAVER P.C., KOZARSKY P.E., WARING G.O. – Fly larva adherent to corneal endothelium. *Am J Ophthalmol* 1986; 102: 211-216.
- (13) PERRY H.D., DONNENFELD E.D., FONT R.L. – Intracorneal ophthalmomyiasis. *Am J Ophthalmol* 1990; 190: 741-742.
- (14) REINGOLD W.J., ROBIN J.B., LEIPA D., KONDRA L., SCHANZLIN D.J., SMITH R.E. – *Oestrus ovis* ophthalmomyiasis externa. *Am J Ophthalmol* 1984; 97: 7-10.
- (15) SIGAUKE E., BEEBE W.E., GANDER R.M., CA-VUOTI D., SOUTHERN P. – Case report: Ophthalmomyiasis externa in Dallas county, Texas. *Am J Trop Med Hyg* 2003; 68: 46-47.
- (16) SIVARAMASUBRAMANYAM P., SADANAND A.V. – Ophthalmomyiasis. *Br J Ophthalmol* 1968; 52: 64-65.
- (17) STEVENS J.D., McCARTNEY A.C., HOWES R. – *Oestrus ovis* ophthalmomyiasis acquired in the UK: case report and scanning electron microscopic study. *Br J Ophthalmol* 1991; 75: 702-703.

- (18) WONG D. – External ophthalmomyiasis caused by the sheep bot *Oestrus ovis* L. *Br J Ophthalmol* 1982; 66: 786-787.
- (19) ZIEMIANSKI M.C., LEE K.Y., SABATES F.N. – Ophthalmomyiasis Interna. *Arch Ophthalmol* 1980; 98: 1588-1589.

We would like to thank Prof. De Loof of the Department of Animal Physiology and Neurobiology of the University of Leuven and Dr. Wim Van Bortel of the Institute of Tropical Medicine in Antwerp for helping us identifying the larvae.

.....

Correspondence:
Dr. K. Verstrynge,
University Hospitals Leuven, Department of
Ophthalmology,
Kapucijnenvoer 33, 3000 Leuven, Belgium.
E-mail: katrien.verstrynge@uzleuven.be