

POSTERIOR UVEITIS: AN UNDER-RECOGNIZED ADVERSE EFFECT OF PAMIDRONATE: 2 CASE REPORTS

HAVERBEKE G.* , PERTILE G.* , CLAES C.* ,
ZEYEN T.*

SUMMARY

Ocular adverse effects of pamidronic acid are rare but well documented. Pamidronate, an inhibitor of bone resorption used primarily in the management of tumor-induced hypercalcemia and Paget's disease, is reported to cause conjunctivitis, anterior uveitis, and infrequently episcleritis and scleritis. It is hypothesized that an allergic or immunologic phenomenon caused by drug-induced immune complex formation is at fault. The reason why the uvea is a target organ is unclear. The acute inflammatory response seems unrelated to the dose of the drug, the way of administration, or the activity of Paget's disease or malignancy.

We report two cases of pamidronate-induced posterior uveitis, following the WHO Causality Assessment Guide of Suspected Adverse Reactions.

Uveitis and scleritis have been reported in association with a variety of topical, intraocular, periocular, and systemic medications. Seven criteria were proposed to establish causality of adverse events by drugs. Only systemically administered biphosphonates meet all seven criteria.

Where pamidronate is currently considered as the drug of choice in diverse strategies, the adverse ocular effects should be well known to physicians in order to make rapid diagnosis and stop the drug causing adverse reaction.

.....

* Dept. of Ophthalmology, AZ Middelheim, Antwerp, Belgium.

received: 23.07.03

accepted: 12.11.03

SAMENVATTING

Oftalmologische nevenwerkingen veroorzaakt door pamidronaat zijn uitzonderlijk doch goed gedocumenteerd. Conjunctivitiden, anterieure uveïtiden en zelden episcleritiden zijn gerapporteerd bij het gebruik van pamidronaat, een inhibitor van de botresorptie, dat wordt gebruikt bij het behandelen van secundaire tumorale hypercalcemie en bij de ziekte van Paget.

De gangbare hypothese is een allergisch of een immuun-gemedieerd fenomeen, veroorzaakt door vorming van immuuncomplexen. Het is onduidelijk waarom de uvea wordt aangetast. Daarbij blijkt het dat de inflammatoire reactie niet relateerd is met de dosering van het product, noch met de graad van activiteit van de ziekte van Paget of de maligniteit.

Wij beschrijven twee gevallen van posterieure uveïtis geïnduceerd door pamidronaat, volgens de 'WHO Causality Assessment Guide of Suspected Adverse Reactions'.

Uveïtis en scleritis zijn gerapporteerd in associatie met een reeks topicale, peri-oculaire en intra-oculaire geneesmiddelen. Zeven criteria zijn voorgesteld om een causaliteit te bewijzen van de medicamenteuze nevenwerkingen. Slechts systemisch toegediend pamidronaat beantwoordt aan deze criteria.

Pamidronaat heeft nu zijn vaste plaats in de behandeling van bepaalde aandoeningen, en het herkennen van de oftalmologische nevenwerkingen wordt nu essentieel voor de behandelende geneesheer om de diagnose te stellen en de toediening van het verantwoordelijke product te stoppen.

RÉSUMÉ

Les effets secondaires de l'acide pamidronique sont rares mais bien documentés. Le pamidronate, un inhibiteur de résorption osseuse utilisé dans la prise

en charge d'hypercalcémie tumorale secondaire et de la maladie de Paget, est rapporté être la cause de conjonctivites, uvéites antérieures et infrequemment d'épisclérites et de sclérites.

L'hypothèse proposée est qu'il s'agit d'un phénomène allergique ou immunologique causé par la formation de complexes immuns. Il n'est pas clair pourquoi l'uvéée est le tissu cible. La réponse inflammatoire aiguë ne semble pas en relation avec la dose du produit, ni la voie d'administration, ni l'activité de la maladie de Paget ou de la malignité.

Nous rapportons deux cas d'uvéite postérieure induits par le pamidronate, respectant le 'Guide de fiabilité de la causalité des effets secondaires suspects de l'OMS'.

L'uvéite et la sclérite ont été décrites en association à une variété de types de médicaments topicaux, péri-oculaires en intra-oculaires. Sept critères ont été proposés pour établir la causalité de ces effets secondaires médicamenteux. Uniquement les biphosphonates administrés de manière systémique répondent aux sept critères.

Sachant que les biphosphonates ont leur place dans le traitement de différentes pathologies, il est important de connaître les effets secondaires oculaires afin de poser un diagnostic rapide et d'interrompre l'administration de l'agent causal.

KEY-WORDS

Pamidronate, posterior uveitis, scleritis, adverse effects

MOTS-CLÉS

Pamidronate, uvéite postérieure, sclérite, effets secondaires

INTRODUCTION

Pamidronate disodium (3-amino-1-hydroxy-propylidene-1, 1-biphosphonate pentahydrate), is a second-generation aminobiphosphonate.

Biphosphonates are analogues of pyrophosphate that bind to hydroxy-apatite at sites of bone remodelling.

The major effects of the biphosphonates on bone are to inhibit skeletal and extraskelatal calcification and to act like inhibitors of osteoclastic bone resorption by binding to hydroxy-apatite crystals.

The consequences are that fewer functional osteoclasts are available for recruitment to erosion sites, and the activation of new remodelling sites may be decreased.

Biphosphonates are approved for treatment of complications of osteolytic bone metastases (in breast cancer), hypercalcemia, multiple myeloma stage III, Paget's disease, and vertebral fractures in osteoporosis (1).

Pamidronate (Aredia®) is reported to cause conjunctivitis, anterior uveitis (2,7,10,15), episcleritis (11,16), scleritis (5), nerve palsy (8), ptosis (8), retrobulbar neuritis (3) and idiopathic orbital inflammation (15).

Although uncommon, the incidence of pamidronate-induced ocular complications was estimated at 0.046% in a drug surveillance study (8) and at 1% in a therapeutic trial in 400 patients (17).

Only the biphosphonates containing a nitrate derivative have been reported to induce ocular adverse effects, with cross-reactions between these different drugs (14).

More recently developed oral aminobiphosphonates have also been associated with scleritis (9, 13).

We present two cases of posterior uveitis confirmed by rechallenge and dechallenge with pamidronate, following the WHO Causality Assessment Guide of Suspected Adverse Reactions (5).

PATIENTS AND METHODS

We report two cases of pamidronate-induced conjunctivitis, uveitis and scleritis, both occurring in February 2002.

CASE REPORTS

CASE 1 G A 03/08/1939

The patient is known with a prostate carcinoma in the stage T3G2N+M+. In 1998, he had a trans-urethral prostate resection. At the moment of first contact, he was taking Eulexin[®]/Decapeptyl[®], Durogesic[®] 75, Estracyt[®] 4 and Rivotril[®]. On 28/02/02, radiotherapy was started for bone metastasis in the right hip and in T3-T7. On 04/03/02, intravenous Aredia[®] 60 mg was started for persistent pain. On 06/03/02, the patient developed conjunctivitis in the left eye, which was treated locally. On 11/03/02, a second treatment with Aredia[®] 60 mg was given. On 13/03/02, uveitis in the left eye was diagnosed, and treated with Cocaine 2 drops for synechiolysis, Atropine 2 drops, Pred Forte[®] one drop/hour. On 18/03/02, we had an echographic suspicion of scleritis of the left eye (fig. 1). The treatment was modified to Pred Forte[®] 6 drops a day and a non-steroidal anti-inflammatory drug for the pain. On 08/04/02, a third

treatment with Aredia[®] 60 mg was administered, with a recurrence of anterior uveitis in the left eye on 10/04/02. We started Pred Forte[®] 6/d again. At this moment, the drug-induced adverse reaction was suspected and we advised to stop Aredia[®]. No further episodes of inflammation were noted.

CASE 2 T G 20/09/1932

This patient was diagnosed on 09/02/02 with a Prostate Carcinoma stage T4N+M+. The following treatment was started: Estracyt[®], Dalfagan[®], Zantac[®], Lopressor[®], Dexamethasone[®]. On 14/02/02, Aredia[®] 60 mg was started for disseminated bone metastases. On 16/02/02, he developed conjunctivitis in the left eye. The initial local treatment, started by the general practitioner (non-steroidal anti-inflammatory eye-drops), didn't work and we saw the patient with severe anterior uveitis on 21/02/02. We performed a diagnostic vitrectomy with collection of microbiological samples and administrated intra-vitreous Vancomy-

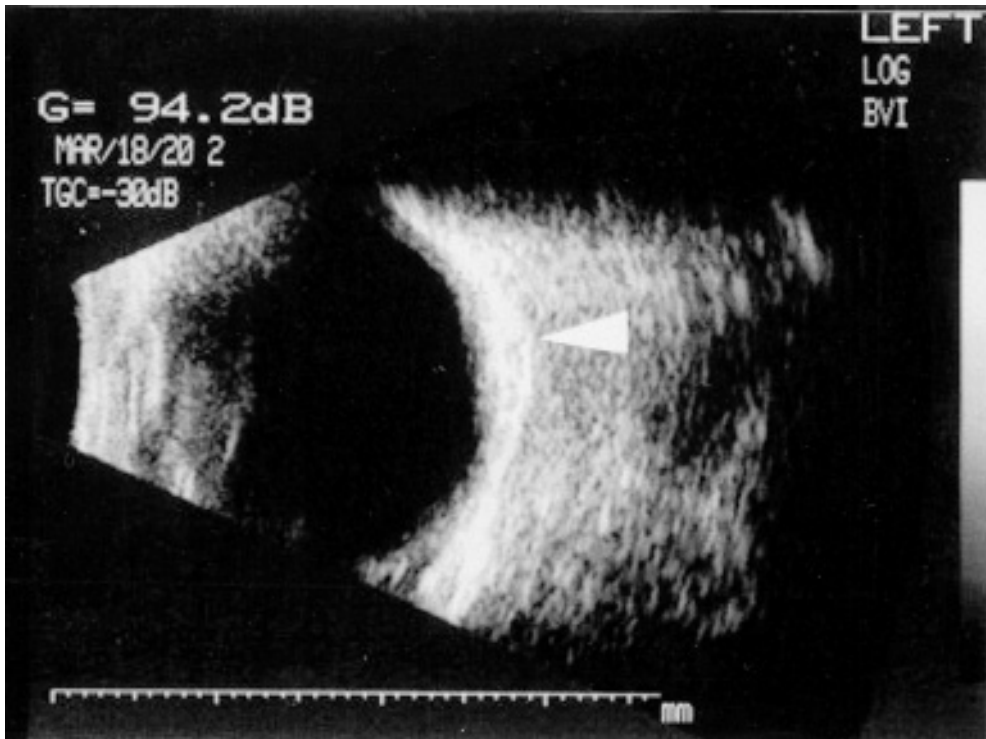


Fig 1. Echographic image of suspicious posterior scleritis

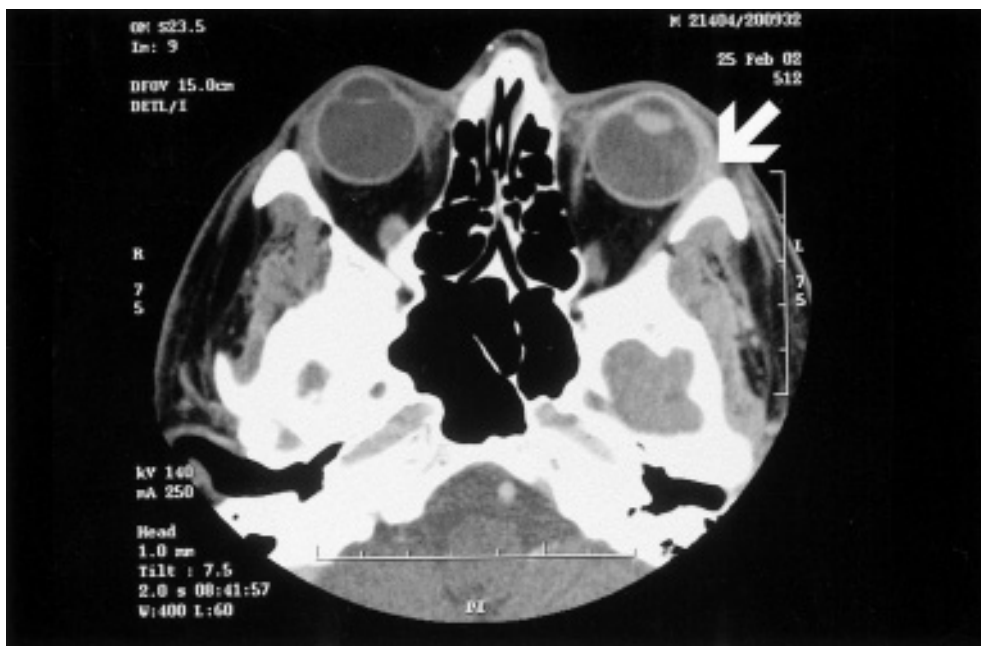


Fig 2. CT-scan image of possible posterior scleritis of left eye

cin and Tobramycin as endogenous panophthalmitis was suspected clinically. A topical therapy of corticosteroids combined with antibiotics (Tobradex® guttae) was started. CT-scan of the orbit showed the possibility of a temporal scleritis (fig.2). Because of the general condition, Aredia® 60 mg was given on 25/03/02 and 25/04/02, and this under cover of Tobradex® 4/d. On 08/05/02, we decided to stop the topical corticotherapy. Two days later, on 10/05/02, the patient developed an anterior uveitis in the left eye, with a rapid reaction to topical corticotherapy. Aredia® couldn't be stopped and was carefully administrated on the 25/05/02 and 26/06/02 at a dose of 60 mg under cover of Pred Forte® 4/d. No reaction was seen. In August 2002, the patient died from his general oncological condition.

DISCUSSION

The WHO Causality Assessment Guide of Suspected Adverse Reactions classifies the reported drug-related events into 6 categories: "certain", "probable/likely", "possible," "unlikely", "conditional/unclassified", and "un-assessible/unclassifiable" (5).

The three main criteria in the WHO Classification Assessment Guide of suspected Adverse Reactions are

- 1/ plausible time relationship to drug administration,
- 2/ positive rechallenge-dechallenge data
- 3/ the absence of other drugs or chemicals or concurrent disease that could explain the adverse effects.

The "certain" category includes a plausible time relationship to drug administration and that the adverse effects cannot be explained by concurrent disease or other drugs or chemicals. Dechallenge data are necessary and rechallenge data should be positive. "Probable" is the same as "certain" without positive rechallenge data. "Possible" is an adverse event in a reasonable time sequence to administration of the drug but could be explained by concurrent disease or other drugs or chemicals. Positive dechallenge data are lacking or unclear in this category.

Only systemically administered biphosphonates meet all seven criteria proposed by Naranjo et al to establish causality for uveitis (10, 11). The seven criteria for an adverse event are the following: a frequently described event that is well

documented, the event improves upon withdrawal of the drug, other possible causes for the event have been excluded, the adverse event is documented by objective evidence, the event becomes more severe when the dose of the drug is increased, the adverse event should occur in a given patient with similar drugs, the event should recur on rechallenge with the suspected drug.

In the first case, the adverse ocular events associated with pamidronate disodium had a very plausible time relationship to drug administration with occurrence of respectively conjunctivitis and anterior uveitis within 48 hours.

The posterior uveitis and possible scleritis were echographically diagnosed some 7 days after the second administration, when the patient was already under treatment for anterior uveitis.

Because of persistent bone pain, it was decided to administer a third treatment with pamidronate 60 mg, with positive rechallenge manifesting as anterior uveitis.

It was then decided to stop the aminobiphosphonates, and the dechallenge data confirmed the causality.

We treated the second patient initially as an endogenous panophthalmia with intravitreal Vancomycin and Tobramycin, considering his general condition after chemotherapy treatment. On the CT-scan we noticed possible posterior scleritis and were thinking more in the direction of toxicity of chemotherapy to explain the clinical picture. The microbiological cultures remained sterile.

It was only when we stopped the corticosteroid treatment and with the development of anterior uveitis that we linked the pamidronate disodium with the first episodes of severe posterior uveitis. We couldn't stop the pamidronate treatment because of the general condition, and under cover of corticotherapy, the patient didn't develop any further adverse effects.

In posterior scleritis, the signs are variable and depend primarily on the site of maximal involvement. Associated anterior scleritis is present in about 80% of all cases.

It is hypothesized that an allergic or immunologic phenomenon caused by drug-induced im-

mune complex formation is at fault. The reason why the uvea is a target organ is unclear. In the differential diagnosis we have to exclude the following causes and associations: idiopathic, surgically induced, rheumatic disorders, connective tissue disorders, enteropathies, systemic vasculitides, granulomatous diseases and skin diseases.

A recent report described 17 cases of unilateral scleritis and one case of bilateral scleritis occurring usually within 6 hours to 2 days after intravenous pamidronate disodium administration (5). In the same study, six patients had positive rechallenge testing with the scleritis occurring after a repeated drug exposure. Other ocular side effects with positive rechallenge data, associated with pamidronate disodium, included blurred vision, non-specific conjunctivitis, ocular pain, bilateral anterior uveitis and episcleritis.

The acute inflammatory response seems unrelated to the dose of the drug, the way of administration, or the activity of Paget's disease or malignancy.

CONCLUSION

The two cases presented here are examples of ocular adverse reactions induced by aminobiphosphonates as we had a very plausible time relationship to drug administration and positive dechallenge as well as rechallenge data. The absence of other drugs or chemicals or of concurrent disease that could explain the adverse effects confirms the hypothesis.

Uveitis and conjunctivitis are well-documented adverse effects of biphosphonates.

Pamidronate disodium can cause vision-threatening diseases, which may require discontinuing or adapting the drug in some uveitis cases and all the cases of scleritis.

BIBLIOGRAPHY

- (1) COUKELL A.J., MARKHAM A. – Pamidronate, a review of its use in the management of osteolytic bone metastases, tumour-induced hypercalcemia and Paget's disease of bone. *Drugs Aging* 1998; 149-68.
- (2) DE S., MEYER P., CRISP A.J. – Pamidronate and uveitis. *Br J Rheumatol* 1995; 34: 479.

- (3) DES GROTTES J.M., SCHROOYEN M., DUMON J.C., BODY J.J. – Retrobulbar optic neuritis after pamidronate administration in a patient with a history of cutaneous porphyria. *Clin Rheumatol* 1997; 93-5.
- (4) EDWARDS I.R., BIRIELL C. – Harmonisation in pharmacovigilance. *Drug Safety* 1995; 10:93-102.
- (5) FRAUNFELDER F.W., FRAUNFELDER F.T., JENSVOLD B. – Scleritis and other ocular side effects associated with pamidronate disodium. *Am J Ophthalmol* 2003; 135: 219-222.
- (6) FRAUNFELDER F.W., ROSENBAUM J.T. – Drug-induced uveitis. Incidence, prevention and treatment. *Drug Saf* 1997; 17: 197-207.
- (7) GHOSE K., WATERWORTH R., TROLOVE P., HIGHTON J. – Uveitis associated with pamidronate. *Aust N Z J Med* 1994; 24: 320.
- (8) MACAROL V., FRAUNFELDER F.T. – Pamidronate disodium and possible ocular adverse drug reactions. *Am J Ophthalmol* 1994; 118: 220-4.
- (9) MBEKEANI J.N., SLAMOVITS L., SCHWARTZ B.H., SAUER H.L. – Ocular inflammation associated with alendronate therapy. *Arch Ophthalmol* 1999; 117: 837-8.
- (10) MOORTHY R.S., VALLURI S., JAMPOL L.M. – Drug-induced uveitis. *Surv Ophthalmol* 1998; 42: 557-70.
- (11) NARANJO C.A., BUSTO U., SELLERS E.M., et al. – A method for estimating the probability of adverse drug reactions. *Clin Pharmacol Ther* 30:239-245, 1981.
- (12) O'DONNELL N.P., RAO G.P., AGUIS-FERNANDEZ A. – Paget's disease: ocular complications of disodium pamidronate treatment. *Br J Clin Pract* 1995; 49: 272-3.
- (13) PRESCRIRE REDACTION. Ocular adverse effects of alendronic acid. *Rev Presc* 2001; 21 (213): 37.
- (14) REY et al. Uveitis, an under-recognized adverse effect of pamidronate. Case report and literature review. *Joint Bone Spine*; 2000; 67: 337-40.
- (15) RYAN P.J., SAMPATH J. – Idiopathic orbital inflammation following intravenous pamidronate. *Rheumatology* 2001; 40: 956-7.
- (16) SIRIS E.S. – Biphosphonates and iritis. *Lancet* 1993; 341: 436-7.
- (17) STEWART G.O., STUCKEY B.G., WARD L.C., PRINCE R.L., GUTTERIDGE D.H., CONSTABLE I.J. – Iritis following intravenous pamidronate. *Aust N Z J Med* 1996; 26: 414-5.
-
- Correspondence to:*
Prof.dr.Thierry Zeyen
Dept. of Ophthalmology
A.Z. Middelheim
Lindendreef 1
B-2020 Antwerpen
Belgium
Tel: 0032 3 2803105
E-mail: thierry.zeyen @ skynet.be