

ECTOPIA LENTIS AND CENTRAL SEROUS CHORIORETINOPATHY IN A PATIENT WITH A MARFANOID HABITUS. A CASE REPORT

VEKEMAN E.* , DUMOULIN D.** ,
HERZEEL R.*

ABSTRACT

We report a case of ectopia lentis and central serous chorioretinopathy in a young female patient with several manifestations of Marfan syndrome in the skeletal, cardiovascular and dermatological systems. We can't conclude however that these two ocular abnormalities are linked.

RÉSUMÉ

Nous présentons un cas d'ectopie du cristallin et de choriorétinite séreuse centrale chez une jeune patiente avec des manifestations du syndrome de Marfan sur le plan squelettique, dermatologique et cardiovasculaire. Une conclusion sur l'association de ces deux pathologies oculaires n'est pour autant pas prouvée par ce cas.

SAMENVATTING

We stellen een casus voor van lenssubluxatie en centrale sereuze chorioretinopathie bij een jonge vrouw met tekens van Marfan syndroom ter hoogte van huid, skelet en cardiovasculair systeem. We kunnen

echter niet met zekerheid besluiten dat deze twee oogandoeningen geassocieerd zijn.

KEY-WORDS

Marfan syndrome, ectopia lentis, diffuse retinal pigment epitheliopathy, central serous chorioretinopathy

MOTS-CLÉS

syndrome de Marfan, ectopie du cristallin, épithéliopathie rétinienne diffuse, choriorétinite séreuse centrale

.....

* *Department of Ophthalmology, Academisch Ziekenhuis, Vrije Universiteit Brussel, Belgium*

** *Department of Ophthalmology, St. Augustinus Kliniek, Veurne, Belgium*

received: 12.08.03

accepted: 20.10.03

INTRODUCTION

Central serous chorioretinopathy (CSCR) is defined as an idiopathic neurosensory retinal detachment attributed to a leak or leaks from the level of the retinal pigment epithelium. The pathogenesis of the disorder is not precisely known. Serous retinal detachment, retinal pigment epithelial detachment or dysfunction, and choroidal hyperpermeability are demonstrated by fluorescein and indocyanine green angiography (4). ERG and EOG findings and visual field testing can be normal or disturbed depending on severity and extent of the disease but have no additional diagnostic value (1).

Marfan syndrome (MFS) is an inheritable disorder of the connective tissue. The major abnormalities occur in the ocular, skeletal, and cardiovascular systems, with variable expression in different patients (12). Ectopia lentis (EL) is a clinical manifestation of MFS or exists as an independent phenotype (2). Different mutations affecting the fibrillin gene on chromosome 15 result in a phenotype-spectrum varying from MFS to EL (2).

We report a case of ectopia lentis and central serous chorioretinopathy in a young female patient. The several ocular, skeletal, cardiovascular and dermatological manifestations of MFS present in our reported patient, are named a marfanoid habitus.

CASE REPORT

A 35-year old woman consulted the department of ophthalmology of the University of Brussels in September 2002 for a decreased visual acuity in her left eye.

Her ophthalmological history was remarkable. In 1996 a spontaneously resolving deterioration of visual acuity of her left eye occurred.

In July 2002 she consulted her ophthalmologist for a central scotoma in her right eye. An ophthalmoscopic examination performed by her ophthalmologist revealed multifocal exudative lesions in the posterior pole of the right eye and some pigment epithelial changes in the macular region of the left eye. Fluorescein angiography showed the presence of a few diffusion points in the macular region and at the supero-temporal arcade and a serous pigment epithelial detachment nasally to the macula in the right eye. In her left eye some pigment epithelial alteration and minimal diffusion points in-framacular were revealed on fluorescein angiography. With a conservative management her vision recovered from 6/10 to 8/10 in her right eye.

A few weeks prior to our first examination she consulted her ophthalmologist again, this time for decreased vision in the left eye. Because of school exams she was under high psychological stress. Her visual acuity was 5/10 in the left eye. A serous retinal detachment in her left

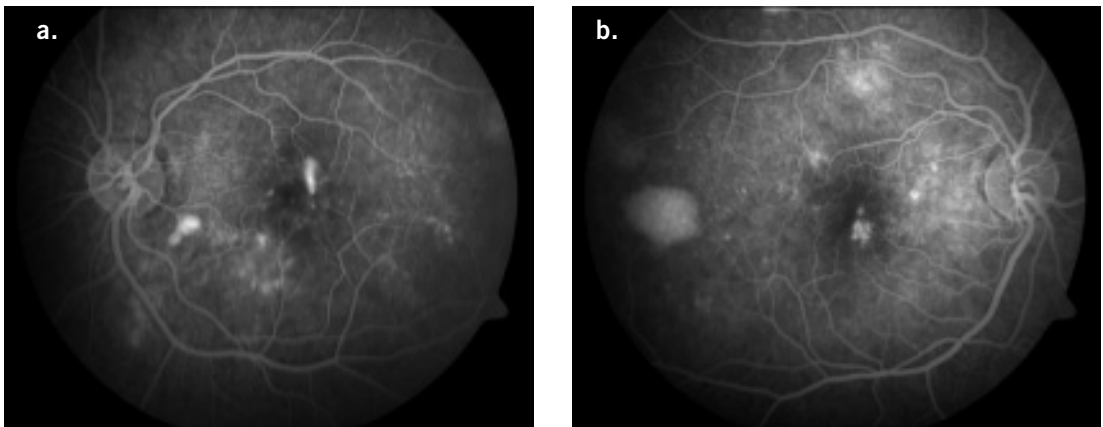


Fig. 1. Fluorescein angiography in September 2002.

a. Left eye: smoke-stack appearance of CSCR.

b. Right eye: serous pigment epithelial detachment and pigment epithelial changes.

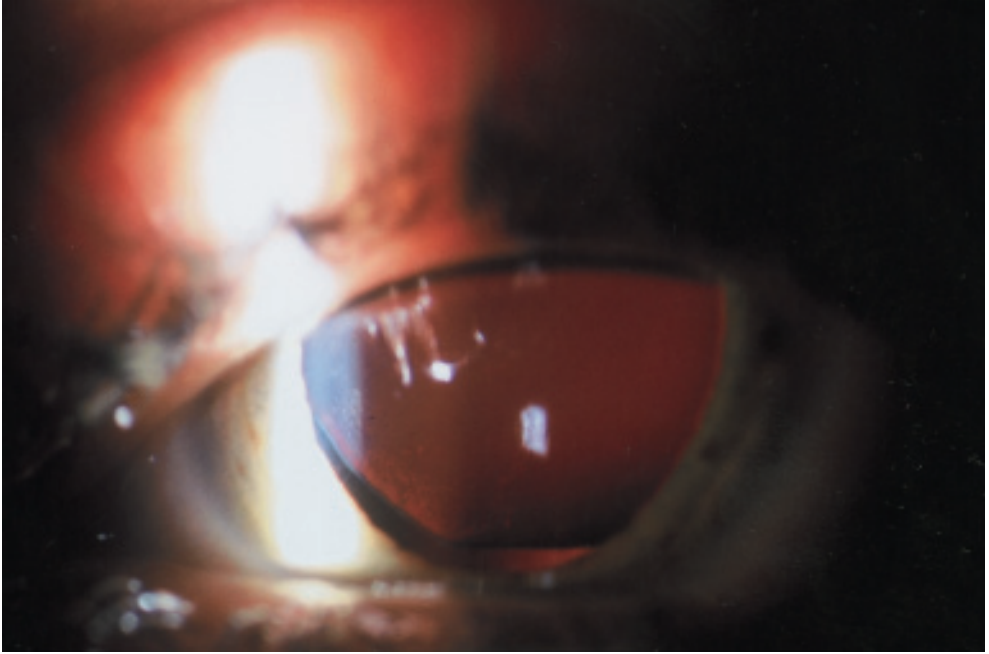


Fig. 2. Supero-temporal subluxation of the crystalline lens of the eye.

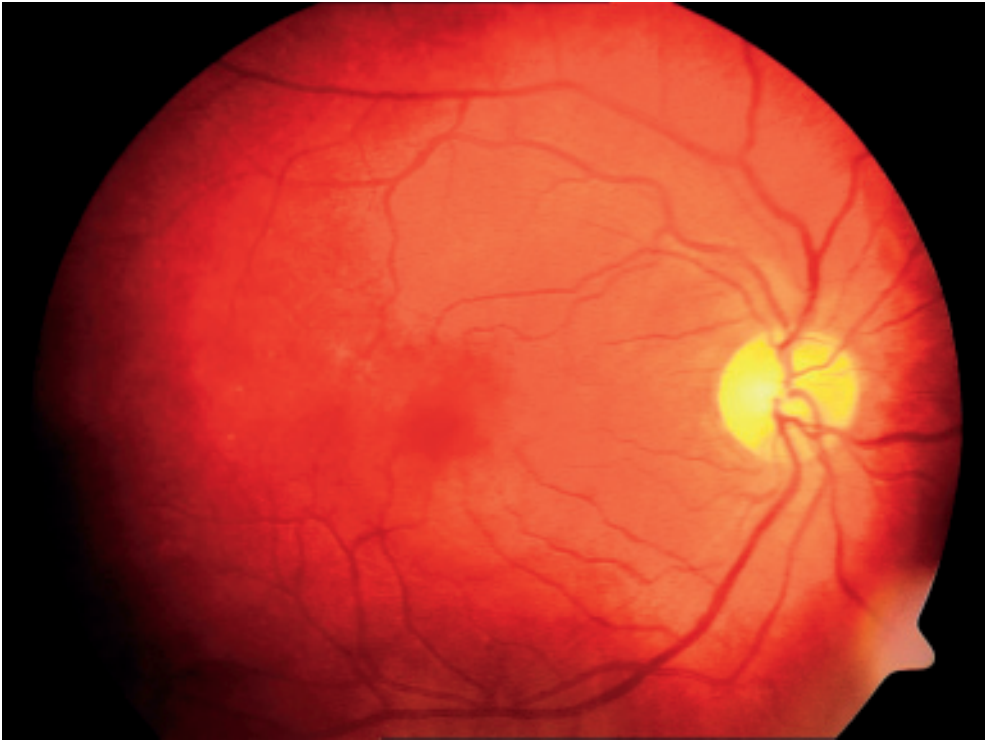
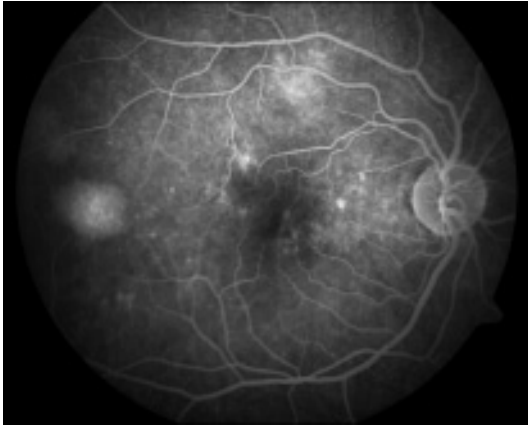
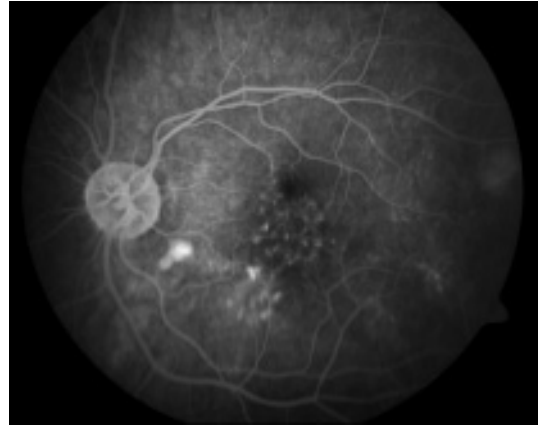


Fig. 3. Serous retinal detachment in the right eye.



a. Right eye



b. Left eye.

Fig. 4. Fluorescein angiography in May 2003.

Focal retinal pigment epithelial defects and serous pigment epithelial detachment indicative of past episodes.

macula was diagnosed. She was treated with oral (32mg of methylprednisolon a day, diminished over 1 month) and subconjunctival (1 injection) corticosteroids. There was a further decrease of visual acuity.

Examination in our department in September 2002 demonstrated a visual acuity of only 2/10 in the left eye. Her medical and family history were unremarkable. She was only taking an oral contraceptive and there was no history of chronic corticosteroid use. Again increased psychological stress was present. On a fluorescein angiogram a smoke-stack appearance of CSCR was noted in the left eye together with the previously described pigment epitheliopathy (fig. 1.a.). In the right eye fluorescein angiography showed a serous pigment epithelial detachment nasally to the macula and macular pigment epithelial changes without leakage indicative of a prior episode (fig. 1.b.). There was no subjective improvement of the vision of the left eye following a conservative management. Slit-lamp examination revealed a bilateral supero-temporal subluxation of the crystalline lens (fig. 2.) without increased ocular axial length (axial length of right eye: 21.22mm, left eye: 21.43mm) or abnormal flattening of the cornea.

The lens subluxation, her long limbs and fingers and her height of 1m82 made us suspect MFS and a genetic counselling was requested. Screening for the diagnostic criteria for MFS

identified skeletal, cardiovascular and dermatological abnormalities together with the ectopia lentis. A positive thumb sign, retrognathia, high arched palate, prolapse of the mitral valve with minor mitral and tricuspidal insufficiency and striae on the thighs were found. Blood samples were taken for DNA analysis.

Investigations including a chest X-ray, full blood count, erythrocyte sedimentation rate, HLA-B27, rheumatoid factor, anti-nuclear antibodies, complement levels, syphilis serology, toxoplasma serology and rubella serology were normal.

In January 2003 she came back complaining of decreased vision of the right eye. The best-corrected visual acuity was 5/10 in the right eye and 4/10 in the left eye. On funduscopy some pigment epithelial changes in the macular region of the left eye were seen. In the right eye a serous retinal detachment (fig. 3.) with recurrence of the diffusion points inferior of the foveola was revealed on fluorescein angiography. The left eye presented pigment epithelial changes without leakage indicative of prior episode. The eyes were not treated.

On her last visit in May 2003 visual acuity was 7/10 in both eyes. Automated perimetry, electroretinography, electro-oculography and visual evoked responses were normal. On Goldmann perimetry a concentric narrowing of approximately 10% was found. Ophthalmoscopic examination showed pigment epithelial

changes in both eyes without apparent leakage on fluorescein angiography. Focal retinal pigment epithelial defects and serous pigment epithelial detachment indicative of past episodes were present (fig. 4.a., fig. 4.b.).

DISCUSSION

Marfan syndrome (MFS) is an autosomal dominant connective tissue disorder characterized by variable phenotypic manifestations mainly in cardiovascular, skeletal, and ocular systems (2). Ocular features are lens subluxation, angle anomaly, retinal detachment associated with lattice degeneration, hypoplasia of the dilator pupillae, flat cornea, blue sclera and axial myopia (6). Ectopia lentis (EL) is a displacement of the lens caused by stretching or disruption of the lenticular zonular filaments. It exists as a clinical manifestation of MFS but also as an independent autosomal dominant phenotype (2).

Current criteria for the diagnosis of MFS are reported by De Paepe et al. (3). While our patient had no confirmed family history, a major manifestation of the ocular system and involvement of the skeletal, cardiovascular and dermatological systems were determined. These manifestations are suggestive of MFS but the clinical criteria (3) were thereby not met. DNA analysis was started to examine the presence a mutation in the fibrillin gene on chromosome 15 (FBN 1). Within several months results of this DNA analysis will be available. Both MFS and ectopia lentis (with or without minor skeletal changes) are linked to the FBN 1 (2). Different mutations affecting the FBN 1 result in a phenotype-spectrum varying from MFS to EL (2). It is likely that such a disorder in the microfibrillar system of connective tissue will be identified in this case. Since a tendency to late onset aortic dilatation and/or dissection is an occasional feature, it is recommended that patients with predominant ectopia lentis be screened with echocardiography initially and at regular intervals throughout their lifetime (2). Other causes of ectopia lentis (6) such as trauma, buphthalmos, anterior uveal tumours, hypermature cataract, Weill-Marchesani syndrome, homocystinuria, hyperlysinaemia, sulphite oxidase deficiency, Stickler syndrome,

Ehlers-Danlos syndrome and aniridia were excluded in this case.

The patient in this report also had bilateral central serous chorioretinopathy (CSCR). It is generally believed that diffuse retinal pigment epitheliopathy, first reported by Zweng and Little in 1977 and also called chronic or atypic CSCR, is a distinct subtype of CSCR. In a study by Tittl et al. (9) classic CSCR was defined as a localized sensory retinal detachment of the macula caused by one or several discrete isolated leaks at the level of the retinal pigment epithelium, which were termed "focal leaks". These focal leaks typically were quite evident during fluorescein angiography. Diffuse retinal pigment epitheliopathy was defined as a sensory retinal detachment associated with areas of pigment epithelial atrophy and pigment mottling that, during fluorescein angiography, displayed areas of granular hyperfluorescence containing one or many subtle leaks (9). In our case fluorescein angiography at different times showed features of both subtypes of CSCR.

CSCR is a poorly understood disorder characterized by serous retinal detachment, retinal pigment epithelial detachment or dysfunction, and choroidal hyperpermeability as demonstrated by fluorescein and indocyanine green angiography (4).

The bilateral, chronic, widespread disturbance of the retinal pigment epithelium (RPE) in chronic CSCR suggests an extensive and continuous disorder with generalized involvement of the RPE associated with a diffuse choroidal vascular disease (11). Fundus appearances are similar in familial and nonfamilial chronic CSCR lesions. Study of the familial type of chronic CSCR suggests that tendency to develop this type of choroidal vasculopathy may be genetically determined. Actually no conclusions with regard to the mode of inheritance are made. In our case family history was unremarkable. Weenink et al. however found that family history is unreliable and a systematic ophthalmological investigation is required to detect affected relatives in familial chronic CSCR (11). Because no relatives of our patient were examined no conclusion can be made whether this is a familial chronic CSCR or not.

There is a variety of predisposing factors that have been reported to be associated with development of CSCR, including emotional strain,

type A personality, pregnancy, organ transplantation, lupus erythematosus, increased levels of endogenous corticosteroids, hypertension and psychopharmacological medication use (9). Psychological stress seems to be the predisposing factor in this case. Corticosteroids use, through a number of routes (such as systemic, inhaled, intranasal, and epidural administration of corticosteroids) has been described as inducing CSCR (5). This patient was prescribed corticosteroids for CSCR before coming to our office. She denied other chronic corticosteroid use. We presume that in this case the development of bilateral diffuse retinal pigment epitheliopathy was not induced by corticosteroids, but that corticosteroids were responsible for the exacerbation of one episode of the disease. It is generally believed that corticosteroids should be avoided as a form of treatment of CSCR (9). CSCR is a condition typically affecting males from 20 to 45 years old. The largest published series of CSCR in women by Perkins et al. (8) found that recurrence and duration longer than 5 months are associated with incomplete recovery, as in our case. Whether early laser treatment of leakage may prevent further progression or recurrences of the disease and whether photocoagulation treatment in the late stage of the disease improves the long-term visual prognosis, is still being debated (7, 10). We believe this case report to be the first one describing ectopia lentis and central serous chorioretinopathy in a patient with a marfanoid habitus. We can't conclude however that the ocular abnormalities present in this case are linked. Only further reports and examinations of other patients with ectopia lentis and central serous chorioretinopathy will allow us to see if an association between those two diseases exist.

REFERENCES

- (1) BALE F., LEROY M.-P., HACHE J.-C., FALLAS P. – Epithéliopathie rétinienne diffuse. A propos de quatre cas. Bull. Soc. Opht. France 1988; 12:1505-1509.
- (2) COMEGLIO P., EVANS A.L., BRICE G., COOLING R.J., CHILD A.H. – Identification of FBN 1 gene mutations in patients with ectopia lentis and marfanoid habitus. Br J Ophthalmol 2002; 86:1359-1362.

- (3) DE PAEPE A., DEVEREUX R.B., DIETZ H.C., HENNEKAM R.C.M., PYERITZ R.E. – Revised diagnostic criteria for the Marfan syndrome. Am J Med Genet 1996; 62:417-426.
- (4) HAIMOVICI R., RUMELT S., MELBY J. – Endocrine abnormalities in patients with central serous chorioretinopathy. Ophthalmology 2003; 4:698-70.
- (5) IIDA T., SPAIDE R.F., NEGRAO S.G., CARVALHO C.A., YANNUZZI L.A. – Central serous chorioretinopathy after epidural corticosteroid injection. Am J Ophthalmol 2001; 132:423-425.
- (6) KANSKI J.J. – Disorders of the lens. Clinical Ophthalmology, Butterworth Heinemann, Heine 1999-fourth ed; 156-182.
- (7) KANYANGE M.L., DE LAEY J.J. – Long-term follow-up of central serous chorioretinopathy (CSCR). Bull. Soc. belge Ophtalmol. 2002; 284:39-44.
- (8) PERKINS S.L., KIM J.E., POLLACK J.S., MERRILL P.T. – Clinical characteristics of central serous chorioretinopathy in women. Ophthalmology 2002; 109:262-266.
- (9) TITTL M.K., SPAIDE R.F., WONG D., PILOTTO E., YANNUZZI L.A., FISHER Y.L., FREUND B., GUYER D.R., SLAKTER J.S., SORENSON J.A. – Systemic findings associated with central serous chorioretinopathy. Am J Ophthalmol 1999; 128:63-68.
- (10) WANG M.S.M., SANDER B., LARSEN M. – Retinal atrophy in idiopathic central serous chorioretinopathy. Am J Ophthalmol 2002; 133:787-793.
- (11) WEENINK A.C., BORSJE R.A., OOSTERHUIS J.A. – Familial chronic central serous chorioretinopathy. Ophthalmologica 2001; 215:183-187.
- (12) WOERNER E.M., ROYALTY K. – Marfan syndrome. What you need to know. Postgrad Med 1990; 87:229-236

.....

Request for reprints:
 Elke Vekeman, MD
 Department of Ophthalmology,
 Academisch Ziekenhuis,
 Vrije Universiteit Brussel
 Laarbeeklaan 101,
 B-1090 Brussels
 Belgium
 e-mail: elke.vekeman@az.vub.ac.be