

GRADENIGO SYNDROME: A CASE-REPORT

PIRON K., GORDTS F.**, HERZEEL R.**

ABSTRACT

We report a case of sixth nerve palsy as a rare complication of acute otitis media (apical petrositis). The clinical triad of acute otitis media, pain in the distribution of the fifth cranial nerve and sixth nerve palsy is known as Gradenigo syndrome.

RÉSUMÉ

Nous rapportons un cas de paralysie du n.VI comme complication rare d'une otite moyenne aiguë (pétrosite apicale). La triade clinique d'otite moyenne aiguë, douleur dans la région du n.V et paralysie du VI est connue sous le nom de syndrome de Gradenigo.

KEY-WORDS

Gradenigo syndrome, acute otitis media, *Fusobacterium necrophorum*, sixth nerve palsy

MOTS-CLÉS

Syndrome de Gradenigo, otite moyenne aiguë, *Fusobacterium necrophorum*, paralysie du n. VI

.....

- * *Department of Ophthalmology, Academisch Ziekenhuis, Vrije Universiteit Brussel, Belgium.*
** *Department of Otorhinolaryngology, Academisch Ziekenhuis, Vrije Universiteit Brussel, Belgium.*

received: 22.09.03

accepted: 18.10.03

INTRODUCTION

The syndrome, first described by Gradenigo in 1907, consists of the clinical triad of acute otitis media, unilateral pain in regions innervated by the first and second branch of the trigeminal nerve, and ipsilateral abducens nerve paralysis [10]. These cranial nerve dysfunctions are caused by osteitis of the petrous apex (petrous apicitis) and are very rare complications of otitis media, especially since the widespread use of antibiotics [2,3,13,15,18]. However, in recent years, a rise in the incidence of intratemporal and intracranial complications of purulent middle ear infections have been mentioned in the literature, mainly in younger children [1,5]. The trigeminal nerve ganglion and the abducens nerve are separated from the petrous apex only by dura mater and are therefore vulnerable to any inflammatory process occurring in this region [4,8].

We report a case of Gradenigo syndrome caused by *Fusobacterium necrophorum*.

CASE REPORT

A 5-year-old girl was admitted to our hospital with a 2-week history of persisting moderate right ear pain, and a unilateral headache since 2 days localized to the right frontal and infra-orbital area. The night prior to the admission the mother noticed a sudden inability of lateral deviation of the right eye.

Her past medical history was significant only for recurrent otitis media.

Ten days before admission the otitis media was treated by topical (polymyxine B/neomycine/fludrocortison) and oral (amoxicillin-clavulanate; 50 mg amoxicillin/kg/day p.o. in three divided doses) antibiotics. At admission there were no meningeal signs, there was a normal

facial motility and no fever. Facial pain was localized in the first and second branch of the right trigeminal nerve. The right abducens nerve palsy was confirmed by Lancaster test. (Fig.1) Visual acuity was 1.0 in both eyes. Ophthalmoscopy and biomicroscopy were normal. No afferent pupillary defect or papilloedema could be detected. Otorhinolaryngological examination revealed a right acute otitis media with a hyperaemic and bulging tympanic membrane. The left tympanic membrane was normal. There was no mastoid tenderness. Physical and neurological examinations were otherwise unremarkable.

Laboratory tests showed a white blood cell count of $9200/\text{mm}^3$, a platelet count of $508000/\text{mm}^3$, a sedimentation rate of 80 mm/hour and a C-reactive protein of 13.6 mg/l.

A right myringotomy was performed the day of the admission. Two days after the myringotomy a complete recovery of the headache was obtained.

Intravenous antibiotic treatment with amoxicillin-clavulanate (100 mg amoxicillin/kg/day i.v. in two divided doses) was initiated, and changed to ceftriaxon (100 mg/kg/day i.v. in one dose)

and metronidazol (35 mg/kg/day i.v. in three divided doses) as soon as the bacteriological results were known: the sample obtained by myringotomy revealed a rich culture of *Fusobacterium necrophorum*.

A computerized tomography (CT) scan showed a poorly pneumatized and clouded right temporal bone, however without signs of bone erosion.

Magnetic resonance imaging (MRI) excluded an additional intracranial abscess as well as thrombophlebitis of the sigmoid sinus. It confirmed an inflammation of the meninges around the right petrous apex as well as of the walls of the right sinus cavernosus. (Fig.2A and 2B)

Considering the unusual and potentially lethal nature of the culprit organism, a combined surgical and medical management was felt to be more appropriate than a purely medical treatment (see Discussion). A right attico-antromastoidectomy with insertion of a ventilation tube into the tympanic membrane was thus performed; intravenous treatment with the formerly mentioned antibiotics was continued for three weeks.

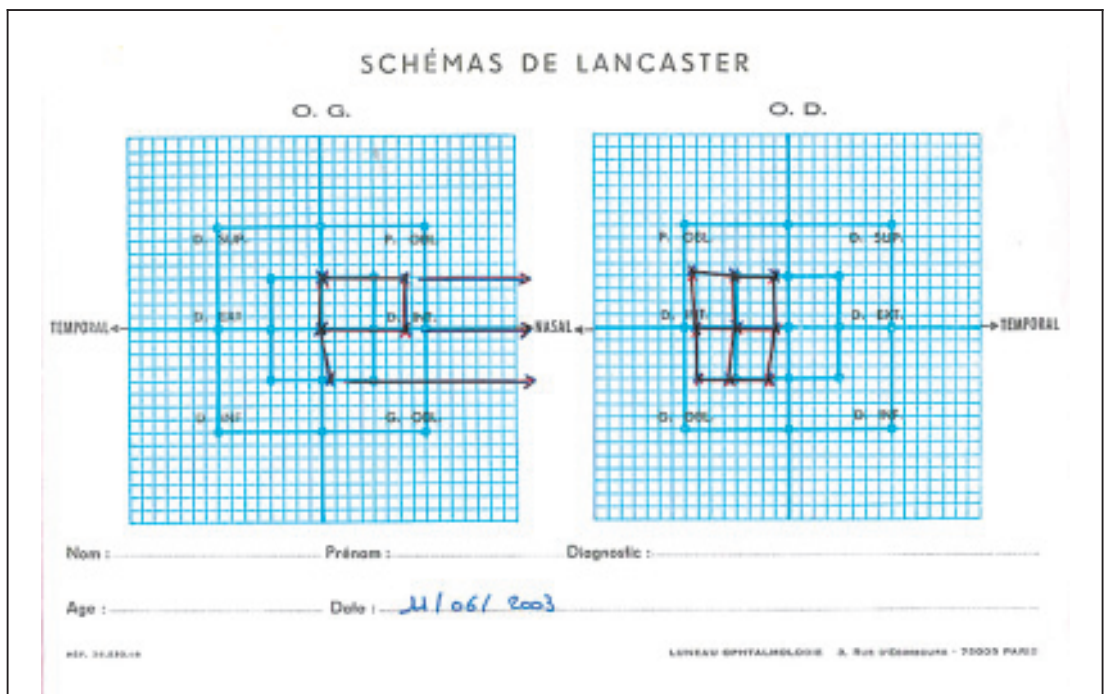


Fig. 1: Lancaster examination (on the day of admission) showing a right abducens paralysis.

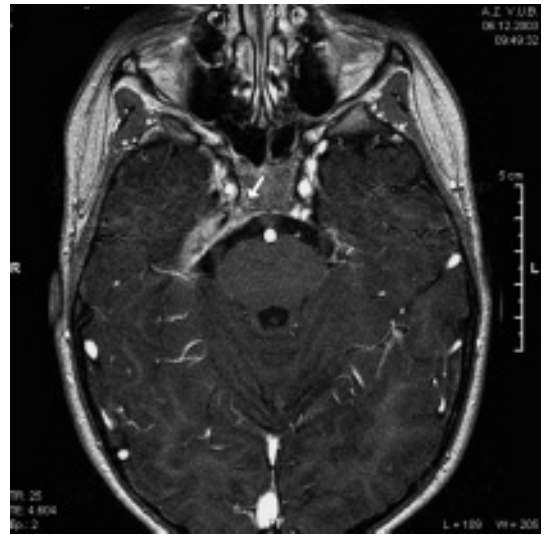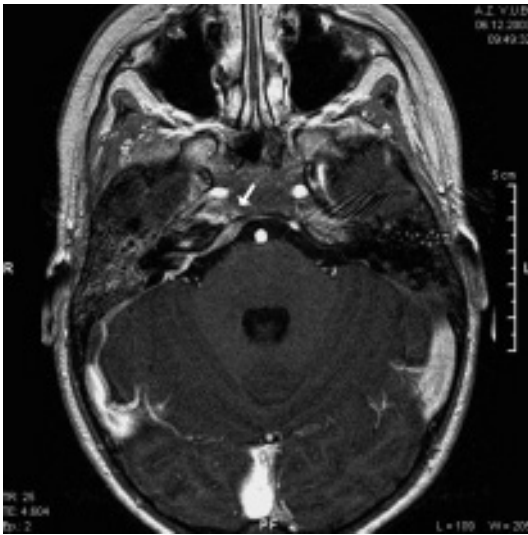


Fig. 2A and 2B: T1-weighted axial MR images showing a right mastoiditis and otitis media. It confirms an inflammation of the meninges around the right petrous apex and of the walls of the right sinus cavernosus.

Already within the first days after surgery an initially minute but steadily progressive improvement of the lateral deviation of the right eye was noticed. Ten days after surgery a Lancaster examination confirmed a partial recovery of the sixth nerve palsy.

The patient was discharged 3 weeks after the intervention with oral antibiotics (amoxicillin-clavulanic acid; 50 mg amoxicillin/kg/day p.o. in three divided doses) for one week.

On a follow-up examination, 6 weeks after the surgical intervention, a complete recovery of the abducens nerve palsy was noted on Lancaster test. Further ophthalmological examination was normal. Audiometrical follow-up showed a normal hearing. MR imaging demonstrated a normalisation of the signal at the level of the sinus cavernosus and the meninges around the petrous apex.

DISCUSSION

Acute otitis media is a frequent childhood disease, with a potential for intratemporal and/or intracranial complications [14]. With the advent of broad-spectrum antibiotics, the intracranial and intratemporal complications of infectious ear disease have become rare [20]. Although the incidence of complications associa-

ted with otitis media has decreased since the introduction of effective antimicrobial treatments, they still occur and their morbidity and mortality remain relatively high [1,5,9]. Children younger than 11 years form almost 50% of the total number of patients with complications [1]. The intratemporal complications of acute otitis media include mastoiditis, facial nerve paralysis, labyrinthitis, and rarely, acute petrositis [7]. Complications of petrous apicitis include cranial nerve palsies, meningitis, labyrinthitis, intracranial abscess formation, retropharyngeal abscess, venous sinus thrombosis, and death [11,16,19].

The air cells in the petrous apex, which communicate with the middle ear, provide a route for spreading of infection and may cause petrositis, petrous apicitis, or otogenic cavernous sinus thrombophlebitis [15]. While 80% of mastoid bones are pneumatized, only 30% of petrous bones have air cells extending to the apex [8]. The extent of pneumatization of the petrous apex is variable [15]. The spread of the infection from the middle ear to remote areas of the petrous bone can also occur by direct extension via fascial planes, vascular channels, or through bone [11]. Thus infections in the petrous apex may be life threatening because of the propensity to spread medially toward the meninges, cavernous sinus, and brain [8].

The triad of sixth nerve palsy, pain in the distribution of the fifth nerve, and otitis media is known as Gradenigo syndrome [10].

The neurological manifestations of Gradenigo syndrome are attributed to the involvement of the fifth and sixth cranial nerves that are only separated from the inflamed petrous apex by dura mater [7,8]. The inflammatory process spreads from the base (mastoid and middle ear) of the pyramid-shaped os petrosum to its top (petrous apex). This explains why the time interval between the onset of the otitis media and the manifestation of cranial nerve dysfunction varies between 1 week and 2-3 months [15]. Many patients diagnosed as having Gradenigo syndrome do not present with all three components [9]. Although abducens palsy is not always present in patients with petrositis, it is not an uncommon finding [16].

For the clinical diagnosis of petrositis the deep facial or ear pain appears to be the most useful symptom [11].

Imaging techniques in otogenic intracranial complications are considered as important diagnostic assets. Computerized tomography (CT) scans and magnetic resonance imaging (MRI) allow rapid and accurate diagnosis of intracranial complications of otitis media [14,20]. MRI and CT are required to identify the deep-seated petrous apex as the site of the inflammatory process [7,20]. CT can show inflammation and abscess formation in adjacent brain and extra-axial spaces, as well as swelling in the cavernous sinus [11]. MRI gives information concerning inflammatory changes in apical petrositis. Coronal post contrast T-1 weighted images are very helpful in showing the inflammation of selected cranial nerves, as well as the meninges at the petrous tip and adjacent to the lateral wall of the cavernous sinus [11].

The management of acute petrositis has progressively changed from radical surgery in all cases of petrous apicitis to less extensive surgical interventions (mastoidectomies without drainage of the petrous apex) combined with myringotomy, tube placement and intravenous antibiotics. Some suggest an even more conservative approach without mastoid surgery [7,9,15]. When conservative treatment fails or chronic ear disease is present, surgery is still indicated to ensure adequate drainage of the

mastoid and petrous bone [7,15,16]. The availability of such accurate diagnostic tools as CT and MRI together with potent antibiotics with good central nervous system penetration has permitted this drastic change in management [20].

In the presence of intratemporal and intracranial complications gram-positive cocci (streptococci / staphylococci) and gram-negative bacilli (*Pseudomonas aeruginosa*...) are the most important causative organisms. Anaerobes are noted in a lesser extend [5,19]. There is no real consistency with the organisms expected in uncomplicated acute otitis media such as *Streptococcus Pneumoniae*, *Haemophilus Influenzae*, *Moraxella catarrhalis* [5,19].

Fusobacterium necrophorum is a gram-negative, obligatory anaerobic, non-spore-forming, non-motile rod-shaped bacterium, belonging to the family Bacteroidaceae which is normally resident in the oropharynx, the gastro-intestinal and genito-urinary tract [6,17]. The virulence of *F. necrophorum* is partly a result of its toxin-producing ability [6]. The organism is implicated as an etiological agent in a variety of necrotic diseases, known collectively as Necrobacillosis [17]. Still today, and as suggested by the Greek origin of its name ("necrophorum" means "the one that bears death"), this organism is feared for its potential lethal nature. Previous experience with this organism by the present ENT co-author has influenced the decision toward a combined surgical/medical approach.

The differential diagnosis of Gradenigo syndrome includes tumours at the petrous apex (meningioma, sarcoma, trigeminal neurinoma, metastases...) and other rare causes such as traumatic intracranial aneurysm or complications following surgical correction of choanal atresia [11,20]. However, apical petrositis in the paediatric population is in general infectious in origin [20].

Trauma and neoplasm are the most frequent causes of sixth nerve paralysis in children. Raised intracranial pressure can be due to benign intracranial hypertension (pseudotumour cerebri) or associated with posterior fossa tumours. Inflammatory disease is more common in the paediatric age group in comparison with the overall population [12].

CONCLUSION

Gradenigo syndrome is a very rare but serious complication of acute otitis media and should be suspected in the presence of unilateral headache and abducens nerve palsy. It is most commonly caused by aerobic organisms but can result from infection with anaerobic organisms as in this present case.

The management varies from radical surgery to conservative therapy depending on the clinical presentation.

This patient recovered completely without sequelae after surgery and intravenous antibiotic therapy.

REFERENCES

- (1) ALBERS F.W. – Complications of otitis media: the importance of early recognition. *Am J Otol* 1999; 20:9-12.
- (2) CHOLE R.A., DONALD P.J. – Petrous apicitis. Clinical considerations. *Ann Otol Rhinol Laryngol* 1983; 92:544-551.
- (3) DAVE A.V., DIAZ-MARCHAN P.J., LEE A.G. – Clinical and magnetic resonance imaging features of Gradenigo syndrome. *Am J Ophthalmol* 1997; 124:568-570.
- (4) DE GRAAF J., CATS H., DE JAGER A.E. – Gradenigo's syndrome: a rare complication of otitis media. *Clin Neurol Neurosurg* 1988; 90:237-239.
- (5) DHOOGHE I.J., ALBERS F.W., VAN CAUWENBERGE P.B. – Intratemporal and intracranial complications of acute suppurative otitis media in children: renewed interest. *Int J Pediatr Otorhinolaryngol* 1999; 49 Suppl 1:s109-114
- (6) FIGUERAS G., GARCIA O., VALL O., MASSAGUER X., SALVADO M. – Otogenic Fusobacterium necrophorum meningitis in children. *Pediatr Infect Dis J* 1995; 14:627-628
- (7) FINKELSTEIN Y., MARCUS N., MOSSERI R., BAR-SEVER Z., GARTY B. – Streptococcus acidominimus infection in a child causing Gradenigo syndrome. *Int J Pediatr Otorhinolaryngol* 2003; 67:815-817.
- (8) GILLANDERS D.A. – Gradenigo's syndrome revisited. *J Otolaryngol* 1983; 12:169-174.
- (9) GOLDSTEIN N.A., CASSELBRANT M.L., BLUESTONE C.D., KURS-LASKY M. – Intratemporal complications of acute otitis media in infants and children. *Otolaryngol Head Neck Surg* 1998; 119:444-454.
- (10) GRADENIGO G. – Über die paralyse des N. Abduzens bei otitis. *Arch Ohrenheilk* 1907; 74:149-158.
- (11) HARDJASUDARMA M., EDWARDS R.L., GANLEY J.P., AARSTAD R.F. – Magnetic resonance imaging features of Gradenigo's syndrome. *Am J Otolaryngol* 1995; 16:247-250.
- (12) HARLEY R.D. – Paralytic strabismus in children. Etiologic incidence and management of the third, fourth, and sixth nerve palsies. *Ophthalmology* 1980; 87:24-43
- (13) JAGADEESAN P., MADESWARAN K., THIRUPATHY S.P., KALAIRAJAN D., INBASEKARAN V. – Gradenigo's syndrome: a rare complication of otitis media. *J Indian Med Assoc* 2002; 100:669-670
- (14) KUCZKOWSKI J., MIKASZEWSKI B. – Intracranial complications of acute and chronic mastoiditis: report of two cases in children. *Int J Pediatr Otorhinolaryngol* 2001; 60:227-237
- (15) MARIANOWSKI R., ROCTON S., AIT-AMER J., MORISSEAU-DURAND M., MANACH Y. – Conservative management of Gradenigo syndrome in a child. *Int J Pediatr Otorhinolaryngol* 2001; 57:79-83
- (16) MINOTTI A.M., KOUNTAKIS S.E. – Management of abducens palsy in patients with petrositis. *Ann Otol Rhinol Laryngol* 1999; 108:897-902.
- (17) PACE-BALZAN A., KEITH A.O., CURLEY J.W., RAMSDEN R.T., LEWIS H. – Otogenic Fusobacterium necrophorum meningitis. *J Laryngol Otol* 1991; 105:119-120.
- (18) TUTUNCUOGLU S., URAN N., KAVAS I., OZGUR T. – Gradenigo syndrome: a case report. *Pediatr Radiol* 1993; 23:556.
- (19) VAN WIERINGEN P.M., VAN LITH H.J., VAN DIJK R.A. – Otitis media, petrositis en het syndroom van Gradenigo. *Tijdschr Kindergeneesk* 1989; 57:63-66.
- (20) WOODY R.C., BURCHETT S.K., STEELE R.W., SULLIVAN J.A., MCCONNELL J.R. – The role of computerized tomographic scan in the management of Gradenigo's syndrome: a case report. *Pediatr Infect Dis* 1984; 3:595-597.

.....

Address for correspondence:

Piron Kathy

*Academisch Ziekenhuis, Vrije Universiteit Brussel
Laarbeeklaan, 101*

B-1090 Brussel

Kathy.Piron@az.vub.ac.be