

# ALPORT SYNDROME AND CONJUNCTIVAL TELANGIECTASIA

DECOCK C.\*, DE LAEY J.J.\*,  
LEROY B.P.\*\*,\*\*, KESTELYN P.H.\*

---

## SUMMARY

We report a patient with ocular abnormalities due to Alport syndrome.

Considerable improvement of visual acuity was obtained following ocular lens extraction with foldable lens implantation in the right eye to compensate the effect of the lenticonus anterior. The presence of conjunctival telangiectasia is a new clinical finding in a patient with Alport syndrome.

## RÉSUMÉ

Nous décrivons des anomalies oculaires chez un patient avec le syndrome d'Alport. Un lenticône antérieur était présent. Après extraction de la cataracte avec implantation d'un cristallin artificiel, une amélioration visuelle notable a été observée. Nous rapportons également la présence de télangiectasies conjonctivales, symptôme non décrit jusqu'à présent.

## KEY-WORDS

Alport syndrome, conjunctival telangiectasia, lenticonus anterior

## MOTS-CLÉS

Syndrome d'Alport, télangiectasies conjonctivales, lenticône antérieur

.....

\* From the Department of Ophthalmology and  
\*\* Centre for Medical Genetics, Ghent University  
Hospital, Ghent, Belgium.

received: 09.07.03

accepted: 25.08.03

## INTRODUCTION

Alport first described this condition in 1927 (1) in his article entitled: "Hereditary familial congenital hemorrhagic nephritis". The first description of the ocular features of this syndrome by Sohar, dates back to 1956 (6). Alport syndrome is an inherited disorder of basement membranes, due to mutations in the gene encoding type 4 collagen (2). As a consequence, the cochlea, glomerulus and several eye structures are affected by structural defects in their respective basement membranes. Until now, ocular abnormalities described in Alport syndrome included those at the level of the cornea, lens, iris and the retina (3). Here we describe a patient with Alport syndrome and conjunctival telangiectasia.

## CASE REPORT:

A 44-year old man with proven, X-linked dominant Alport syndrome was referred to our department because of a slowly progressive drop in visual acuity in his right eye. A full clinical work-up including biomicroscopy, funduscopy, corneal topography and optical coherence tomography was performed. This patient developed a high-tone sensorineural hearing loss by the age of 20 and a terminal renal failure. The latter was treated by two consecutive kidney transplantations, the first in 1985 and a second after chronic rejection of the first graft, in 1991. A bout of malignant hypertension following the second kidney transplantation probably caused a bilateral cystic macular oedema with an associated papilledema. This lasted for two and a half weeks.

## RESULTS

Visual acuity was 3/10 with -5.5 (-5.75/13°) in the right and 1/20 with -5.5 (-4/0°) in the left eye. Ocular examination revealed multiple, bilateral conjunctival telangiectasias (*fig. 1*). The lesions were equally distributed in both eyes and located only on the bulbar conjunctiva, predominantly in the perilimbal area at 3 and 9 o'clock. Slitlamp examination revealed a polymorphous corneal dystrophy, a lenticonus anterior and a corneal arcus juvenilis in both eyes. A bilateral dot-and-fleck retinopathy was obvious on funduscopy, as was a large stage 4 macular hole in the left eye (*fig. 2*). Corneal topography showed a regular corneal astigmatism of +2.84/94° (right eye) and +2.81/94° (left eye). Hence, approximately half of the total astigmatism in the right eye is lenticular in origin and related to the lenticonus anterior. Clear lens extraction in the right eye with foldable lens implantation was performed and one month after treatment visual

acuity was restored to 9/10 with +1.75 (-3.5/170°). With corneal topography, the remaining astigmatism was proven to be only corneal in origin.

## DISCUSSION

The first to report retinal telangiectasia in a patient with Alport syndrome were Kondra et al. (4) in 1983. However, to our knowledge, conjunctival telangiectasia have never been described before. Mannis et al (5) presented a differential diagnosis of conjunctival telangiectasia including (a) local conditions which dilate the conjunctival vessels and (b) concomitant telangiectasia of conjunctiva and skin. The latter includes (a) Osler-Rendu-Weber syndrome, (b) ataxia-telangiectasia, (c) angiokeratoma corporis diffusum and (d) generalised essential telangiectasia. This group can generally be excluded because of the absence of skin lesions in our patient. Local conditions dilating the conjunctival vessels are mainly due to (a) an in-

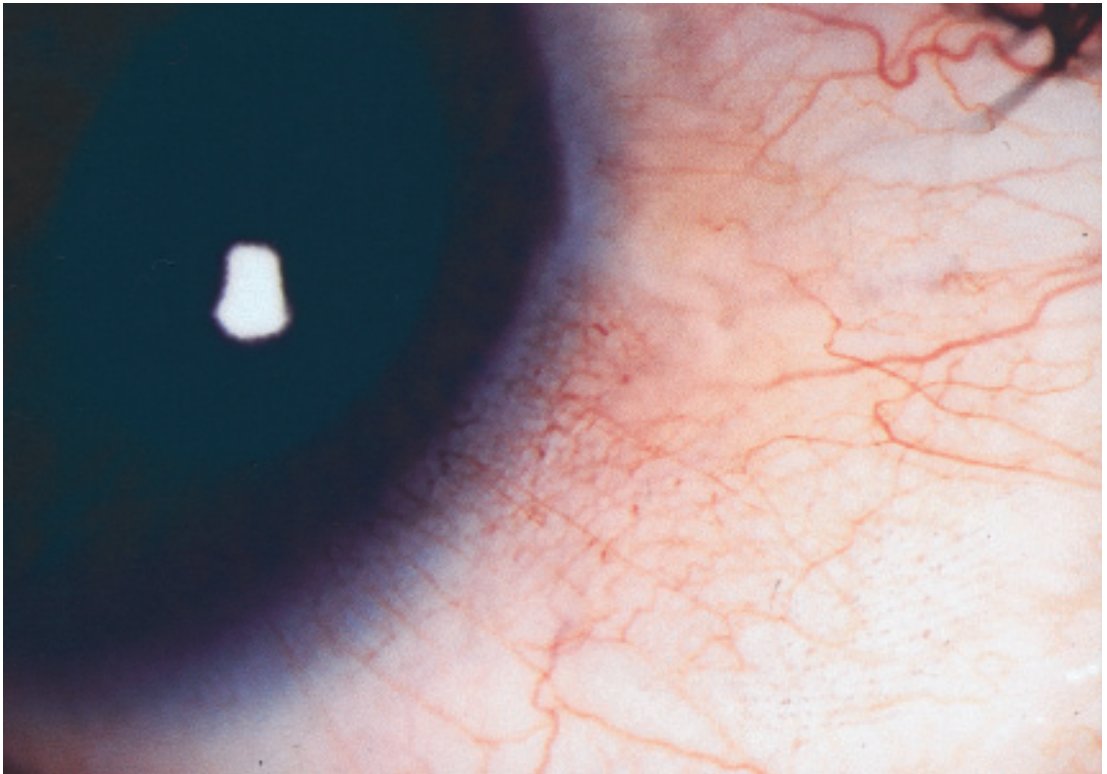


Figure 1. Multiple conjunctival telangiectatic vessels near limbus of right eye.

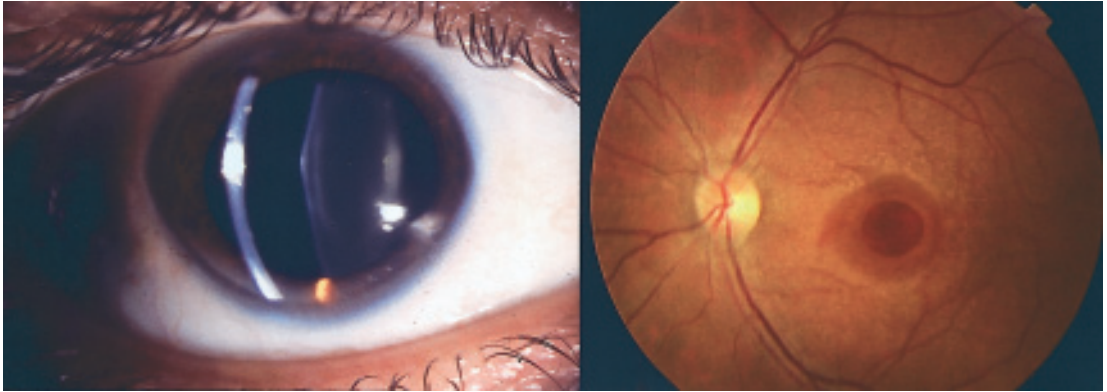


Figure 2.

(left) Lenticonus anterior in the right eye.

(right) Fundus of left eye showing typical dot-and-fleck retinopathy and a stage 4 macular hole.

creased local blood flow (including a carotid-cavernous fistula or an underlying uveal melanoma) and (b) a local inflammatory process (e.g. Graves ophthalmopathy, chronic conjunctivitis). All of these were excluded in our patient. As on the one hand conjunctival vessels have a well-defined basement membrane, and on the other hand the pathology in Alport syndrome is caused by an inherited disorder of these very basement membranes, one might consider this as a possible explanation for the existence of conjunctival telangiectasia in our patient.

To our knowledge, no correlation has been described between our patient's medical treatment namely azathioprine, cyclosporine, calciumcarbonate and natriumbicarbonate, and conjunctival telangiectasia.

## CONCLUSION

In summary, we report a patient with ocular abnormalities secondary to Alport syndrome. Considerable improvement of visual acuity has been obtained following ocular lens extraction with foldable lens implantation in the right eye to compensate the effect of the lenticonus anterior. The presence of conjunctival telangiectasia is a new clinical finding in a patient with Alport syndrome.

## REFERENCES

- (1) ALPORT A.C. – Hereditary familial congenital hemorrhagic nephritis. *Brit. Med. J.* 1927; 1, 504-506.
- (2) CLIFFORD E., KASHTAN – Alport syndrome: an inherited disorder of renal, ocular and cochlear basement membranes. *Med.* 1999; 78: 338-360.
- (3) COLVILLE D.J., SAVIGE J. – Alport syndrome: a review of the ocular manifestations. *Ophthalm. Genet.* 1997; 18: 161-173.
- (4) KONDRA L., CANGEMI F.E., PITTA C.G. – Alport's syndrome and retinal telangiectasia. *Ann. Ophthalmol.* 1983; 15: 550-551.
- (5) MANNIS M.J., BINDI C.S., HUNTLEY A.C. – Ocular manifestations of generalized essential telangiectasia. *Cornea* 1999; 18: 731-733.
- (6) SOHAR E. – Renal disease, inner ear deafness and ocular changes; a new heredofamilial syndrome. *Arch. Intern. Med.* 1956; 97: 627-630.

.....

*Address for correspondence:*  
 Decock Christian  
 Twee Dreven 76  
 9830 Sint-Martens-Latem  
 +32-9-3210060  
 christian\_decocock@hotmail.com