
HETEROCHROMIA OF THE IRIDES AND A MOTILITY DISORDER OF THE OESOPHAGUS: A COINCIDENCE OR A DEFECT DURING EMBRYOGENESIS?

GOETHALS S.* , HOFFMAN I.** ,
DEVRIENDT K.*** , CASTEELS I.*

SUMMARY

We present an infant with heterochromia of the irides and a motility disorder of the oesophagus. The association between Hirschsprung's disease and heterochromia of the irides has been reported in the past and has been explained by the common origin during embryogenesis of the parasympathetic ganglion cells and the stroma of the iris.

SAMENVATTING

Wij beschrijven een kind met een bilaterale heterochromie van de iris en een motiliteitsafwijking van de slokdarm. In het verleden is al een associatie aangetoond tussen de ziekte van Hirschsprung en heterochromie van de iris. De associatie is het gevolg van de gemeenschappelijke oorsprong tijdens de embryogenese van de parasympathische ganglioncellen en het stroma van de iris.

RÉSUMÉ

Nous présentons un enfant avec une hétérochromie bilatérale de l'iris et une dysfonction de la motilité

de l'oesophage. L'association entre la maladie de Hirschsprung et une hétérochromie de l'iris a déjà été rapportée. L'association est attribuée à l'origine commune durant l'embryogenèse des cellules ganglionnaires parasympathiques et du stroma de l'iris.

KEY-WORDS

Heterochromia of the iris, oesophagus, Hirschsprung's disease

MOTS-CLÉS

Hétérochromie de l'iris, oesophage, maladie de Hirschsprung

.....

* Dept. of Ophthalmology, University Hospital St. Raphaël, Kapucijnenvoer 33, B-3000 Leuven, Belgium.

** Dept. of Pediatrics, University Hospital Gasthuisberg, Herestraat 49, B-3000 Leuven, Belgium.

*** Dept. of Human Genetics, University Hospital Gasthuisberg, Herestraat 49, B-3000 Leuven, Belgium.

received: 02.06.03

accepted: 06.08.03

INTRODUCTION

We present a female infant with sector heterochromia of the irides due to a stromal hypoplasia and a motility disorder of the oesophagus. The association between Hirschsprung's disease, which is a congenital condition consisting of the absence of parasympathetic ganglion cells in the affected distal bowel, and heterochromia of the irides has been previously described (4,5,8,9). To our knowledge there is no previous report on the association between a motility disorder of the oesophagus and sector heterochromia of the irides.

CASE

We present a 2 years old girl who was referred to us by the pediatrician because of heterochromia of the irides.

This patient was born at term to healthy non-consanguineous parents. Pregnancy and delivery were uncomplicated. Birth weight was 3,670 kg. At the age of five weeks she had a polysomnography which showed desaturations to 73% when feeding her bottle. On observation she drank very gluttonously and choked a lot. Secondary to the feeding problems with milk aspiration, she developed persisting respiratory problems.

Manometric study of the oesophagus demonstrated a normal basic tonus of the superior and inferior oesophageal sphincter. The inferior oesophageal sphincter relaxed normally after deglutition. Peristaltic contractions of the corpus of the oesophagus were rarely seen after deglutition. Most of the time there were simultaneous contractions of the whole oesophagus. The superior oesophageal sphincter relaxed only partially by after deglutition. Between meals the inferior oesophageal sphincter showed transient relaxation.

Oesophageal pH monitoring showed pathological reflux and oesophagoscopy revealed an oesophagitis grade 1. Medication alone didn't relieve the symptoms and duodenal enteral feeding was necessary.

On ophthalmological examination there was normal visual contact and normal eye motility. There was no strabismus. The pupils had an irregular appearance, more evident on the left eye. Pupillary reflexes were normal. Pigmenta-

tion of the periorbital structures such as skin, eyebrows and eyelashes were normal. Conjunctivae, corneas and anterior chambers showed no abnormalities. Both irides had a light-blue color with in the right eye a sector of stromal hypoplasia of the iris at 2 o'clock (figure 1). In the left eye there was a sector of more obvious stromal hypoplasia of the iris at 10 o'clock (figure 2). Intra-ocular pressure measured with Perkins applanation tonometry was 10 mmHg in both eyes. After dilation with cyclopentolate 0,5% funduscopy didn't reveal any abnormalities of the discs, maculae and posterior poles. Streak retinoscopy showed emmetropia.

COMMENT

Embryological studies show that the neural crest cells play an important role in the development of several tissues (1,5,9). They arise from ectoderm at the neural plate margin and form the neural crests on the summit of neural folds. The neural crest cells exit from the neural crest to migrate to other regions of the embryo where they differentiate into a variety of cells and tissues, such as spinal ganglia, parasympathetic ganglia, pigment cells, endocrine cells, muscle cells, skeletal cells and connective cells.

The neural crest cells play an important role in the development of the anterior segment of the human eye (1,2). During the embryonic development of the eye neural crest cells enter the primary mesenchyme to form the secondary mesenchyme (1). Out of the secondary mesenchyme, which exists out of undifferentiated cells, three distinct waves of cells invade the anterior segment and the cells differentiate into corneal endothelium, corneal stroma and keratocytes, and into the anterior iris stroma and melanocytes. Furthermore neural crest cells contribute in the development of the anterior chamber angle structures and pigment cells of the choroid and sclera (2). The pigment epithelium of the iris differentiates from neural ectoderm.

In a different pathway of the embryogenesis submucosal and myenteric ganglion cells also originate from neural crest cells (2,9). Cells originating from the neural crest cells of the thoracic region migrate on each side of the spinal cord. They form a bilateral chain of segmen-

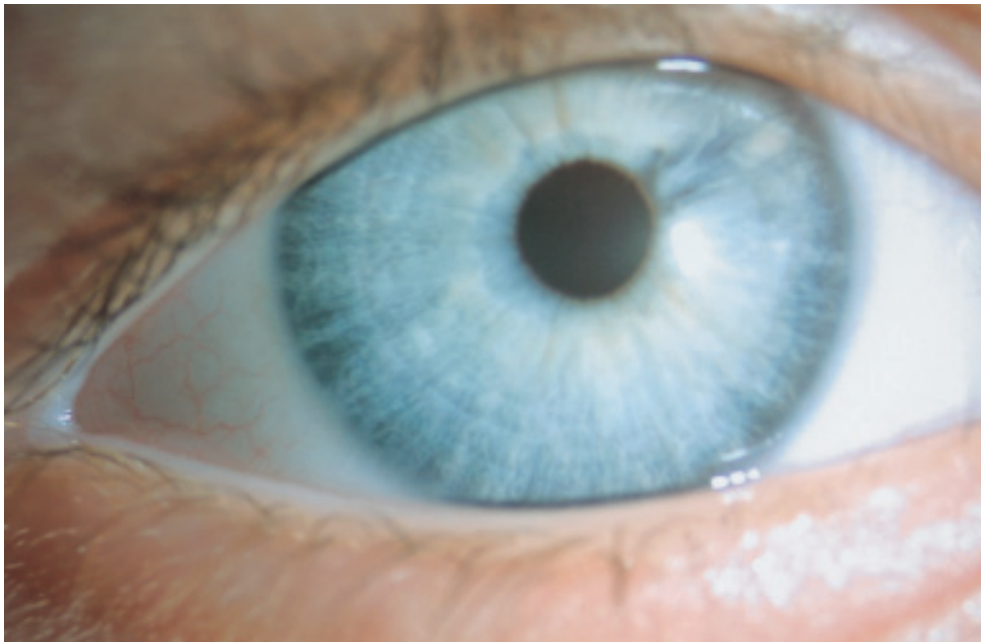


Fig 1. Right eye showing sectorial stromal hypoplasia of the iris.

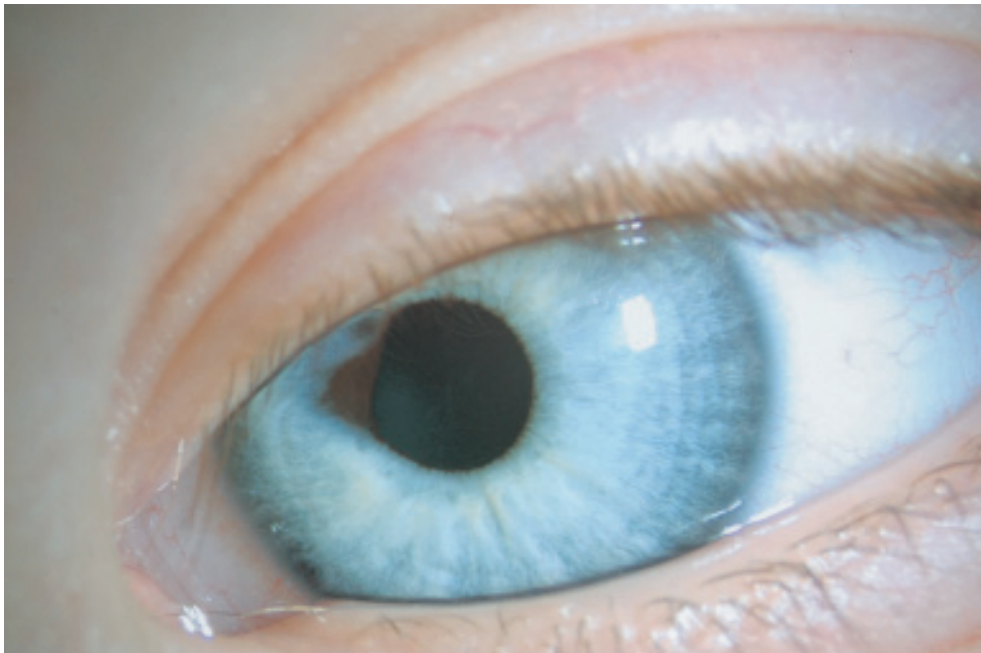


Fig 2. Left eye showing sectorial stromal hypoplasia of the iris.

tally arranged sympathetic ganglia. Some sympathetic neuroblasts migrate in front of the aorta to form the submucosal and myenteric ganglia.

There are three factors relating to iridial structure that may influence its color: 1) melanin pigment of the iris pigment epithelium, 2) quantity and granule size of pigment in the stromal melanocytes, 3) cellular density of the iris stroma (3). The amount and distribution of melanin in the iris pigment epithelium is similar in irides of different color. When there is an important stromal hypoplasia of the iris, the color of the iris appears brown due to the melanin of the iris pigment epithelium. The iris pigment epithelium is derived from the neuroectoderm, so it has a different embryological origin than iris stroma which is derived from the neural crest. One may think that in our case the changes of the irides resemble an ectropion uveae. Careful examination with the slit lamp however showed a stromal hypoplasia of the iris which is not present with congenital ectropion uveae. In this case the sectorial heterochromia is due to a direct view of the iris pigment epithelium at the posterior surface of the iris and not due to an extension of the iris pigment on the anterior surface of the iris.

As already mentioned, in our case there was gastro-oesophageal reflux causing oesophagitis grade 1. There was also an important dysfunction of the superior oesophageal sphincter. One may think that these two entities are related. However a previous study showed that the function of the superior oesophageal sphincter in children with gastro-oesophageal reflux does not differ from normal infants (10). In the literature there is a report of two infants with similar gastro-oesophageal symptoms as our patient (11). One of these infants died of pneumonia after food-aspiration. Postmortem histology showed the presence of nerve fibers and ganglion cells in the lower two-third of the oesophagus. In the upper one third of the oesophagus however there were nerve fibers but no ganglion cells. These findings were similar to the agangliosis seen in Hirschsprung's disease (11).

In the past several case reports have been published showing the relationship between Hirschsprung's disease and bilateral iris sector heterochromia (4,7,8,11). There is also a known

association between Waardenburg's syndrome and iris sector heterochromia. Patients with Waardenburg's syndrome have also other ocular features: telecanthus, lateral displacement of lower lacrimal punctum, blepharophimosis, hyperplasia of the eyebrows medially and pigmentary changes in fundo (5). Our patient had neither of these features. The link between Hirschsprung's disease and iris heterochromia is attributed to their common origin from the neural crest cells.

In our case there is a dysfunction of the oesophagus, another part of the gastro-intestinal tract. This dysfunction of the oesophagus may be caused by an agangliosis similar to a previous presented case (11). A congenital impaired differentiation of the neural crest cells could give abnormal or absent submucosal and myenteric ganglion cells of the oesophagus.

The presence of heterochromia of the irides as seen in Hirschsprung's disease is an argument for a neurocristopathy. The association between a dysfunction of the oesophagus and heterochromia of the irides due to stromal hypoplasia in our case may therefore represent a neurocristopathy.

REFERENCES

- (1) BAHN C.F., FALLS H.F., VARLEY G.A., MEYER R.F., EDELHAUSER H.F., BOURNE W.M. – Classification of corneal endothelial disorders based on neural crest origin. *Ophthalmology* 1984;91:558-63
- (2) BEAUCHAMP G.R., KNEPPER P.A. – Role of the neural crest in anterior segment development and disease. *J Pediatr Ophthalmol Strabismus*. 1984;21:209-14
- (3) BOLANDE R.P. – The neurocristopathies. *Hum Pathol*. 1975;5:409-29
- (4) BRAZEL S.M., SULLIVAN T.J., THORNER P.S., CLARKE M.P., HUNTER W.S., MORIN J.D. – Iris sector heterochromia as a marker for neural crest disease. *Arch Ophthalmol* 1992;110:233-6
- (5) GOLDBERG M.D. – Waardenburg's syndrome with fundus and other anomalies. *Arch Ophthalmol* 1966;76:797-810
- (6) IMESCH P.D., WALLOW I.H.L., ALBERT D.M. – The color of the human eye: a review of morphologic correlates and of some conditions that affect iridial pigmentation. *Surv Ophthalmol* 1997; 41, supplement 2: S117-S123

- (7) LAI J.S., LAM D.S. – Bilateral iris sector heterochromia with or without Hirschsprung's disease. *Eye* 1998;12:1024-7
- (8) LIANG J.C., JUAREZ C.P., GOLDBERG M.F. – Bilateral bicoloured irides with Hirschsprung's disease. *Arch Ophthalmol* 1983;101:69-73
- (9) MEIJERS J.H.C., TIBBOEL D., VAN DER KAMP A.W.M., VAN HAPERON-HEUTS C.C.M., MOLENAAR J.C. – Cell division in migratory and aggregated neural crest cells in the developing gut. *J Pediatric Surg* 1987;22:243-5
- (10) SONDHEIMER J.M. – Upper esophageal sphincter and pharyngoesophageal motor function in infants with and without gastroesophageal reflux. *Gastroenterology* 1983;85: 301-5
- (11) UTIAN H.L., THOMAS R.G. – Cricopharyngeal incoordination in infancy. *Pediatrics* 1969;43:402-6
-
- Request for reprints:*
Dr. S. Goethals
Dept. of Ophthalmology
University Hospital St. Raphaël
Kapucijnenvoer 33
B-3000 Leuven, Belgium