

---

# THE ADVERSE EFFECTS OF CORTICOSTEROIDS IN CENTRAL SEROUS CHORIORETINOPATHY

*DE NIJS E. \*, BRABANT P. \*, DE LAEY J.J. \**

---

## SUMMARY

The purpose of this paper is to report on the possible deleterious effect of corticosteroids in central serous chorioretinopathy (CSCR). We will describe three patients in whom CSCR was induced or aggravated by corticosteroids. Despite multiple reports describing the onset of CSCR or aggravation of existing lesions with corticosteroids, they are still used by some ophthalmologists for the treatment of CSCR. Corticosteroids are also widely used for the treatment of a variety of diseases. Ophthalmologists should be aware that corticosteroids independently of the way of administration may cause this type of complication.

## RÉSUMÉ

Le but de notre rapport est de souligner l'effet néfaste des stéroïdes sur la choriorétinite séreuse centrale (CRSC). Nous décrivons trois patients chez qui la CRSC est provoquée ou aggravée par les corticoïdes.

Malgré les nombreuses publications, certains ophtalmologues ignorent les effets défavorables des corticoïdes dans toutes ses formes sur la CRSC. Certains les utilisent même dans le traitement de ces lésions. Les corticostéroïdes sont fréquemment prescrits pour un vaste nombre d'affections. Les ophtalmologues doivent être au courant de leurs complications maculaires éventuelles.

## SAMENVATTING

Dit artikel handelt over de schadelijke gevolgen van corticosteroïden op chorioretinitis serosa centralis

.....

\* *Department of Ophthalmology, Ghent University Hospital, Belgium*

received: 10.04.03

accepted: 18.06.03

(CRSC). Drie patiënten worden voorgesteld waarbij CRSC geïnduceerd of verergerd werd na corticotherapie. Ondanks veelvuldige publicaties die deze bijwerking van corticoïden aantoonde bij patiënten met CRSC, gebruiken sommige oogartsen nog steeds steroïden bij CRSC. Steroïden zijn vaak nodig bij de behandeling van uiteenlopende aandoeningen. Oogartsen moeten op de hoogte zijn van deze schadelijke effecten van corticoïden in al hun toedieningsvormen.

## KEY-WORDS

Central serous chorioretinopathy - side effect - corticosteroid

## MOTS-CLÉS

Choriorétinite séreuse centrale - complication - corticoïdes

## INTRODUCTION

Ocular side effects due to systemic or ocular administration of corticosteroids are well known e.g. corticosteroid induced glaucoma, posterior subcapsular cataract (6). This paper highlights another -less known- complication of corticosteroid treatment: central serous chorioretinopathy. This retinal disorder can occur during treatment with corticosteroids administered under various forms or may worsen in case it is treated with corticosteroids.

Central serous chorioretinopathy is characterized by the formation of a localized neurosensory retinal detachment caused by leakage of fluid at the level of the retinal pigment epithelium. It typically affects young and middle-aged men, who present with symptoms of diminished visual acuity, relative central scotoma, me-

tamorphopsia and micropsia. This report describes 3 patients: two patients suffering from CSCR received steroids: under systemic form in the first patient and by means of retrobulbar injections in the second patient. The third patient developed ocular problems during systemic treatment with intravenous and peroral corticosteroids for bronchiolitis obliterans with organizing pneumonia (BOOP).

## CASE REPORTS

### CASE 1

A 41-year-old male complained of blurred vision in the right eye in December 2001. A diagnosis of central serous chorioretinopathy was made. One week later, the left eye was affected. A therapy with systemic corticosteroids (me-

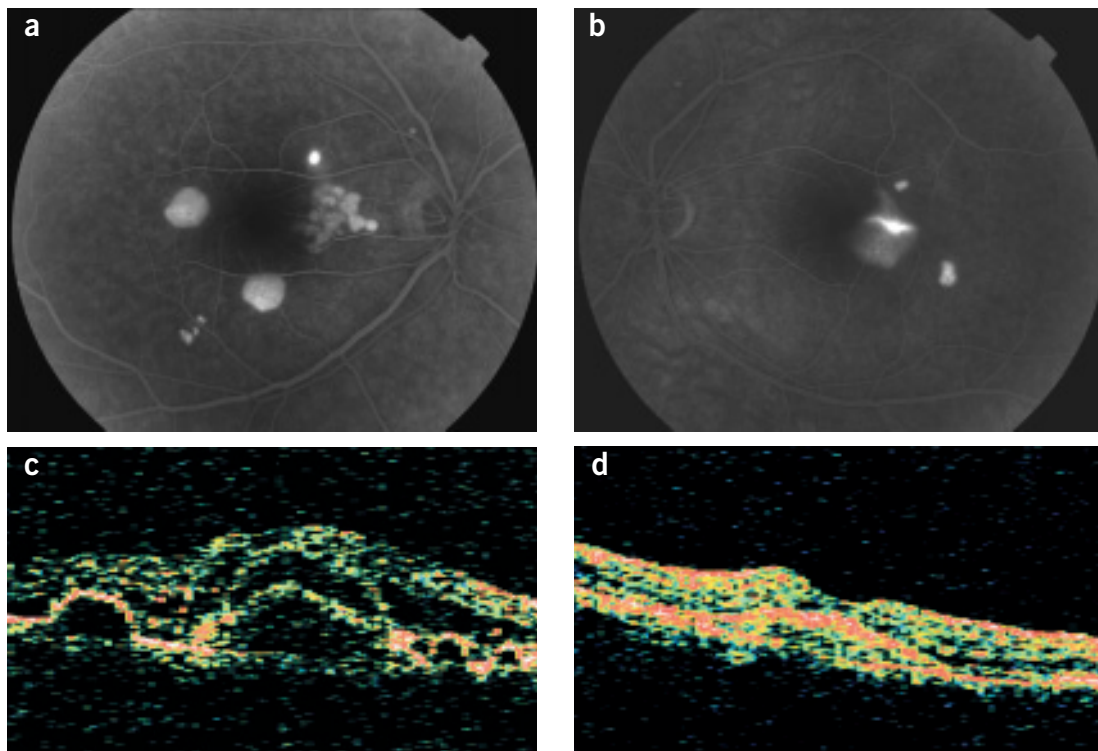
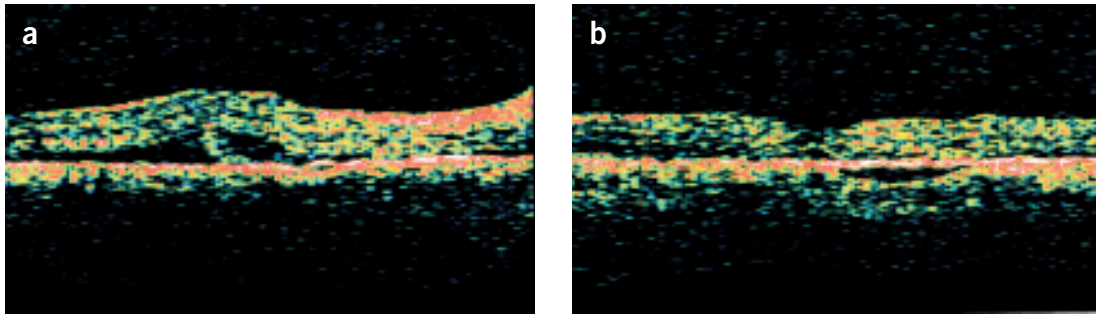
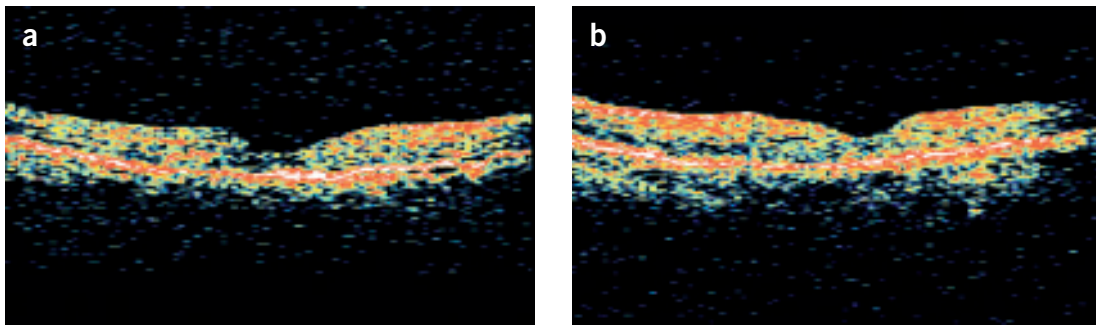


Fig 1. Case 1: March 2002:

- (a): FA of the right eye: pinpoint leakage point, cluster of focal lesions, PED
- (b): FA of the left eye: smoke stack sign, PED
- (c): OCT of the right eye: multiple PED and neurosensory detachments and diffuse macular edema
- (d): OCT of the left eye: foveolar serous detachment



*Fig 2. Case 1: April 2002:*  
 – (a): OCT of the right eye: significant decrease of PED and neurosensory detachments after withdrawal of steroids  
 – (b): OCT of the left eye: restored foveal depression, small PED

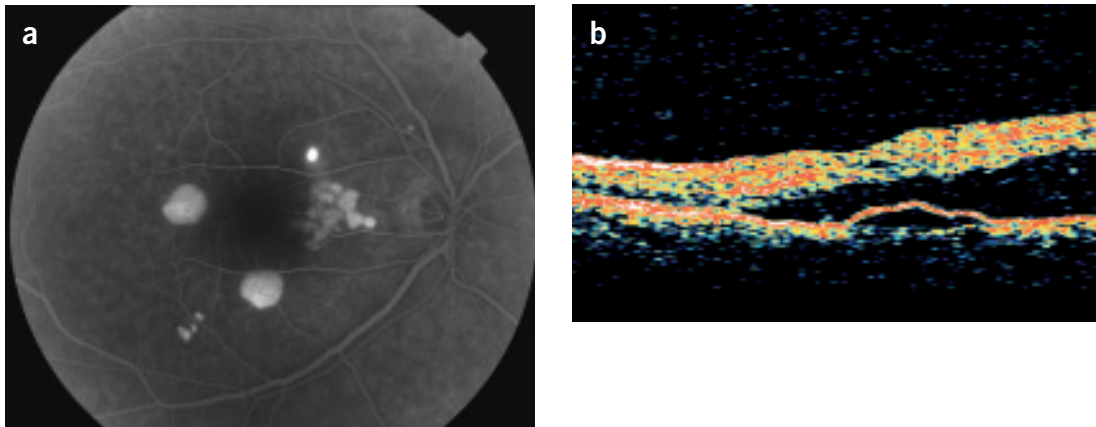


*Fig 3. Case 1: August 2002:*  
 – (a): OCT of the right eye: foveal depression with only a small amount of fluid beneath the sensory retina  
 – (b): OCT of the left eye: normal aspect

thylprednisolone 64 mg) was given. No improvement of complaints or visual acuity occurred. The patient was then referred to our department for second opinion in March 2002. According to the patient, vision had further decreased. He also complained of micropsia and disturbed colour perception. His best corrected visual acuity was 7/10 in the right eye and 8/10 in the left eye. Fluorescein angiography (FA) showed a pinpoint focus with late leakage of dye, a cluster of focal lesions and pigment epithelial detachments (PED) in the right eye (fig 1a) and a serous detachment with typical smoke-stack sign and a small PED in the left eye (fig 1b). Optical coherence tomography (OCT) showed multiple PED's, serous detachments and a diffuse macular oedema in the right eye (fig 1c) and a serous detachment at the fovea in the left eye (fig 1d). As on fluorescein angiography as well as OCT polypoidal choroidal vasculopathy could be considered in

the differential diagnosis, an intracyaninegreen (ICG) angiography was performed. With this examination no polypoidal vascular lesion was seen. However transient choroidal hyperfluorescence with a washing out phenomenon was noticed, highly suggestive for central serous choroidopathy. The corticosteroids were tapered. Six weeks later, the patients symptoms worsened. The best corrected visual acuity was now 8/10 in both eyes. On OCT a significant decrease in size of the neurosensory detachments could be seen in the right eye (fig 2a) and the foveal depression was restored in the left eye (fig 2b). Because FA showed a persistent leakage spot in the right eye, focal laser treatment was applied.

Another six weeks later, the patient reported improvement of symptoms in both eyes. His best corrected visual acuity was 9/10 in the right eye and 10/10 in the left eye. On FA no dye leakage was seen in the right eye. In the left eye



*Fig 4.* Case 1: September 2002: reactivation of the lesions due to steroids:  
 – (a): FA of the left eye: leaking point with filling of a large bulla  
 – (b): OCT of the same eye: large serous detachment with small PED

there was still a small PED, but no further lesions were seen. No treatment was given.

Three months later (7 months after the initial symptoms) the patient mentioned improved visual acuity but still some metamorphopsia and difficulties in colour perception. His best corrected visual acuity was 10/10 in the right eye and 12/10 in the left eye. He read Parinaud 1 with both eyes. The Amsler test showed discrete metamorphopsia and two small scotomas in the right eye, and was normal in the left eye. On colour vision testing, he had an acquired blue-yellow defect, more pronounced in the right than in the left eye. Automated perimetry showed some relative defects, possibly related to poor concentration. OCT of the right eye showed now a foveal depression with only residual fluid beneath the sensory retina (fig 3a). OCT of the left eye was normal (fig 3b). FA showed a hyperfluorescent area with surrounding lipid exudates in the right eye and a small PED in the left eye. As there were no active lesions any more, the patient was asked to return for follow up after six months.

Unfortunately, the patient came back four weeks later with new complaints. Because of chronic sinusitis, the oto-rhino-laryngologist started methylprednisolone 64 mg orally as well as a nasal corticosteroidspray. Four days later our patient noticed a decrease in visual acuity and a scotoma in the left eye. The best corrected visual acuity was 10/10 in both eyes with a

marked scotoma in the left eye on Amsler testing. On FA of the right eye no leaking points could be seen, but in the left eye a leaking point with subsequent filling of a large bulla was noticed (fig 4a). OCT of the right eye showed no changes, whereas a large serous detachment was seen in the left eye (fig 4b). As the systemic treatment had already been stopped, we asked the patient to withdraw his nasal spray as soon as possible. Six weeks later he had less visual problems and on OCT the serous detachment was no longer visible.

## CASE 2

In March 1997, a 58-year-old male was referred to our department. Since more than 10 years he had recurrent episodes of blurred vision in both eyes due to chronic central serous chorioretinopathy. He had received multiple retrobulbar injections with corticosteroids in both eyes and laser photocoagulation in the left eye. He noticed a recent decrease in visual acuity in the left eye. His best corrected visual acuity in the right eye was 10/10 and 2/10 in the left eye. FA of the right eye showed an important diffuse retinal pigment epithelial atrophy without obvious leaking points. In the left eye extensive retinal pigment epithelial atrophy was associated with an area of diffusion surrounded by hemorrhages and lipid exudates, strongly suggestive for a subretinal neovascular mem-

brane. Direct photocoagulation of this lesion was subsequently performed. Two weeks later his visual acuity remained unchanged in the right eye and improved to 4/10 in the left eye. FA of the left eye showed less exudates and hemorrhages. A control one month later showed no changes in visual acuity or FA. The patient did not come back until five years later in February 2002 for a routine examination. His best corrected visual acuity was 8/10 in the right eye and counting fingers in the left eye. On FA large areas of pigment epithelial atrophy without diffusion were seen in both eyes and a fibrotic scar without leakage in the left eye. OCT of the right eye showed an irregular RPE with slight edema and a fibrotic scar in the left eye. This remained unchanged 6 months later.

### CASE 3

A 56-year-old female had an episode of bronchiolitis obliterans with organizing pneumonia (BOOP) in June 2002. A treatment with systemic corticosteroids was started, intravenously at first, followed by oral methylprednisolone. Four weeks later the patient complained of blurred vision and metamorphopsia in the right eye. Her best corrected visual acuity was 5/10 in her right eye and 10/10 in the left eye. FA showed a perifoveolar leakage point in the right eye and some hyperfluorescent spots due to pigment epithelial alterations in the left eye. ICG angiography confirmed the diagnosis of central serous chorioretinopathy. On OCT a serous retinal detachment was seen in the right eye, the macular profile in the left eye was normal. As the steroids were already tapered, no local treatment was advised. Six weeks later, the visual acuity in the right eye improved to 9/10. On FA the neurosensory detachment was less extensive.

### DISCUSSION

The physiopathogenesis of CSCR remains unclear.

A number of predisposing factors have been reported: type A personality, emotional strain, hypertension, pregnancy, organ transplantation, systemic lupus erythematosus, increased levels of endogenous cortisol, psychopharmaco-

logical medication or treatment with corticosteroids (1,3,4,7-16,18,19,21,22,25).

Previous reports describe the onset of CSCR or aggravation of pre-existing lesions by corticosteroids regardless of their route of administration: not only systemic administration (intravenously, intramuscular, peroral) but also intra-joint and epidural injection, intranasal spray, inhaled corticosteroids, topical skin application and retrobulbar injections (1,3,4,8,10,13-15,21,22).

The daily dose is of greater influence in the onset than the total dosage and frequently symptoms can arise by increasing the daily dose (1,18,24). The latency time is shorter with higher doses and recurrences occur earlier when the dosage of corticosteroids is higher (3,5,24). Recurrences can also occur in patients who had previous episodes of CSCR independent of corticosteroid use (3,10).

The patients are often older than the patients with the idiopathic type of CSCR (19,24).

The lesions in corticosteroid-related CSCR are frequently bilateral (3,19).

The lesions are typically localized serous detachments of neuroretina and/or the RPE. However, atypical forms such as chronic CSCR are more likely associated with the use of steroids (3,12,18,22).

Subretinal neovascularization is also here a possible complication (20), as seen in our second patient. In this patient, the choroidal neovascularization can be a complication of CSCR, the previously performed laser treatment or both. A decrease or discontinuation of the steroids may improve visual symptoms (1,4,5,13,18,21,23). Laser photocoagulation can be performed either for a persistent leakage spot or for subretinal neovascularization (3,8,13,20,21). Acetazolamide treatment for CSCR shortens the time for subjective and objective improvement, but has no effect on visual outcome or recurrence rate (17). In vitro studies with bovine RPE cells showed a beneficial effect of brimonidine at the level of the rupture in the RPE: an alpha-1-receptor on the apical side of RPE cells is stimulated by the aspecific alpha-agonist effect with subsequent resorption of subretinal fluid (2). This has not been confirmed clinically yet.

Physicians should be prudent in using steroids and a periodic ophthalmologic examination is

recommended (21). CSCR patients should avoid the use of corticosteroids in any form, unless they cannot be treated with alternative medications (1,3,4,8,10,15,22,23).

## CONCLUSION

Despite several reports indicating the adverse effects of corticosteroids on the severity and course of CSCR, corticosteroids are still used as a treatment for CSCR.

With these case reports we want to demonstrate the causal relationship between steroids and CSCR.

## REFERENCES

- (1) ABU EL-ASRAR A.M. – Central serous chorioretinopathy complicating systemic corticosteroid therapy, *Eur J Ophthalmol* 1997; 7: 297-300
- (2) ARNDT CF. – Rôle des récepteurs aux corticoïdes et gabaergiques dans le transport des molécules organiques à travers l'épithélium pigmentaire de la rétine, Doctoral thesis, July 2, 2001
- (3) BOUZAS E.A., KARADIMAS P., POURNARAS C.J. – Central serous chorioretinopathy and glucocorticoids, *Surv Ophthalmol* 2002; 47: 431-448
- (4) CARVALHO-RECCHIA C.A., YANNUZZI L.A., NEGRAO S., SPAIDE R.F., FREUND K.B., RODRIGUEZ-COLEMAN H., LENHARO M., IIDA T. – Corticosteroids and central serous chorioretinopathy, *Ophthalmology* 2002; 109: 1834-1837
- (5) CHAINE G., HAOUAT M., MENARD-MOLCARD C., FAVARD C., VIGNAL-CLERMONT C., CAMPINCHI-TARDY F., MASSIN P., GAUDRIC A., BADELON I., NICOLON L., SABATIER P., GUILLEVIN L. – Chorioretinite séreuse centrale et corticothérapie systémique, *J Fr Ophtalmol* 2001;24:139-146
- (6) FRANCOIS J. – Effets secondaires et complications ophtalmologiques de la cortisonothérapie, *Bull. Soc. belge Ophtalmol.* 1979; 186: 47-55
- (7) GARG S.P., DADA T., TALWAR D., BISWAS N.R. – Endogenous cortisol profile in patients with central serous chorioretinopathy, *Br J Ophthalmol* 1997; 81: 962-964
- (8) GASS J.D.M., LITTLE H. – Bilateral bullous exudative retinal detachment complicating idiopathic central serous chorioretinopathy during systemic corticosteroid therapy, *Ophthalmology* 1995; 102: 737-747
- (9) GASS J.D.M. – Central serous chorioretinopathy and white subretinal exudation during pregnancy, *Arch Ophthalmol* 1991; 109: 677-681
- (10) HAIMOVICI R., GRAGODAS E.S., DUKER J.S., SJAARDA R.N., ELIOTT D. – Central serous chorioretinopathy associated with inhaled or intranasal corticosteroids, *Ophthalmology* 1997; 104: 1653-1660
- (11) HARADA T., HARADA K. – Six cases of central serous chorioidopathy induced by systemic corticosteroid therapy, *Doc Ophthalmol* 1985; 37-44
- (12) IIDA T., SPAIDE R.F., NEGRAO S.G., CARVALHO C.A., YANNUZZI LA. – Central serous chorioretinopathy after epidural corticosteroid injection, *Am J Ophthalmol* 2001; 132: 423-425
- (13) JAMPOL L.M., WEINREB R., YANNUZZI L. – Involvement of corticosteroids and catecholamines in the pathogenesis of central serous chorioretinopathy: a rationale for new treatment strategies, *Ophthalmology* 2002; 109: 1765-1766
- (14) KAO L.Y. – Bilateral serous retinal detachment resembling central serous chorioretinopathy following epidural steroid injection, *Retina* 1998; 18: 479-481
- (15) LIN J.M., TSAI Y.Y. – Retinal pigment epithelial detachment in the fellow eye of a patient with unilateral central serous chorioretinopathy treated with steroid, *Retina* 2001; 21: 377-379
- (16) MARMOR M.F. – On the cause of serous detachments and acute central serous chorioretinopathy, *Br J Ophthalmol* 1997; 81: 812-813
- (17) PIKKEL J., BEIRAN I., OPHIR A., MILLER B. – Acetazolamide for central serous retinopathy, *Ophthalmology* 2002; 109: 1723-1725
- (18) POLAK B.C., BAARSMA G.S., SNYERS B. – Diffuse retinal pigment epitheliopathy complicating systemic corticosteroid treatment, *Br J Ophthalmol* 1995; 79: 922-925
- (19) QUILLEN D.A., GASS D.M., BROD R.D., GARDNER T.W., BLANKENSHIP G.W., GOTTLIEB J.L. – Central serous chorioretinopathy in women, *Ophthalmology* 1996; 103: 72-79
- (20) SPAIDE R.F., CAMPEAS L., HAAS A., YANNUZZI L.A., FISHER Y.L., GUYER D.R., SLAKTER J.S., SORENSON J.A., ORLOCK D.A. – Central serous chorioretinopathy in younger and older adults, *Ophthalmology* 1996; 103: 2070-2080
- (21) SPRAUL C.W., LANG G.E., LANG G.K. – Retinal pigment epithelial changes associated with

- systemic corticosteroid treatment: report of cases and review of the literature, *Ophthalmologica* 1998; 212: 142-148
- (22) TITTL M.K., SPAIDE R.F., WONG D., PILOTTO E., YANNUZZI L.A., FISHER Y.L., FREUND B., GUYER D.R., SLAKTER J.S., SORENSON J.A. – Systemic findings associated with central serous chorioretinopathy, *Am J Ophthalmol* 1999; 128: 63-68
- (23) WAKAKURA M., ISHIKAWA S. – Central serous chorioretinopathy complicating systemic corticosteroid treatment, *Br J Ophthalmol* 1984; 68: 329-331
- (24) WAKAKURA M., SONG E., ISHIKAWA S. – Corticosteroid-induced central serous chorioretinopathy, *Jpn J Ophthalmol* 1997; 41:180-185
- (25) YANNUZZI L.A. – Type-A behavior and central serous chorioretinopathy, *Retina* 1987; 7: 111-130.
- .....
- This study was supported by a grant of: Les Amis des Aveugles, Ghlin*
- Request for reprints to:  
Prof. J.J. De Laey,  
Department of Ophthalmology,  
Ghent University Hospital,  
De Pintelaan 185,  
B- 9000 Ghent,  
Belgium*