

---

# CAT SCRATCH DISEASE (CSD) IN PATIENTS WITH STELLATE NEURORETINITIS: 3 CASES.

DE SCHRYVER I.\* STEVENS A.M.\*,  
VERECKE G.\* KESTELYN PH.\*

---

## SUMMARY

This case series describes three patients with a similar clinical picture: unilateral abrupt visual loss, optic nerve edema, and a macular star exudate. In all cases we found significant antibody titers to *Bartonella henselae*, the causative agent of cat scratch disease. Cat scratch disease seems to be the most common cause of stellate neuroretinitis, formerly known as Leber's idiopathic stellate retinopathy. A review of the pertinent literature shows that serologic evidence of *B. henselae* is sufficient to confirm the diagnosis given the low incidence of significant titers in the general population. Cat scratch disease is usually a self limiting disorder in immunocompetent patients, but treatment with doxycycline is recommended.

## RÉSUMÉ

Nous décrivons une série de trois patients qui présentent un tableau clinique similaire: une perte brutale de l'acuité visuelle dans un oeil, un oedème papillaire et des exsudats en étoile autour de la macula. Chez ces trois patients la sérologie met en évidence un taux élevé d'anticorps contre *Bartonella henselae*, l'agent étiologique de la maladie des griffes du chat. La maladie des griffes du chat semble être la cause la plus fréquente de la neurorétinite stellaire, connue sous le nom de rétinite stellaire pseudonéphritique de Leber dans l'ancienne littérature. Une revue de la littérature apprend que la séropositivité pour *B. henselae* suffit en général pour affirmer le diagnostic, étant donné la faible séropré-

valence dans la population générale. La maladie des griffes du chat connaît une évolution bénigne chez les patients immunocompétents. Néanmoins, une cure d'antibiotiques sous forme de doxycycline est conseillée.

## KEY- WORDS

Cat scratch disease- neuroretinitis- *B. henselae*- Leber's stellate retinopathy- macular star

## MOTS-CLÉS

Maladie des griffes du chat- neurorétinite- *B. henselae*- rétinite stellaire pseudonéphritique de Leber- exsudat maculaire en étoile

.....

\* Department of Ophthalmology, University Hospital  
Ghent, Belgium

received: 25.07.02  
accepted: 28.09.02

## INTRODUCTION

Cat scratch disease (CSD) is a subacute, self-limiting infection caused by the gram-negative bacillus *Bartonella henselae* (figure 1). Most patients develop a mild to moderately severe flu-like illness associated with regional lymphadenopathy. Ocular involvement occurs in only 5% to 10% of patients with CSD and includes Parinaud's oculoglandular syndrome, neuroretinitis, and focal retinochoroiditis. A review of the literature indicates a prevalence of neuroretinitis in documented CSD between 1 and 2% (6,20), although one series reported a prevalence as high as 26% (24). Encephalitis, osteomyelitis, and hepatosplenic disease are rare complications of CSD.

We report 3 cases of neuroretinitis with a positive serology for *B. henselae*.

## PATIENTS AND RESULTS

### CASE 1

A 50-year old caucasian woman presented with sudden visual loss in the left eye. She reported a febrile illness with mild headaches and myalgia, 2 weeks prior to the visual loss. She owned a hostel for lost animals.

Physical examination revealed an erythematous papule at the left hand and a tender lymph node in the left elbow.

Best corrected visual acuity was 20/20 in the right eye and 20/70 in the left eye. Biomicroscopy was unremarkable in both eyes. She had a left relative afferent pupillary defect. Fundus

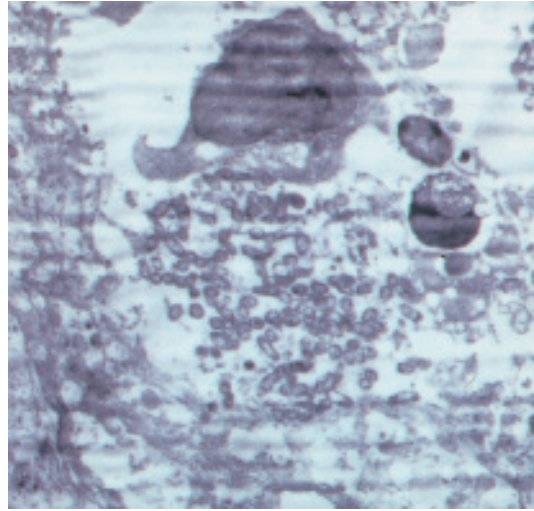


Fig 1. Gram-negative bacilli *Bartonella henselae* in a visceral lymph node. Photograph taken by Dr. C. Van Den Broecke, Department of Anatomopathology, University Hospital Ghent.

examination of the right eye revealed no particularities. Examination of the left eye showed disc edema, especially in the superior segment, with minimal macular edema (fig. 2a). Visual field testing revealed a mild left central scotoma. She was not given treatment initially and on examination 4 days later the visual acuity in her left eye had improved to 20/30. Ophthalmoscopy of the left eye now showed disc edema surrounded by flame-shaped hemorrhages and a macular star pattern of lipid exudates. Additionally, there was a white retinal focus superotemporal to the fovea (Fig. 2b).

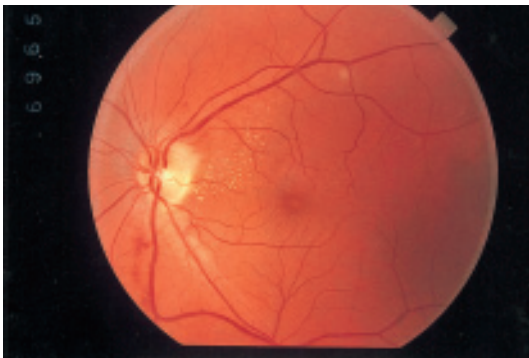

Fig 2a. Severe disc edema with minimal macular edema and a retinal focus superotemporal to the fovea.

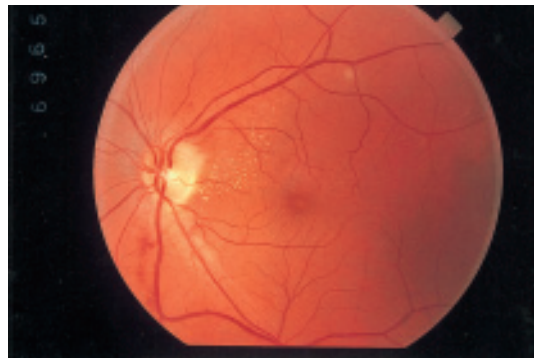

Fig 2b. Disc edema with flame-shaped hemorrhages, macular star exudates and a retinal focus superotemporal to the fovea.

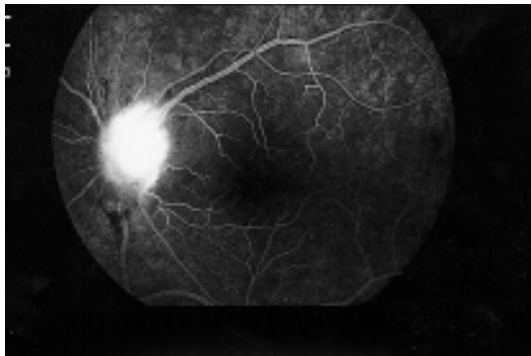

Fig 3. Staining of the optic disc and the superotemporal focus on fluorescein angiography.

Fluorescein angiography of the left eye demonstrated staining of the optic disc (especially superiorly) and of the superotemporal focus (Fig. 3). Color vision, contrast sensitivity and electroretinography of both eyes were within normal limits. Visually evoked potentials of the left eye showed slightly increased latencies. Several basic investigations were all found to be normal: a complete blood examination, chest X-ray, abdominal ultrasound, angiotensin-converting enzyme level, neurological examination including lumbar puncture and neuroimaging. The erythrocyte sedimentation rate was slightly elevated. Serologic tests for Lyme disease, syphilis and toxoplasmosis were negative. Serological indirect immunofluorescence tests detected antibodies to *B. henselae* at a dilution of 1/256, confirming the diagnosis of neuroretinitis caused by CSD. She was treated with oral ciprofloxacin 1g/day for 2 weeks. Follow-up 2 months later showed complete resolution of the fundus lesions and recovery of the visual acuity in the left eye to 20/20.

#### CASE 2

An 18-year old caucasian man was referred to our department for sudden visual loss in the right eye. He reported no viral prodrome and had no cats. Best corrected visual acuity was 20/70 in the right eye and 20/20 in the left eye. Biomicroscopy was unremarkable in both eyes. An afferent pupillary defect was present in the right eye. Fundus examination of the right eye revealed disc edema surrounded by retinal hemorrhages, venous dilation and a focal lesion superotemporal to the disc. The fundus of the

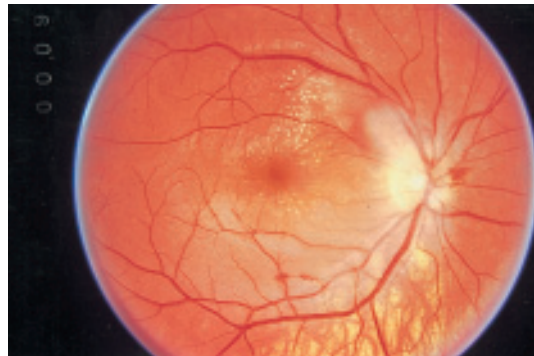

Fig 4. Disc edema with flame-shaped hemorrhages, venous dilation and macular star exudates. Note the retinal focus superotemporal to the disc.

left eye was normal. Examination one week later showed a similar clinical picture with macular star exudates (Fig. 4). A general examination revealed no scratch or papule, nor any lymphadenopathy. Basic investigations including a complete blood examination, chest X-ray, abdominal ultrasound and neuroimaging showed no abnormalities. Serology for *B. henselae* was positive at a dilution of 1/512. The patient was treated with doxycycline 100 mg/day for 6 weeks. At a follow-up visit one month later the fundus findings were essentially unchanged but the visual acuity in the right eye was restored to 20/20.

#### CASE 3

A 42-year old caucasian man complained of sudden blurred vision in the right eye. He mentioned a recent episode of malaise and had a cat at home.

Visual acuity was counting fingers in the right eye and 20/20 in the left eye. No afferent pupillary defect was detected. Slit-lamp examination revealed no inflammation. Fundus examination of the right eye showed disc edema with a focal lesion temporal to the disc and a peripapillary serous retinal detachment (Fig. 5). Examination of the left eye was normal.

Fluorescein angiography demonstrated late leakage from the optic nerve and the temporal focus. Serologic testing was negative for Lyme disease and toxoplasmosis. Bartonella IgM titers were positive at a dilution of 1/128. The patient was treated with doxycycline 100mg/day for two weeks. Follow-up 1 month later

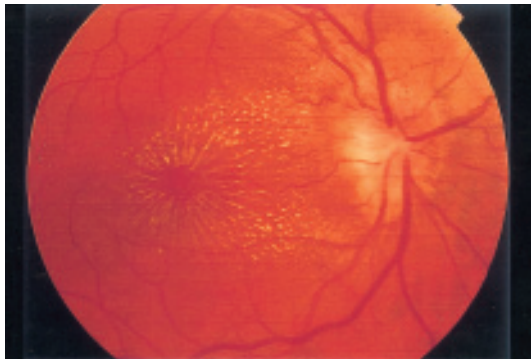


Fig 5. Disc edema, peripapillary serous retinal detachment and a macular star. Note again the retinal focus temporal to the disc.-

showed formation of a macular star with regression of the disc edema and the temporal focus. Two months after the initial visit the visual acuity of the right eye had improved to 20/20. The macular star, still present at that time, faded away over the next month.

## DISCUSSION

CSD is a self-limited infectious disease that primarily affects the lymphatic system. It appears to affect patients of any age with a higher prevalence among youngsters and without a predilection for either sex. Domestic cats are a major reservoir for *B. henselae*, the causative agent of CSD. This agent was first described by Wear and coworkers in 1983 (22). They identified a pleomorphic gram-negative bacillus in a lymph node from a patient with CSD using the Whartin-Starry silver method. In 1990 Relman and coworkers identified a new pathogen as a cause of bacteremia, bacillary angiomas and bacillary splenitis: *Rochalimaea henselae* (13). This previously unknown organism was closely related to the causative agent of trench fever, at that time named *Rochalimaea quintana* and it was suggested that it be named *Rochalimaea henselae* (16,23).

Brenner and coworkers revealed that the *Rochalimaea henselae* species were closely related to *Bartonella bacilliformis*, the agent of oroya fever and verruga peruana in Peru and Ecuador (1). A new reclassification in 1993 changed the genus *Rochalimaea henselae* in the Bartonella species. Studies suggested that not only fleas, but also the human body louse, the sar-

id fly and ticks are potential vectors in the transmission of the Bartonella species (10).

*B. henselae* seropositivity in cats varies depending on the geographic region and the climate conditions (15). The frequency of infection in cats seems to be higher in regions with more fleas (7).

Typically, a scratch by a cat, especially a kitten, is followed after a variable incubation period of three to ten days by unilateral regional lymphadenopathy. An erythematous papule or pustule may be present at the site of inoculation. The infection may be asymptomatic or cause a systemic illness with fever, malaise, night sweats and painful regional lymphadenopathy. Occasionally CSD may cause a more severe picture with involvement of the central and peripheral nervous system, liver, spleen, lung, bone, skin and eye (18).

The eye is the most commonly affected non-lymphatic organ and many ophthalmic manifestations of CSD have been reported: neuroretinitis, chorioretinitis, serous detachment of the macula, optic neuritis, anterior and posterior uveitis and Parinaud's oculoglandular syndrome (2). The most common association appears to be the oculoglandular syndrome of Parinaud, affecting approximately 5% of symptomatic patients and characterized by fever, granulomatous conjunctivitis and regional lymphadenopathy (2).

Neuroretinitis, formerly known as Leber's (idiopathic) stellate retinopathy, is characterized by unilateral acute visual loss, optic disc edema, lipid exudation in the macula arranged in a star configuration and one or more foci of chorioretinitis (8).

Gass demonstrated in 1977 that the tissue primary involved appears to be the optic nerve head vasculature. Abnormal permeability of the small capillaries on the optic nerve results in leakage of lipid-rich exudate in the subretinal space. He hypothesized that the macular star is due to reabsorption of the serous component of this exudate leaving lipid precipitates in the outer plexiform layer of the macular region. These observations led him to the conclusion that this clinical entity should preferentially be called neuroretinitis rather than a retinopathy or a maculopathy (5).

Neuroretinitis secondary to CSD is typically unilateral, although bilateral cases have been de-

scribed (21). Generally, patients present with abrupt unilateral visual loss. Most patients have features of optic neuropathy.

Anterior chamber cells and flare may be present and posterior vitreous cells are common. All patients have optic edema and a peripapillary serous detachment. Nerve fiber layer splinter hemorrhages are occasionally seen. After 1 to 2 weeks when the serous fluid resolves, a macular star begins to precipitate. These lipid exudates disappear after a few to several months and may leave retinal epithelial pigment defects behind.

Foci of retinitis or choroiditis have been described (17). They can be multiple or isolated. Our three patients presented with an isolated focus in association with disc edema and a macular star. In two cases the focus appeared peripapillary. Complications of focal chorioretinitis include branch retinal artery (3,17) and vein occlusions (3), and localized serous detachment (25).

Several other infectious diseases may produce a similar clinical picture and should be ruled out: syphilis, Lyme disease, leptospirosis, toxoplasmosis, toxocariosis and tuberculosis.

The diagnosis of CSD is confirmed by a positive serology of the causative agent.

In 1992 Regnery and coworkers introduced indirect fluorescent antibody testing for *Bartonella henselae* with 88% sensitivity and 96% specificity. They also established a 3% incidence of significant titers against *B. henselae* in the healthy population (12).

Different test assays [immunofluorescent assays (IFA), immunoblot] have been used for the serodiagnosis of CSD. The sensitivity and specificity varies according to which test has been used. IFA seems to be the most popular and reliable test (14). The highest antibody titers seem to be detected in weeks 0-16 after the onset of the lymphadenopathy (26).

However, IgG antibodies may occasionally be low or even negative in the early stage of the disease (4). In such case, a second serum specimen must confirm the diagnosis. A seroconversion, a high titer of  $\geq 1:512$  or a fourfold increase in a second sample is indicative of CSD (11,27).

It is at present unclear which proportion of all cases with neuroretinitis is due to CSD. In 1999 Suhler and coworkers attempted to determine

the percentage of neuroretinitis caused by CSD, based upon a positive serology. They found a seropositivity for *Bartonella henselae* in 65.3% of tested patients with neuroretinitis (19). This result is much higher than the 3% incidence in the general population, found by Regnery and coworkers, implying that CSD is one, if not the single most important cause of neuroretinitis. The optimal treatment for CSD is unknown due to a lack of adequate clinical trials. *B. henselae* seems to be sensitive in vitro to a number of antibiotics: erythromycin, doxycycline, ciprofloxacin, rifampicin and trimethoprim-sulfamethoxazole. Doxycycline (100mg orally twice daily) is preferred: it has better ocular and central nervous system penetration. It is usually given 2 to 4 weeks in immunocompetent patients and 4 months in immunocompromised patients (9). The benefit of antibiotic therapy in immunocompetent patients with CSD has never been demonstrated and before the identification of *B. henselae*, most immunocompetent patients tended to do well without any treatment.

Summarizing these data, *B. henselae* is the primary cause of neuroretinitis. The diagnosis should be based upon clinical findings and confirmed by a positive serology for *B. henselae*. *B. henselae*-associated ocular complications are usually self-limiting but may be treated with doxycycline.

#### REFERENCES

- (1) BRENNER D.J., O'CONNOR S.P., WINKLER H.H., STEIGERWALT A.G. – Proposals to unify the genera *Bartonella* and *Rochalimaea*, with descriptions of *Bartonella quintana* comb. nov., *Bartonella vinsonii* comb. nov., *Bartonella henselae* comb. nov., and *Bartonella elizabethiae* comb. nov., and to remove the family Bartonellaceae from the order Rickettsiales. Int J System Bacteriol 1993; 43:777-786.
- (2) CARITHERS H.A. – Cat scratch disease: an overview based on a study of 1200 patients. Am J Dis Child 1985; 139:1124-1133.
- (3) COHEN S.M., DAVIS J.L., GASS J.D.M. – Branch retinal arterial occlusions in multifocal retinitis with optic nerve edema. Arch Ophthalmol 1995; 113:1271-1276.
- (4) DEMERS D.M., BASS J.W., VINCENT J.M., PERSON D.A., NOYES D.K., STAEGE C.M.,

- SAMLASKA C.P., LOCKWOOD M.H., REGNERY R.L., ANDERSON B.E. – Cat scratch disease in Hawaii: etiology and seroepidemiology. *Journal of Pediatrics* 1995; 126:23-26.
- (5) GASS J.D.M. – Diseases of the optic nerve that may simulate macular disease. *Trans Am Acad Ophthalmol Otolaryngol* 1977; 83:763-70.
- (6) HUANG M.C., DREYER E. – Parinaud's oculoglandular conjunctivitis and cat-scratch disease. *Int Ophthalmol Clin* 1996; 36:29-36.
- (7) JAMESON P., GREENE C., REGNERY R., DRYDEN M., MARKS A., BROWN J., COOPER J., GLAUS B., GREENE R. – Prevalence of *Bartonella henselae* antibodies in pet cats throughout regions of North America. *J Infect Dis* 1995; 172:1145-1149.
- (8) KING M.H., CARTWRIGHT M.J., CARNEY M.D. – Leber's idiopathic stellate neuroretinitis. *Ann Ophthalmol* 1991; 23:58-60.
- (9) KOEHLER J.E., RELMAN D.A. – Bartonella species. In: Yu WL, Merigan TC jr, Barriere SL, editors. *Antimicrobial therapy and vaccines*. Baltimore: Williams and Wilkins, 1999: pp 78-583.
- (10) MAURIN M., BIRTLES R.J., RAOULT D. – Current knowledge of Bartonella species. *Eur J Clin Microbiol Infect Dis* 1997; 16:487-506.
- (11) NADAL D., ZBINDEN R. – Serology to *Bartonella (Rochalimaea) henselae* may replace traditional diagnostic criteria for cat scratch disease. *Eur J Ped* 1995; 154:906-908.
- (12) REGNERY R.L., OLSON J.G., PERKINS B.A., BIBB W. – Serological response to "*Rochalimaea henselae*" antigen in suspected cat-scratch disease. *Lancet* 1992; 339:1443-5.
- (13) RELMAN D.A., LOUIT J.S., SCHMIDT T.M., FALKOW S., TOMPKINS L.S. – The agent of bacillary angiomatosis. An approach to the identification of uncultured pathogens. *N Engl J Med* 1990; 323:1573-1580.
- (14) SANDER A., BERNER R., RUESS M. – Serodiagnosis of cat scratch disease: response to *Bartonella henselae* in children and a review of diagnostic methods. *Eur J Clin Microbiol Infect Dis* 2001; 20:392-401.
- (15) SANDER A., BARTONELLOSIS – In: Cimolai N (ed): *Laboratory diagnosis of bacterial infections*. Marcel Decker, New York (2001) pp 653-686.
- (16) SLATER L.N., WELCH D.F., HENSEL D., COODY D.W. – A newly recognized fastidious gram-negative pathogen as a cause of fever and bacteremia. *N Eng J Med* 1990; 323:1587-1593.
- (17) SOLLEY W.A., MARTIN D.F., NEWMAN N.J., NEWMAN N.J., KING R., CALLANAN D.G., ZACCHEI T., WALLACE R.T., PARKS D.J., BRIDGES W., STERNBERG P. – Cat scratch disease: posterior segment manifestations. *Ophthalmology* 1999; 106:1546-1553.
- (18) SPACH D.H., KOEHLER J.E. – Bartonella-associated infections. *Infect Dis Clin North Am* 1998; 12:137-155.
- (19) SUHLER E.B., LAUER A.K., ROSENBAUM J.T. – Prevalence of serologic evidence of cat scratch disease in patients with neuroretinitis. *Ophthalmology* 2000; 107:871-876.
- (20) SUHLER E.B., MACRAE S.M. – Cat scratch disease. In: Fraunfelder FT, Roy FH, eds. *Current Ocular Therapy*, 5(th) ed. Philadelphia: Saunders, 1999; 16-7.
- (21) WADE N.K., PO S., WONG I.G., CUNNINGHAM ET jr. – Bilateral Bartonella-associated neuroretinitis. *Retina* 1999; 19:355-356.
- (22) WEAR D.J., MARGILETH A.M., HADFIELD T.L., FISHER G.W., SCHLAGEL C.J., KING F.M. – Cat scratch disease. A bacterial infection. *Science* 1983; 112:365-71.
- (23) WELCH D.F., PICKETT D.A., SLATER L.N., STEIGERWALT A.G., BRENNER D.J. – *Rochalimaea henselae* sp. Nov., a cause of septicemia, bacillary angiomatosis, and parenchymal bacillary peliosis. *J Clin Microbiol* 1992; 30:275-280.
- (24) WONG M.T., DOLAN M.J., LATTUADA C.P. jr, et al. – Neuroretinitis, aseptic meningitis, and lymphadenitis associated with *Bartonella (Rochalimaea) henselae* infection in immunocompetent patients and patients infected with human immunodeficiency virus type 1. *Clin Infect Dis* 1995; 21:352-60.
- (25) ZACCHEI A.C., NEWMAN N.J., STERNBERG P. – Serous retinal detachment of the macula associated with cat-scratch disease. *Am J Ophthalmol* 1995; 20:796-797.
- (26) ZANGWILL K.M., HAMILTON D.H., PERKINS B.A., REGNERY R.L., PLIKAYTIS B.D., HADLER J.L., CARTTER M.L., WENGER J.D. – Cat scratch disease in Connecticut. Epidemiology, risk factors, and evaluation of a new diagnostic test. *N Engl J Med* 1993; 329:8-13.
- (27) ZBINDEN R., MICHAEL N., SEKULOVSKI M., VON GRAEVENITZ A., NADAL D. – Evaluation of commercial slides for detection of immunoglobulin G against *Bartonella henselae* by indirect immunofluorescence. *Eur J Clin Microbiol&Infect Dis* 1997; 16:648-652.
- .....

Correspondence and reprints:  
 Philippe Kestelyn, M.D., Ph.D.  
 Department of Ophthalmology, University Hospital  
 Ghent  
 De Pintelaan 185, B-9000 Ghent, Belgium.









