

---

# (HYDROXY) - CHLOROQUINE RETINAL TOXICITY: TWO CASE REPORTS AND SAFETY GUIDELINES

HERMAN K. \*, LEYS A. \*, SPILEERS W. \*

---

## SUMMARY

Retinal toxicity as a result of antimalarial therapy has been reported for many years.

Retinopathy may be divided into reversible pre-maculopathy and irreversible true retinopathy.

Risk factors for the development of toxicity are daily dosage related to body weight, total drug dosage and the specific drug used. The daily dosage of chloroquine should not exceed 4 mg/kg lean body weight a day. Exceeding the total dosage of 300 g increases the risk. The daily dosage of hydroxychloroquine should not exceed 6.5 mg/kg lean body weight a day with increased risk when the duration of treatment exceeds 8 years (1330 g for a patient of 70 kg). Regular dilated fundus examination, visual field testing using Amsler grid test and automated central 10-2 perimetry (to a red test object) is advised to detect reversible pre-maculopathy. Hydroxychloroquine toxicity due to excessive cumulative dosage is discussed in case 1. Chloroquine toxicity due to excessive daily dosage is discussed in case 2.

## RÉSUMÉ

La toxicité rétinienne induite par les médicaments antipaludiques a été décrite depuis de nombreuses années. On distingue d'une part la rétinopathie pré-maculaire réversible et d'autre part la vraie rétinopathie irréversible. La dose quotidienne en fonction du poids corporel, la dose cumulative et le type de médicaments utilisés sont les facteurs de risque. La dose quotidienne de chloroquine ne doit pas dépasser

4 mg/kg par jour sur base du poids idéal du patient. Une dose cumulative supérieure à 300 g augmente le risque de rétinopathie. La dose quotidienne d'hydroxychloroquine ne doit pas dépasser 6.5 mg/kg par jour sur base du poids idéal du patient. Par ailleurs le risque de rétinopathie est réel si la durée du traitement est supérieure à 8 ans (1330 g pour un patient de 70 kg). Un examen régulier du fond d'oeil dilaté, un examen du champ visuel utilisant d'une part la grille d'Amsler et d'autre part la périmétrie automatisée centrale 10.2 (stimulus rouge) sont nécessaires afin de détecter une pré-maculopathie réversible. Nous présentons deux cas de toxicité rétinienne. Le premier illustre la toxicité d'hydroxychloroquine due à une dose cumulative excessive. Le second illustre la toxicité de chloroquine due à une dose quotidienne excessive.

## KEY-WORDS

chloroquine, hydroxychloroquine, retinal toxicity, safety guidelines, dosage monitoring

## MOTS-CLÉS

chloroquine, hydroxychloroquine, toxicité rétinienne, recommandations de dépistage, monitoring de la dose

.....

\* *Dienst Oogziekten, UZ Leuven*

received: 15.02.02

accepted: 04.04.02

## INTRODUCTION

The antimalarial agents chloroquine and hydroxychloroquine have been used since the 1950's to treat inflammatory disorders, including systemic lupus and rheumatoid arthritis. Soon after their introduction for chronic use, concerns arose about their ocular safety. The relationship between chloroquine and retinal toxicity was first reported by Cambioggi in 1957 in a patient undergoing treatment for systemic lupus erythematosus (5). Since that report, the retinal damage produced by chloroquine (Nivaquine®) and hydroxychloroquine (Plaquenil®) has become probably the most feared of all ocular toxic drug reactions. Indeed, the risk of retinal toxicity has caused many rheumatologists and dermatologists to abandon or severely restrict the use of these agents. In this study we present two case reports and outline the retinal side effect of antimalarial drugs. The screening methods to rule out possible ocular toxicity, the dose monitoring guidelines and the follow-up strategy are subsequently discussed.

## PATIENTS AND METHODS

Two patients with antimalarial retinal toxicity are discussed in this report using a retrospective review of their case notes between 1996-2001.

## CASE REPORTS

### CASE 1:

A 67-year old woman with a 20-year history of rheumatoid arthritis had a recent onset of decreased central vision. She had been taking a daily dose of 250 mg of hydroxychloroquine (3.2 mg/kg per day) for 17 years (cumulative dose of 1551g). Corrected visual acuity was 5/10, Snellen 4 at the right eye and 4/10, Snellen 4 at the left eye. Fundus examination showed a ring of depigmentation surrounded by a ring of hyperpigmentation in both eyes. Fluorescein angiography showed window defects in a bull's eye pattern bilaterally (Figure 1). Static perimetry with a white test object (Humphrey Field Analyzer 30-2) showed absolute pericentral scotoma in both eyes (Figure 2). Bilateral pericentral scotomata were also demonstrated by Amsler grid testing. Full-field flash-electroretinograms recorded from both eyes were extinguished (Figure 3). Hydroxychloroquine treatment was discontinued and a follow-up at 36 months after treatment disclosed neither further deterioration nor improvement of visual function.

### CASE 2:

A 69-year old woman with a long standing history of mutilating rheumatoid arthritis (both legs had been amputated) was referred to our department because of a recent onset of central scotomata in both eyes. For the last 2 years she had been treated with a magistral drug for

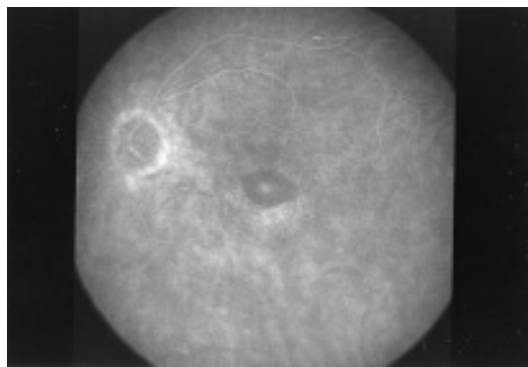
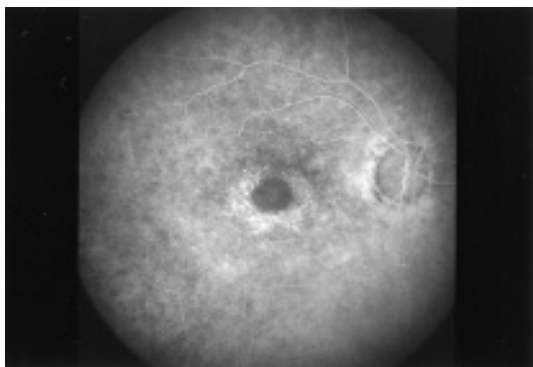



Fig 1. Case 1. Fluorescein angiogram of right eye (left) and left eye (right) showing window defects in a bull's eye pattern.

Fixation Monitor: Gaze/Blindspot  
 Fixation Target: Central  
 Fixation Losses: 0/15  
 False POS Errors: 1 %  
 False NEG Errors: 10 %  
 Test Duration: 07:32  
 Stimulus: III, White  
 Background: 31.5 ASB  
 Strategy: SITA-Fast  
 MD -23.97 dB P < 0.5%  
 PSD 10.59 dB P < 0.5%



Fixation Monitor: Gaze/Blindspot  
 Fixation Target: Central  
 Fixation Losses: 0/16  
 False POS Errors: 1 %  
 False NEG Errors: 18 %  
 Test Duration: 07:46  
 Stimulus: III, White  
 Background: 31.5 ASB  
 Strategy: SITA-Fast  
 MD -19.91 dB P < 0.5%  
 PSD 11.74 dB P < 0.5%




Fig 2. Case 1. Static perimetry demonstrates large central scotomata on testing with a white test object in the right eye (left) and the left eye (right) (Humphrey Field Analyzer 30-2).

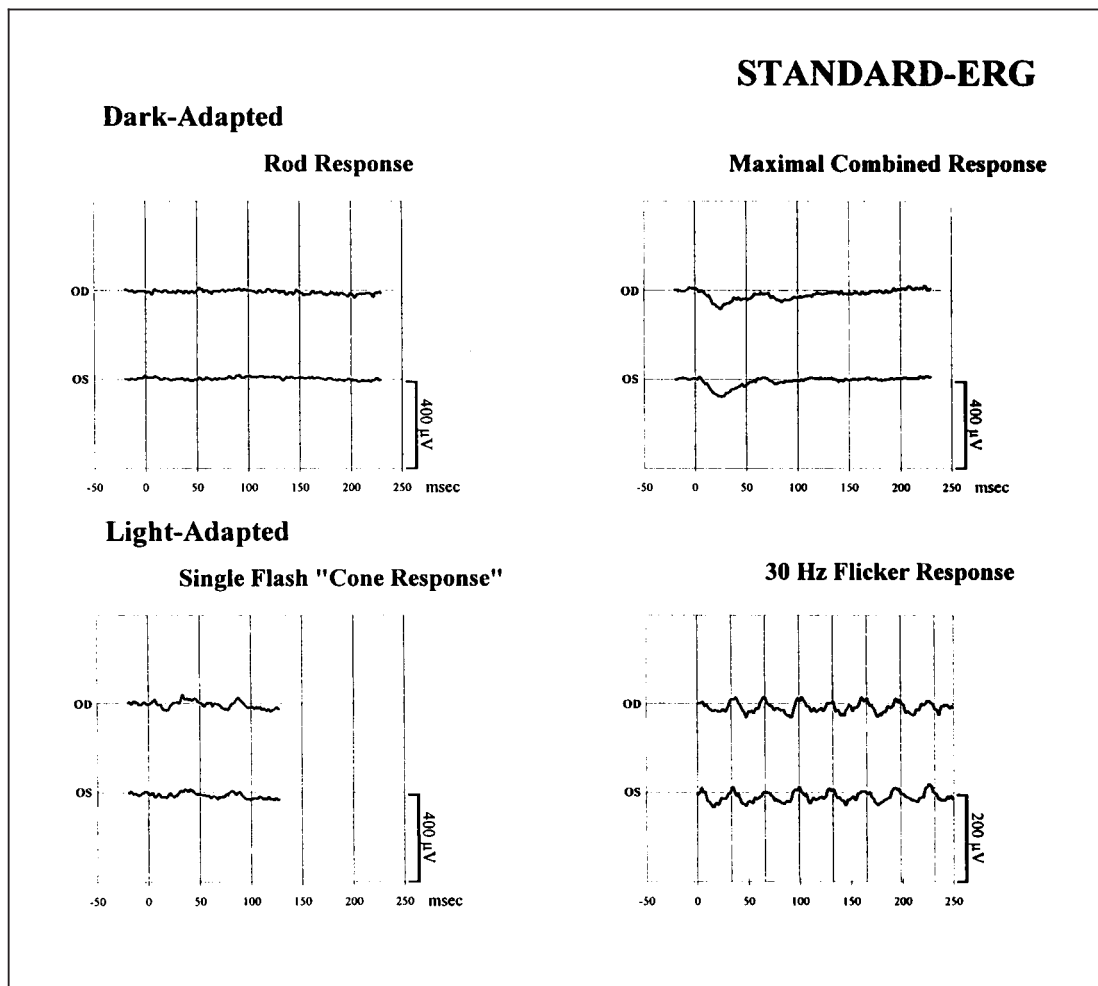


Fig 3. Case 1. Full-field flash-electroretinogram shows the extinguished dark adapted rod response; maximal combined response and the light adapted single flash cone response and 30 Hz flicker response for both eyes.

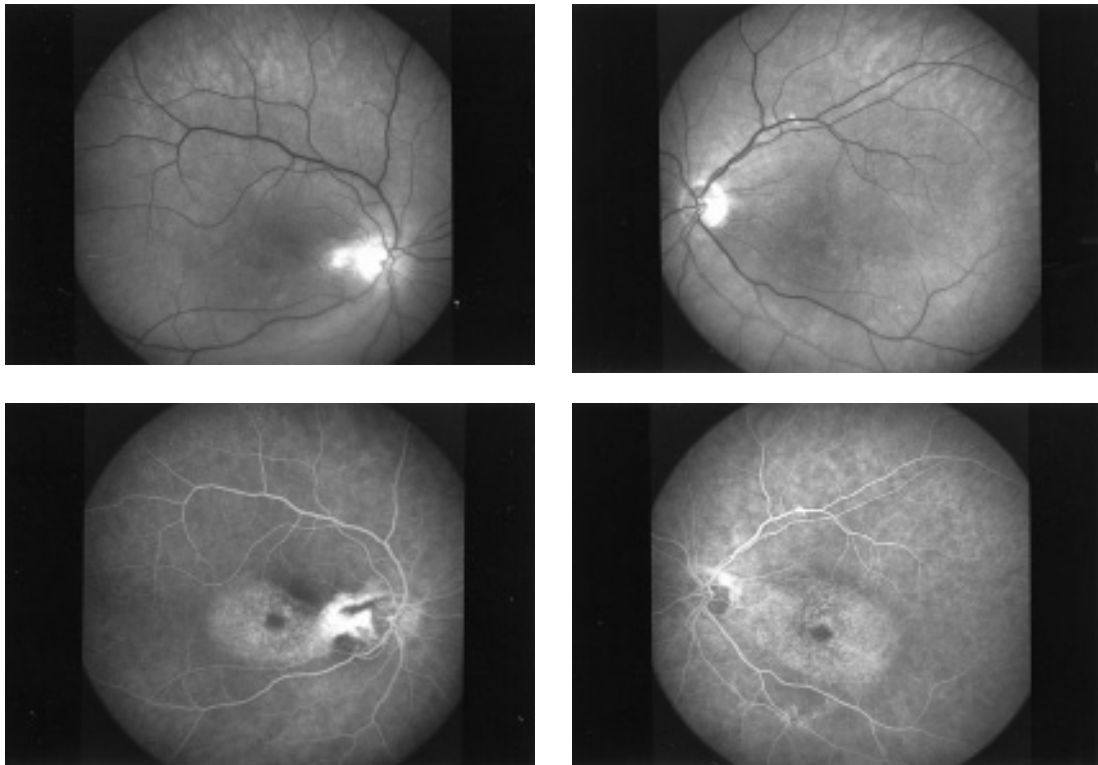


Fig 4. Case 2. Top: Red free image of the right eye (left) and the left eye (right) of a patient with hydroxychloroquine retinopathy. Bottom: Fluorescein angiogram of right eye (left) and left eye (right) showing window defects in a bull's eye pattern.

persistent joint ache in the upper limbs and back pain. This preparation contained chloroquine 250mg/d. She only weighted 36 kg, giving a daily dose of chloroquine of 6.95 mg/kg per day. Corrected visual acuity was 7/10, Snellen 3 to both eyes. Fundus examination showed a typical bull's eye maculopathy in both eyes. Fluorescein angiography showed window defects in a bull's eye pattern bilaterally (Figure 4). Static perimetry with a white test object (Humphrey Field Analyzer 30-2) showed deep central scotomas in both eyes (Figure 5). Bilateral pericentral scotomata were also demonstrated by Amsler grid testing. Full-field flash-electroretinograms recorded from both eyes were severely decreased (Figure 6). The electro-oculogram (EOG) was also performed. The Arden ratio for both eyes was decreased: 1.70 for the right eye and 1.56 for the left eye (Figure 7) (A score of 1.8 is considered to be the lower normal limit). The prescription containing chloroquine was discontinued and a fol-

low-up at 48 months after treatment disclosed neither further deterioration nor improvement of visual function.

## DISCUSSION

### RETINAL TOXICITY:

Retinal toxicity due to (hydroxy)-chloroquine may be separated into premaculopathy and true maculopathy. **Premaculopathy** consists of fine pigmentary stippling or mottling without loss of visual acuity. There is visual field loss to a red test object with the parafoveal 10 degrees being the initial site of visual field defects. It usually reverses after the medication has been stopped and has never been reported to start or to progress after the drug discontinuation (22). **True retinopathy** is associated with more prominent pigmentary changes, which may include a bull's eye lesion: granular pigmenta-

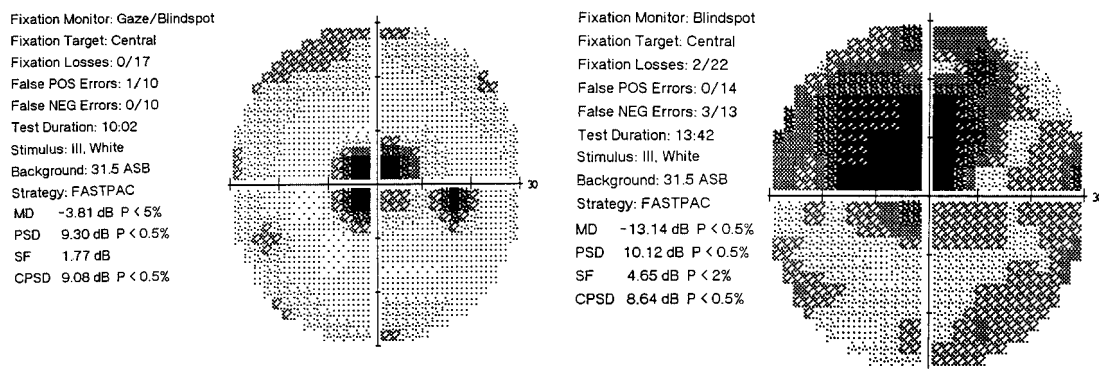


Fig 5. Case 2. Static perimetry demonstrates large deep central scotomata on testing with a white test object in the right eye (left) and the left eye (right) (Humphrey Field Analyzer 30-2).

tion of the macula surrounded by a clear zone of deep pigmentation surrounded in turn by another ring of pigmentation (22). Pigmentary changes are mild or even absent in patients with skin type I and II (reddish and blond hair). With more extensive damage to the retina, the arterioles show generalized attenuation and segmental constriction with pallor of the optic disc. A fine granularity of the retina and prominent choroidal pattern in the periphery may also occur (16). Scotomata are evident with suprathreshold white test objects and visual acuity may be lost. Changes are often permanent and may even progress after the medication is stopped (2,21).

There is no general consensus on the minimum findings needed to define true maculopathy. Currently, there are 2 commonly cited definitions of ocular toxicity. Bernstein's definition requires the development of persistent paracentral or central visual field scotomata to suprathreshold white stimuli and a duration of treatment of > 9 months (2). Easterbook advocated the use of bilateral, reproducible, positive field defects that can be shown by 2 different visual field tests, Amsler grid test and an automated 10-degree visual field test, as definitive evidence of retinal toxicity (10). In the absence of visual field changes, the pigmentary changes must consist of actual retinal pigment epithelial loss, sometimes resembling a bull's eye lesion (20). Several maculopathies share phenotypic similarities with (hydroxy)-chloroquine retinopathy. Premaculopathy should be differentiated from macular changes associated with age-related macular degeneration. True macu-

lopathy should be differentiated from combined cone and rod dystrophies, classical cone dystrophies, neuronal ceroid lipofuscinosis, Stargardt's disease and fenestrated sheen macular dystrophy (23). The most common presenting symptoms of antimalarial retinopathy are difficult reading, photophobia, blurred distance vision, central visual field scotomas and entopic phenomenon. Since patients are asymptomatic despite abnormal fundi or visual field defects in the reversible premaculopathy stage, the ophthalmologist's challenge is to detect evidence of retinopathic changes before irreversible damage develops.

#### EXAMINATION AND TESTING:

Numerous tests have been proposed for screening, and the variety suggests lack of an ideal one.

a) *Color vision* testing has generally been found to be unhelpful. Color vision is essentially undisturbed in early cases of retinopathy as tested with the Farnsworth 15 color Hue test and with the pseudoisochromatic H-R-R color plates (16). Others have found normal color vision even in the presence of scotomas or macular mottling (14,19).

b) *Fundoscopy*: With early retinopathy the foveal reflex is lost and fine pigmentary stippling or mottling is present. Since early age related macular degeneration exhibits similar findings, the differential diagnosis is difficult leading to overdiagnosis of drug induced toxicity (16).

c) *Fluorescein Angiography (FA)*: Since the development of scotomas precedes abnormali-

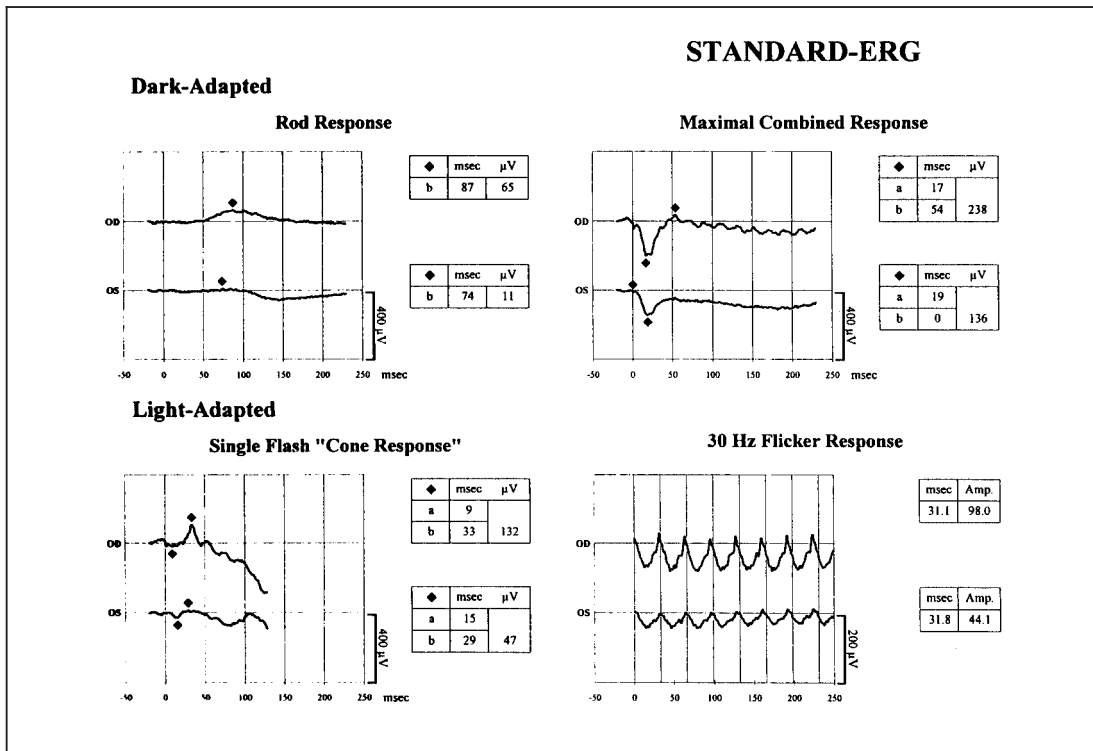


Fig 6. Case 2. Full-field flash-electroretinogram shows the decreased dark adapted rod response and maximal combined response and the light adapted single flash cone response and 30 Hz flicker response for both eyes.

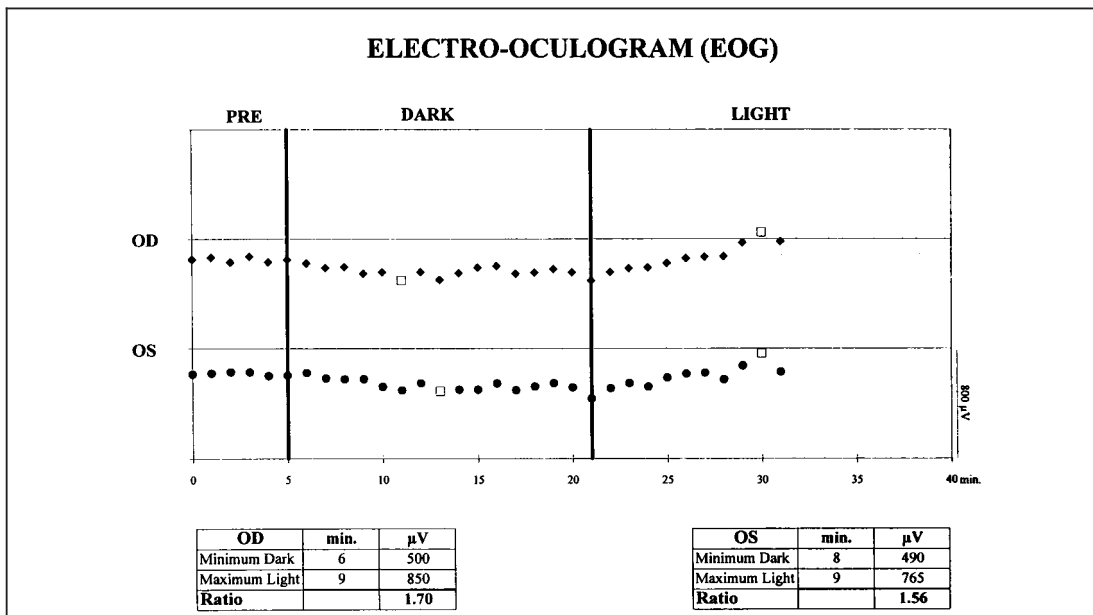


Fig 7. Case 2. The electro-oculogram recorded from both eyes shows the decreased Arden ratio: 1.70 for the right eye and 1.56 for the left eye.



ties detected by FA, this test has little merit in establishing early retinopathy (18). In older patients with age related macular degeneration however, FA may help to distinguish the macular changes associated with antimalarial retinopathy (8). Visual field testing may not be reliable in elderly patients, in these cases FA may be useful. As pigmentary changes are mild or almost absent in patients with skin type I and II (reddish and blond hair), FA helps to identify subtle pigmentary alterations.

d) *Visual Field Testing: Automated static threshold perimetry* has revealed pericentral visual field defects in patients with antimalarial retinopathy. Studies comparing automated and non-automated static and kinetic perimetry indicate that automated perimetry yields the greatest sensitivity in assessing macular function in patients with retinopathy (9). The Humphrey 10-2 program tests 68 points in the central 10 degrees of vision. Results could be further enhanced using a red test target, making it possible to reveal scotomata in the reversible pre-maculopathy stage (22).

*Non-automated static or kinetic perimetry* is helpful in patients who are unable to perform automated perimetry due to physical limitations or low test reliability.

The use of the *Amsler grid* in chloroquine retinopathy was suggested by Carr et al (6). The Amsler grid is an excellent means of screening for early antimalarial retinopathy. It will pick up very small scotomata even before they can be demonstrated by kinetic and static field testing (7,13). The standard Amsler grid, the red Amsler grid and the poster-sized one meter modified Amsler grid can be used (2,22). The Amsler grid is simple, inexpensive, reproducible, and self-administrable by a cooperative patient, making it an excellent screening test.

e) *Electro-Oculography (EOG)*: Since the electro-oculogram reflects the metabolic integrity of the retinal pigment epithelium, it was believed that EOG would detect early retinal changes in patients receiving antimalarial drugs. However, the prognostic significance of the test is quite limited. A poor correlation between macular changes and the EOG, high interindividual variability over a period of time, preexisting low EOG values among patients with rheumatoid arthritis and the influence of the disease activity itself

on EOG results limit its usefulness as a screening test (3,8).

f) *Flash-Electroretinogram (ERG)*: ERG findings are normal when macular damage alone is present and diminish only as diffuse retinal damage occurs. There is no evidence that ERG can be of real value in predicting the onset of retinal damage (22).

#### DOSAGE SCHEDULE AND RETINOPATHY:

A number of factors have been implicated in the development of retinopathy. The important contributors are daily dosage, total drug dosage, renal and liver function, genetic predisposition and the specific drug used.

a) *Daily dosage*: Mac Kenzie has shown that the risk of retinopathy can be reduced by calculating the daily dosage according to body weight. In overweight individuals one should use the ideal or lean body weight based on age, sex and height. For hydroxychloroquine the daily dosage should not exceed 6.5 mg/ kg lean body weight/ day. For chloroquine the daily dosage should not exceed 4 mg/ kg lean body weight/ day. Exceeding the recommended daily dosage sharply increases the risk of retinal toxicity (12,17).

b) *Cumulative dosage*: Retinal changes are uncommon in patients taking the recommended daily dosage of chloroquine if the cumulative dosage does not exceed 300g (12). With hydroxychloroquine, toxicity on low daily dosage has occurred only when the duration of treatment exceeded 8 years (1).

c) *Renal and liver function*: Patients taking a fixed daily dosage corresponding to Mac Kenzie's guidelines might be overdosed if hepatic and renal failure is present (24).

d) *Genetic predisposition*: Some individuals with an ABCR mutation may be predisposed to retinal toxicity when exposed to chloroquine or hydroxychloroquine even at recommended daily dosage (23).

#### FOLLOW-UP STRATEGY:

For practical purposes a simple screening protocol for antimalarial retinotoxicity may be used. The initial examination within 1 year of onset of treatment provides baseline observations for

any subsequent changes (12,15). Patients should be asked about visual symptoms. Visual acuity for far and near should be measured. A careful funduscopic examination of the macula for fine pigmentary disturbances should be performed. Suprathreshold scotomata can be detected with the Amsler grid test and quantitatively tested with the automated static perimetry using the red test object and central 10-2 program (12,24). Periodic ocular examination is recommended even if the dose safety guidelines are respected because of this drug's retinotoxic history and the possibility of non-drug-related ocular disease in associated systemic diseases. Patients taking chloroquine should be reviewed yearly (11). Different opinions concerning the interval of screening for patients on hydroxychloroquine are found in the literature. Some authors recommend yearly follow-up only after 5 - 10 years of treatment where others suggest a follow-up program after 2 years of treatment (4,11-13). Self-testing using the Amsler grid test once a month has become a recommended procedure (2).

## CONCLUSION

Retinal toxicity as a result of antimalarial therapy has been reported for many years. The important risk factors are daily dosage according to body weight and the total drug dosage. Correlating drug dosage to the patient's weight has shown to reduce the risk of retinopathy. Regular ocular examination and frequent screening are necessary to detect reversible premaculopathy. Patients should be instructed to screen themselves at home once a month using the Amsler grid test to detect the onset of pericentral or paracentral visual changes. Ophthalmological assessment consisting of visual acuity measurement, dilated fundus examination and automated central 10-2 perimetry (to a red test object) should be performed at baseline and follow-up.

## BIBLIOGRAPHY

- (1) BERNSTEIN H.N. – Ocular safety of hydroxychloroquine. *Ann Ophthalmol*, 1991, 23: 292-296.
- (2) BERNSTEIN H.N. – Ocular safety of hydroxychloroquine sulfate (Plaquenil). *South Med J*, 1992, 85: 274-279.
- (3) BISHARA S.A., MATAMOROS N. – Evaluation of several tests in screening for chloroquine maculopathy. *Eye*, 1989, 3: 777-782.
- (4) BLOCK J.A. – Hydroxychloroquine and retinal safety. *Lancet*, 1998, 351: 771.
- (5) CAMBIAGGI A. – Unusual ocular lesions in a case of systemic lupus erythematosus. *Arch Ophthalmol*, 1957, 57, 451-453.
- (6) CARR R., GOURAS P., GUNKEL R. – Chloroquine retinopathy. *Arch Ophthalmol*, 1966, 75: 171-178.
- (7) EASTERBOOK M.D. – The use of the Amsler grid in early chloroquine retinopathy. *Ophthalmology*, 1984, 91: 1368-1372.
- (8) EASTERBOOK M.D. – Ocular effects and safety of antimalarial agent. *Am J Med*, 1988, 85 (suppl 4a),: 23-29.
- (9) EASTERBOOK M.D., TROPE G. – Value of Humphrey perimetry in the detection of early chloroquine retinopathy. *Lens Eye Toxic Res*, 1989, 6: 255-268.
- (10) EASTERBOOK M.D. – The ocular safety of hydroxychloroquine. *Semin Arthritis Rheum*, 1993, 23 (suppl 1): 62-67.
- (11) EASTERBROOK M. – An ophthalmological view on the efficacy and safety of chloroquine versus hydroxychloroquine. *J Rheumatol*, 1999, 26: 1866-1867.
- (12) ESDAILE J.M. – Canadian consensus conference on hydroxychloroquine. *J Rheumatol*, 2000, 27: 2919-2921.
- (13) GRIERSON D.J. – Hydroxychloroquine and visual screening in a rheumatology outpatient clinic. *Ann Rheum Dis*, 1997, 56: 188-190.
- (14) HENKIND P., CARR R., SIEGLE I. – Early chloroquine retinopathy: clinical and functional findings. *Arch Ophthalmol*, 1984, 71: 157-165.
- (15) JONES S.K. – Ocular toxicity and hydroxychloroquine: guidelines for screening. *Br. J. Dermatol*, 1999, 140: 3-7.
- (16) LOZIER J.R., FRIEDLAENDER M.H. – Complications of antimalarial therapy. *Int Ophthalmol Clin*, 1989, 29: 172-178.
- (17) MACKENZIE A.H. – Dose refinements in long-term therapy of rheumatoid arthritis with antimalarials. *Am J Med*, 1983, 75 (suppl 18), 40-45.



- (18) NOZIK R.A., WEINSTOCK F., VIGNOS P. Jr. – Ocular complications of chloroquine. *Am J Ophthalmol*, 1964, 58: 774-778.
- (19) NYLANDER U. – Ocular damage in chloroquine therapy. *Acta Ophthalmol*, 1966, 44: 335-348.
- (20) RAINES M.F., BHARGAVA S.K., ROSEN E.S. – The blood-retinal barrier in chloroquine retinopathy. *Invest Ophthalmol Vis Sci*, 1989, 30: 1726-1731.
- (21) RENNIE I.G. – Clinically important ocular reactions to systemic drug therapy. *Drug Saf*, 1993, 9: 196-211.
- (22) RYNES R.I., BERNSTEIN H.N. – Ophthalmologic safety profile of antimalarial drugs. *Lupus*, 1993, 2 (suppl 2): 517-519.
- (23) SHROYER N.F., LEWIS R.A., LUPSKI J.R. – Analysis of the ABCR (ABCA4) gene in 4-aminoquinoline retinopathy: is retinal toxicity by chloroquine and hydroxychloroquine related to Stargardt disease? *Am J Ophthalmol*, 2001, 131, 761-766.
- (24) SPALTON D.J., VERDON ROE G.M., HUGHES G.R. – Hydroxychloroquine, dosage parameters and retinopathy. *Lupus*, 1993, 2: 355-358.
- .....
- Correspondence to:*  
*Kristien Herman, MD*  
*Verbindingslaan 47*  
*B-3001 Heverlee*  
*Belgium*  
*Tel: 0032 16 405366*  
*E-mail: tineherman@hotmail.com*





