
SUCCESSFUL PHOTODYNAMIC THERAPY COMBINED WITH LASER PHOTOCOAGULATION IN THREE EYES WITH CLASSIC SUBFOVEAL CHOROIDAL NEOVASCULARISATION AFFECTING TWO PATIENTS WITH MULTIFOCAL CHOROIDITIS: CASE REPORTS

COQUELET P.*, POSTELMANS L.*,
SNYERS B.***, VEROUGSTRAETE C.*

SUMMARY

Multifocal choroiditis (MC) is an idiopathic choroidal inflammatory disease affecting young subjects. Secondary choroidal - and often central - neovascularisation is a frequent complication leading to a poor visual prognosis. Photodynamic therapy (PDT) has now proven to be successful to treat classic subfoveal choroidal neovascularisation in age-related macular degeneration and in pathologic myopia. We describe the treatment applied to classic choroidal neovascularisation in two young women with MC, two eyes with subfoveal neovascular membrane and one eye in which new vessels encroach the foveal avascular zone. PDT has been useful in the three reported eyes, with stable or improved visual acuity. In two of them, it even made the membrane retract and become extrafoveal, allowing a secondary treatment using conventional laser.

.....

* *Dept. of Ophthalmology, Brugmann and Saint-Pierre University Hospitals, Brussels*

** *Dept. of Ophthalmology, St-Luc University Hospital, Brussels*

received: 28.12.01

accepted: 25.02.02

RÉSUMÉ

La choroïdite multifocale est une affection inflammatoire choroïdienne idiopathique touchant les adultes jeunes. Des néovaisseaux choroïdiens secondaires - et souvent centraux - constituent une complication fréquente provoquant une importante baisse de l'acuité visuelle. Actuellement, le traitement des néovaisseaux centraux, principalement de type visible, par thérapie photodynamique, est reconnu dans la dégénérescence maculaire liée à l'âge et chez les myopes. Nous rapportons les cas de deux jeunes femmes (trois yeux) présentant des néovaisseaux choroïdiens visibles sur choroïdite multifocale. Dans deux yeux, les néovaisseaux sont rétrofovéolaires, et, dans un oeil, ils empiètent sur la zone avasculaire centrale. Un traitement par PDT a été appliqué aux trois yeux, avec une stabilisation ou une amélioration de la vision. Dans deux d'entre eux, la membrane néovasculaire s'est rétractée en dehors de la fovéa, permettant un traitement complémentaire par laser conventionnel.

KEY-WORDS

Multifocal choroiditis, choroidal neovascularisation, photodynamic therapy, conventional laser.

MOTS-CLÉS

Choroidite multifocale, néovaisseaux choroïdiens, thérapie photodynamique, laser conventionnel.

INTRODUCTION

Multifocal choroiditis (MC) is an idiopathic inflammatory chorioretinal disease predominantly seen in middle-aged, mildly myopic women^(1, 2, 3, 6, 14). The main complaints are blurred vision, scotoma or flickering lights. During the acute phase of the disease, yellowish-grey active choroidal lesions are seen on ophthalmoscopic examination, while evolution to atrophic chorioretinal scars characterises the inactive state. In most patients, the visual prognosis is good, but in nearly one third of them, there is a significant visual loss secondary to the development of subfoveal classic choroidal neovascularisation (CNV)⁽²⁾.

CASE REPORTS

CASE 1

A young healthy 23-year old woman consulted in April 2001. She complained of blurred vision, especially while reading, and scotomas in both eyes. The vision was 5/10 in the right eye (RE) and 8/10 in the left eye (LE). No inflammation was demonstrated on slit lamp examination. The ophthalmoscopic and fluoangiographic examinations showed active classic CNV with oedema and bleedings in both eyes secondary to chorioretinal scars suspect of MC. In the RE, the membrane was subfoveal, although in the LE new vessels were superfoveal encroaching the foveal avascular zone (FAZ). A photodynamic therapy (PDT) with Verteporfin was rapidly performed in both eyes. One month later, the vision was stabilised at respectively 5/10 and 8/10, with a neovascular activity having almost disappeared in the RE. The LE showed a retraction of the CNV outside the FAZ, allowing a complementary conventional laser therapy to be applied. The vision of this eye increased progressively from 9/10 one month later to 12/10 seven months later, with no more neovascular activity detected. Despite a stabilised visual acuity of 5/10, a second PDT was

performed in the RE six months after the first one, because a little neovascular recurrence had been discovered (fig. 1).

CASE 2

A 23-year old woman consulted in January 2001, complaining of recently decreased vision and metamorphopsia in her LE. Her visual acuity was 10/10 in the RE and 3/10 in the LE, and the examination with slit lamp was normal in both eyes. An ophthalmoscopic examination, confirmed by fluorescein angiography, showed a unilateral classic subfoveal CNV developed on MC scars. In the LE, a PDT with Verteporfin was performed and, after one month, the vision increased to 8/10 in the LE, and metamorphopsia had disappeared. Examination of the fundus revealed a retracting and shrinking CNV beyond the FAZ. It was decided to perform a conventional laser photocoagulation of the neovascular membrane. After an eighth month follow-up, the visual acuity of the LE is 9/10, with no more signs of CNV activity (fig. 2).

DISCUSSION

Multifocal choroiditis is an inflammatory chorioretinal disease characterised by acute lesions that evolve into pigmented scars^(1, 2, 3, 6, 14). Although visual prognosis is good in most patients, CNV develops in about one third of the cases. Significant visual loss, often to less than 1/10 and usually due to CNV that involves the fovea, is then observed⁽²⁾. Areas of neovascularisation can be observed or treated with laser photocoagulation if extrafoveal or juxtafoveal. In subfoveal CNV secondary to MC, the efficiency of other treatments like steroids or surgical removal of the membrane has not been demonstrated yet^(4, 5, 7). The initial optimism of surgery has also been tempered by long term follow-up, which shows a high recurrence rate^(11, 12, 13). The PDT with Verteporfin has now proven to be useful in treating classic subfoveal CNV in age-related macular degeneration and in pathologic myopia^(8, 10). Verteporfin therapy is also being considered as a treatment for other causes of subfoveal CNV, particularly chorioretinal inflammatory diseases^(8, 9). One example is the ocular histoplas-

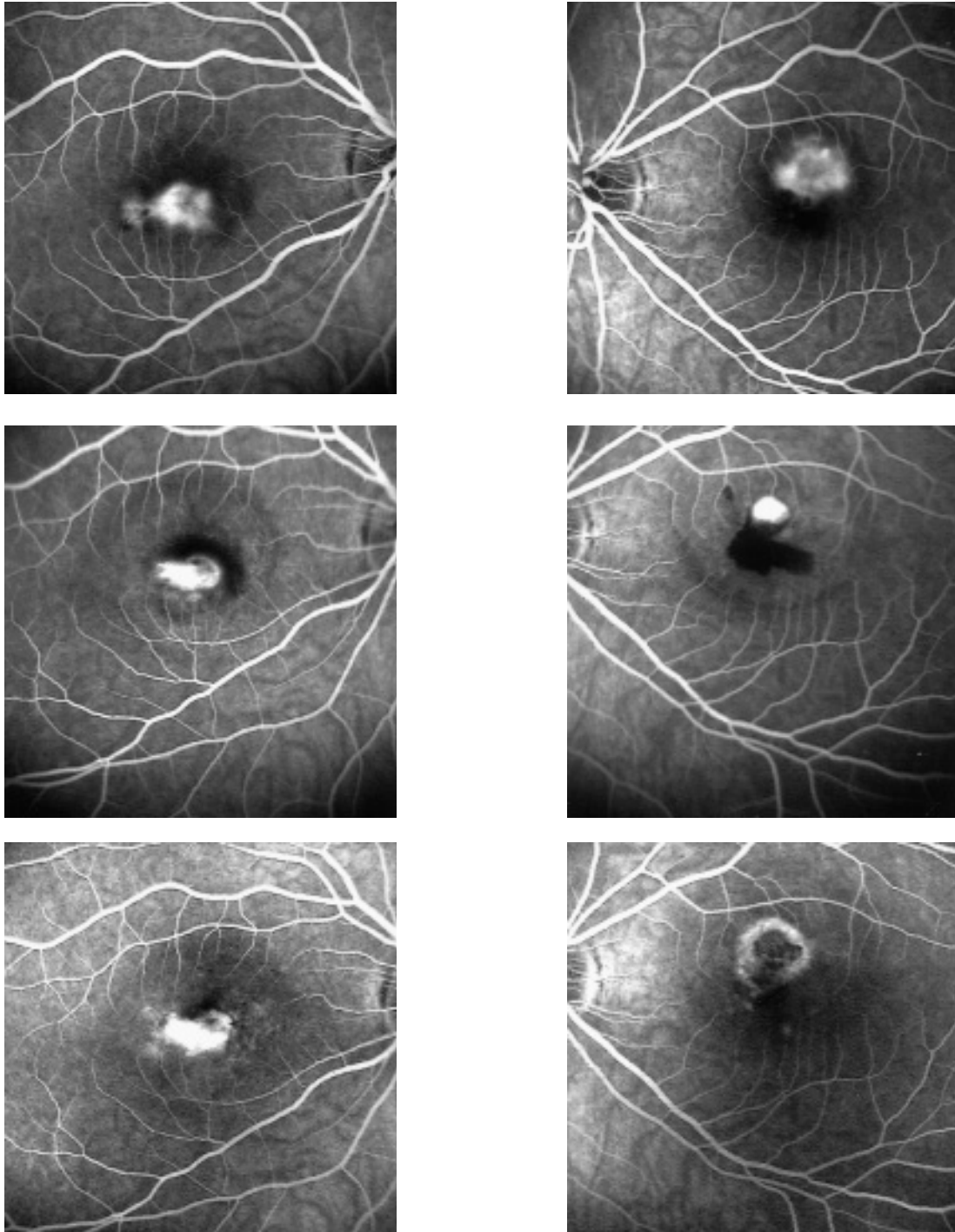


Fig 1 (Case 1):

Top left: Fluorescein angiography of the right eye before photodynamic therapy (PDT): classic subfoveal choroidal neovascularisation (CNV). Top right: Fluorescein angiography of the left eye before PDT: superfoveal CNV encroaching the foveal avascular zone.

Center left: no more CNV activity in right eye one month after PDT. Center right: contraction and retraction of the CNV outside the foveal avascular zone in left eye one month after PDT.

Bottom left: recurrence of CNV in right eye eight months after first PDT. Bottom right: dry laser scar in left eye seven months after conventional laser therapy.

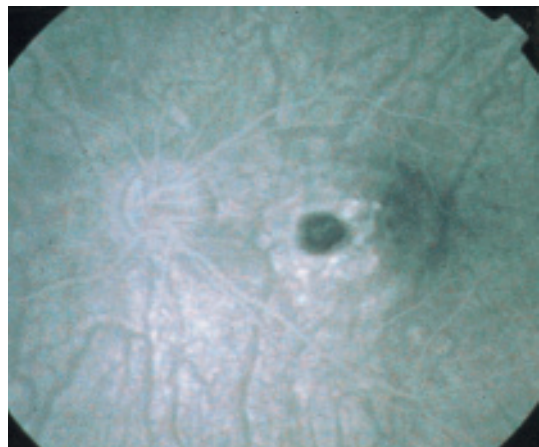
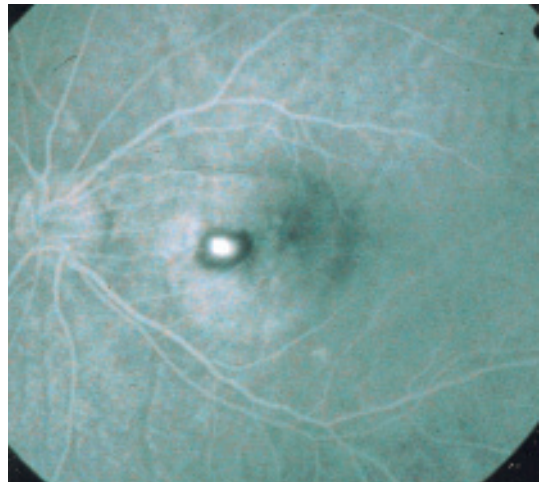
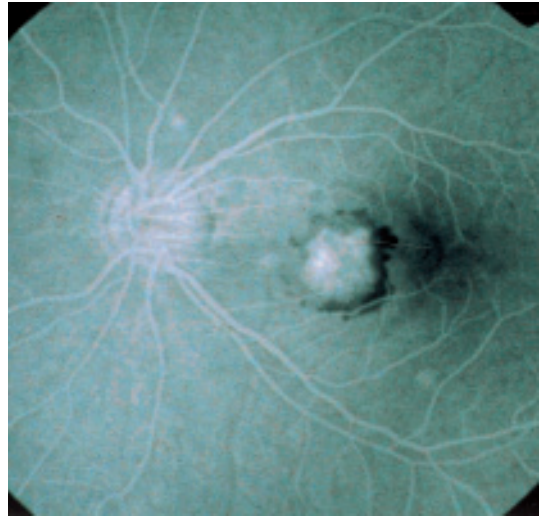
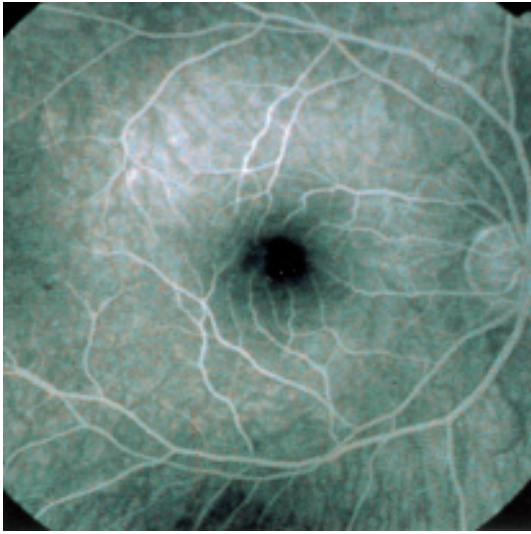


Fig 2 (Case 2):

Top left: fluorescein angiography of the unaffected right eye before photodynamic therapy (PDT). Top right: fluorescein angiography of the left eye before PDT: classic subfoveal choroidal neovascularisation (CNV). Center: contraction and retraction of the CNV outside the foveal avascular zone in left eye one month after PDT. Bottom: no more neovascular activity in left eye eight months after conventional laser therapy.

mosis syndrome, that is a major cause of severe central irreversible visual loss amongst adults living in central and eastern United States. We report three eyes with classic CNV - subfoveal or within the FAZ - secondary to multifocal choroiditis developed in two young mildly myopic women. A treatment using PDT with Verteporfin was performed on all three eyes, this solution being the only way to avoid damages to the foveal functions. In two eyes, the neovascular membrane shrunk and retracted beyond the FAZ. In order to increase the chance to prevent central recurrence with more accuracy, it was decided to perform an additional conventional laser photocoagulation of the CNV. After a follow-up of six months in average, the two eyes treated with laser have a stabilised or even improved visual acuity and neovascular activity has disappeared. In the eye with subfoveal CNV treated with PDT only, no more neovascular activity was noticed during the first six months. A second PDT was performed afterwards, because of a little recurrence of the CNV.

In conclusion, we can say that PDT has been successful on the three treated eyes, with stable or improved visual acuity. Therefore, visual prognosis seems to be better than in the case of natural evolution of CNV involving the fovea in the MC⁽²⁾. In two of the treated eyes, it even made the membrane retract as to become extrafoveal allowing a secondary treatment using conventional laser. These cases show the potential complementarity of PDT and laser photocoagulation in central CNV.

REFERENCES

- (1) BROWN J., FOLK J.C. – Current controversies in the white dot syndromes: multifocal choroiditis, punctate inner choroidopathy, and the diffuse subretinal fibrosis syndrome. *Ocul Immunol Inflamm* 1998; 6: 125-127.
 - (2) BROWN J., JAMES C. – Visual prognosis of multifocal choroiditis, Punctate inner choroidopathy, and the diffuse subretinal fibrosis syndrome. *Ophthalmology* 1996; 103: 1100-1105.
 - (3) DREYER R.F., GASS J.D.M. – Multifocal choroiditis and panuveitis: a syndrome that mimics ocular histoplasmosis. *Arch Ophthalmol* 1984; 102: 1776-1784.
 - (4) FLAXEL C.J., OWENS S.L., MULHOLLAND B. – The use of corticosteroids for choroidal neovascularisation in 10 patients. *Eye* 1998; 12: 266-72.
 - (5) FUJII G.Y., HUMAYNU M.S., PIERAMICI D.J. – Initial experience of inferior limited macular translocation for subfoveal choroidal neovascularisation resulting from causes other than age-related macular degeneration. *Am J Ophthalmol* 2001; 131: 90-100.
 - (6) GASS J.D.M., MARGO C.E., LEVY M.H. – Progressive subretinal fibrosis and blindness in patients with multifocal granulomatous chorioretinitis. *Am J Ophthalmol* 1996; 122: 76-85.
 - (7) LIT E.S., KIM R.Y., DAMICO D.J. – Surgical removal of subfoveal choroidal neovascularisation without removal of posterior hyaloid: a consecutive series in younger patients. *Retina* 2001; 21: 317-23.
 - (8) SHULLER M.F., BORILLO J.L. – Photodynamic therapy update. *Curr Opin Ophthalmol* 2001; 12: 202-206.
 - (9) SICKENBERG M., SCHMIDT-ERFURTH U., MILLER J.W. – A preliminary study of photodynamic therapy using Verteporfin for choroidal neovascularisation in pathologic myopia, ocular histoplasmosis syndrome, angioid streaks, and idiopathic causes. *Arch Ophthalmol* 2000; 118: 327-36.
 - (10) TAP Study Group – Photodynamic therapy of subfoveal choroidal neovascularisation in age-related macular degeneration with Verteporfin. *Arch Ophthalmol* 2001; 119: 198-207.
 - (11) THOMAS J.W., GROSSNIKLAUS H.E., LAMBERT H.M., AABERG T.M., L'HERNAULT N. – Ultrastructural features of surgically excised idiopathic subfoveal neovascular membranes. *Retina* 1993; 13: 93-98.
 - (12) THOMAS M.A., KAPLAN H.J. – Surgical removal of subfoveal neovascularization in the presumed ocular histoplasmosis syndrome. *Am J Ophthalmol* 1991; 111: 1-7.
 - (13) THOMAS M.A., DICKINSON J.D., MELBERG N.S., IBANEZ H.E., DHALIWAL R.S. – Visual results after surgical removal of subfoveal choroidal neovascular membranes. *Ophthalmology* 1994; 101: 1384 - 1396.
 - (14) VEROUGSTRAETE C. – White dot syndromes. *Bull Soc belge Ophthalmol* 2001; 279: 67-78.
-

Correspondence and reprints:
 Pascale COQUELET
 Department of Ophthalmology, CHU Brugmann
 Pl. A. Van Gehuchten, 4
 B - 1020 Brussels