

THE COLLABORATIVE OCULAR MELANOMA STUDY AND MANAGEMENT OF CHOROIDAL MELANOMA

BRADLEY R. STRAATSMA, M.D.**

Baron Jules François was the preeminent ophthalmologist in a generation that included a number of notable colleagues. Throughout his distinguished tenure as Professor and Director of Ophthalmology at the University of Ghent, he combined intellectual and scholarly achievement with extraordinary energy and global vision.

Scientific interests ranging from genetics¹ to glaucoma² culminated in authorship of hundreds of articles, chapters, and books. His boundless energy permitted an intense work ethic at the University of Ghent, leadership as President of the Royal Academy of Medicine of Belgium (1969) and a broad commitment to international ophthalmology.

Central to all activities, Jules François had a vision of ophthalmology as a global community. While President of the International Council of Ophthalmology from 1974 to 1982, he presided over the XXIII International Congress of Ophthalmology in Tokyo, Japan, during 1978 and the XXIV International Congress of Ophthalmology in San Francisco, United States, during 1982. At the Closing Ceremony of the latter, Jules François stated that "friendship has gained as much as science and we have felt close to one another, both in heart and in mind."

.....

* presented at "Ophthalmologia Belgica", Brussels, 24th November 2001.

** From the Jules Stein Eye Institute and Department of Ophthalmology, UCLA School of Medicine, University of California, Los Angeles, California, USA



At the conclusion of his term, grateful colleagues elected Jules François Honorary Life President of the International Council of Ophthalmology.³

In 1975, Jules François initiated formation of the Academia Ophthalmologica Internationalis to encourage interaction among academic ophthalmologists. In recognition, he was accorded the title of Honorary Life President of the Academia Ophthalmologica Internationalis.

Illustrating the global vision of Jules François, in April 2001, the International Council of Ophthalmology and the Academia Ophthalmologica Internationalis, working together, published the International Ophthalmology Strategic Plan to Preserve and Restore Vision - Vision for the Future.⁴ Presented simultaneously in print and full-text on the Internet (www.icoph.org and www.acad-ophthal-int.org), this is a multiyear blueprint for improving eye care throughout the world.

The international leadership of Jules François and his participation in countless ophthalmology meetings in all parts of the world forged friendships that united the profession of ophthalmology. With respect and warm memories of association, it is a distinct honor and a great personal pleasure to present the Jules François Memorial Lecture.

In this presentation, I will focus on the role of randomized clinical trials in determination of evidence-based medical intervention, results of the Collaborative Ocular Melanoma Study, and forward-looking goals of choroidal melanoma research. The first major publication from a large, multicenter randomized clinical trial in ophthalmology was published in the American Journal of Ophthalmology in 1976, exactly 25 years ago. This report by the Diabetic Retinopathy Study Group changed the global standard of care of proliferative diabetic retinopathy.⁵ Since then, randomized clinical trials have influenced the management of nearly every major pathologic condition in ophthalmology, including corneal disease, cataract, glaucoma, endophthalmitis, complications of acquired immunodeficiency syndrome (AIDS), retinopathy of prematurity, retinal vein occlusion, age-related macular degeneration, and choroidal melanoma.⁶

In the quest for evidence-based medical intervention, a clinical trial may be appropriate when (1) the disease to be studied is a substantial public health concern, (2) there is preliminary evidence that a "new" test treatment may be superior to the current "standard" treatment, (3) a valid trial outcome may be obtained in a reasonable time, and (4) ethical patient protection is in place. When these conditions are met, it is more ethical to conduct a clinical trial than to pursue either the "new" test treatment or the "standard" treatment on the basis of the incomplete or inconclusive evidence. Properly designed, a randomized clinical trial can control for bias or unascertained factors by randomization, reduce the variability in patient outcome by a suitable sample size, and protect the participating patients by appropriate ethical safeguards.⁶

Results of clinical trials are central to evidence-based medical intervention. However, results are often published over several years in numerous articles that appear in multiple jour-

nals. Computerized search engines such as Medline may not assemble information from an ongoing or completed clinical trial. Recognizing this, the American Journal of Ophthalmology inaugurated the Clinical Trials Digest as an Internet feature available to all viewers at www.ajo.com in October 2001.⁷ This Digest is designed to include ongoing and completed trials that evaluate the effect of treatment (drug, procedure, device, or regimen) in ophthalmic patients. For each listed trial, the Digest presents the trial design, names of participating centers, and a list of all publications from the trial by title, date, and authorship. An electronic link permits the viewer to click on the title of any publication and immediately review the abstract of the article. This electronic information resource will enable ophthalmologists to locate evidence-based information, alert physicians to new treatment opportunities for their patients, and foster collaborations within the global research community.

Illustrating a randomized clinical trial, the Collaborative Ocular Melanoma Study (COMS), in progress since 1985, is sponsored by the National Eye Institute and National Cancer Institute. The COMS is Chaired by Stuart L. Fine, M.D.; John D. Earle, M.D. (radiation oncologist), and Bradley R. Straatsma, M.D., are Co-Chairs; Barbara S. Hawkins, Ph.D., directs the Coordinating Center; and Natalie Kurinij, Ph.D., represents the National Eye Institute. This study is being conducted at 43 clinical centers in the United States and Canada.

During 2001, the COMS Randomized Trial of Iodine 125 Brachytherapy for Choroidal Melanoma presented results in three publications: characteristics of patients enrolled and not enrolled⁸, initial mortality findings⁹, and visual acuity three years after brachytherapy¹⁰. To assess the extent to which findings of the trial can be generalized to future patients, one report considered the characteristics of patients enrolled and not enrolled. At the 43 COMS Clinical Centers, 8,712 choroidal melanoma patients were screened between February 1987 and completion of accrual in July 1998, 5,046 had melanoma of eligible size, 2,882 fulfilled all eligibility criteria, and 1,317 enrolled in the trial.⁸ Enrolled patients had choroidal melanoma from 2.5 mm to 10.0 mm in apical height, no more than 16 mm in longest basal diame-

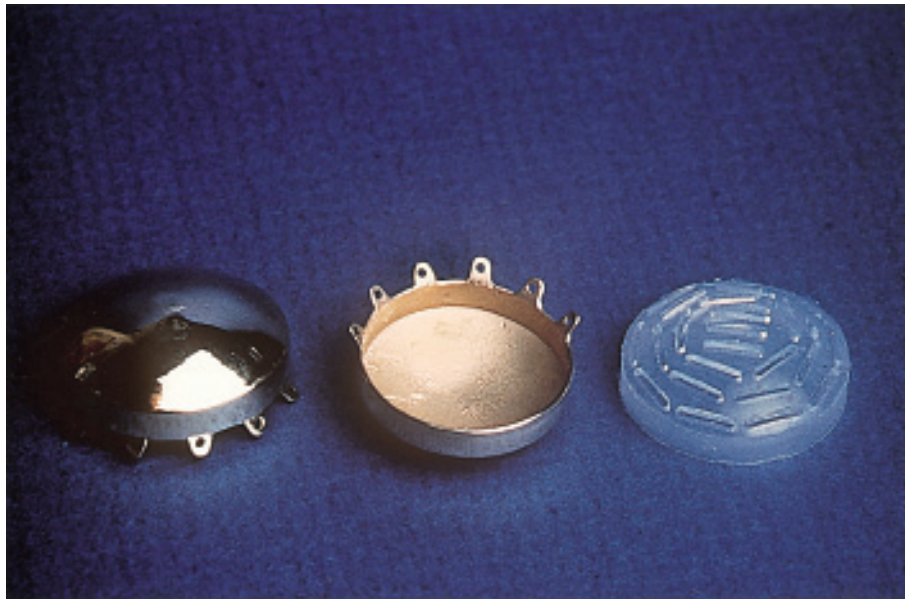

Fig 1. Standardized gold plaque with insert for I-125 seeds and eyelets for fixation sutures.

ter, and with exceptions, a proximal border 2 mm or more from the optic disk. Eligible patients were adults, free of clinically detectable melanoma metastasis and with no history of other primary cancer.

Approximately half (1,371 (46%) of 2,882) of the eligible patients enrolled. Baseline demographic characteristics and tumor characteristics of enrolled and not-enrolled patients were well-balanced for all factors judged to be important in determining outcome. Thus, results of enrolled patients may be generalized to include eligible but not-enrolled patients.

A further question is whether the enrolled patients are broadly representative of patients who would be candidates for treatment with I-125 brachytherapy. Based on a choroidal melanoma incidence of six to eight new cases per million population per year and a 280 million population in the United States and Canada, there were about 19,320 to 25,760 new cases of choroidal melanoma during the 11.5 years of COMS patient accrual. The 8,718 patients screened at COMS Centers were 34% to 45% of all new cases during that time. Moreover, COMS patients were compared with patients in other published studies of I-125 brachytherapy. There is considerable variability among stud-

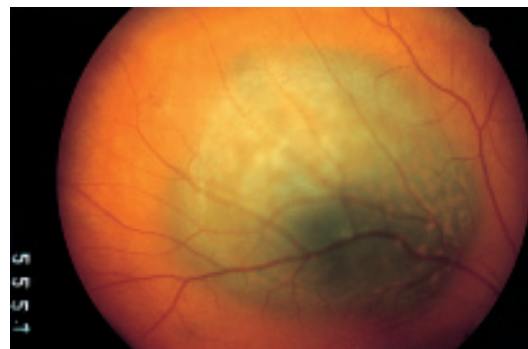


Fig 2. 62-year-old man. Medium choroidal melanoma, right eye, with basal diameters of 9 mm and 10 mm and apical thickness of 3.8 mm prior to brachytherapy. Visual acuity: 20/25.

ies, but COMS patients were consistently within the parameters of patients in other studies. The COMS has high internal validity by design and by comparison of enrolled and not-enrolled patients. The COMS has high external validity based on the proportion of melanoma cases screened at COMS Centers and comparison of COMS patients with published reports. We may conclude that results of the COMS randomized trial are generalizable to future patients who meet COMS eligibility criteria.

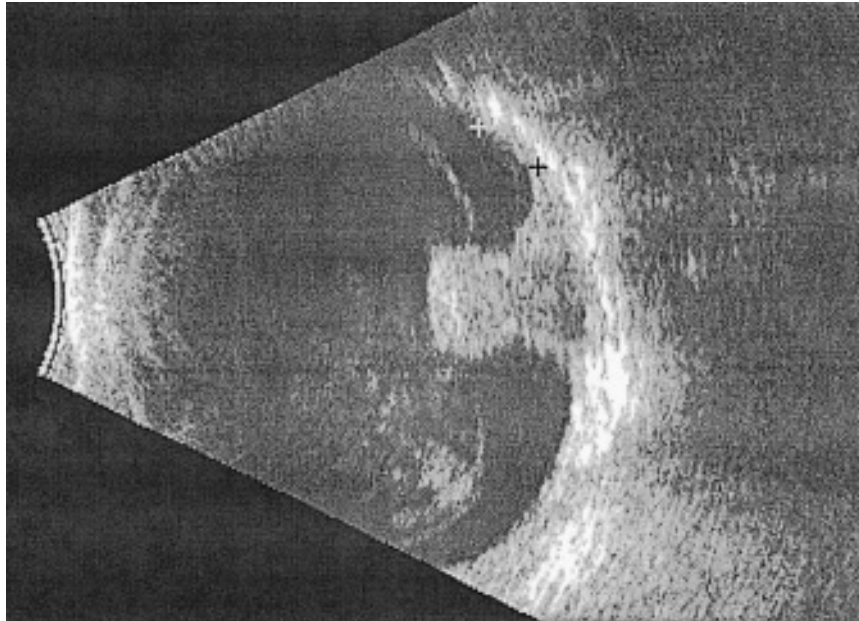


Fig 3. Intraoperative ultrasonography confirms that the I-125 plaque extends 3 mm beyond the border of the melanoma at 90° intervals around the circumference. Cursors identify tumor border and plaque edge. 85-year-old man with collar-button shape melanoma measuring 10 mm x 10 mm x 6.3 mm.

In the randomized trial of I-125 brachytherapy, 1,317 patients were enrolled; 660 were assigned randomly to enucleation, and 657 to I-125 brachytherapy.⁹ When histopathology was reviewed centrally, 658 (99.7%) of 660 eyes had choroidal melanoma and 2 eyes had carcinoma metastatic to the choroid. The I-125 brachytherapy protocol provided a dose of 85 Gy at the tumor apex or 5 mm from the interior surface of the sclera for tumors with apical height of less than 5 mm. The protocol utilized standard gold plaques that provided a 2 to 3 mm margin of treatment beyond the tumor border (Figure 1).

The I-125 plaque placement procedure may be illustrated by a typical case (Figure 2). Briefly, under monitored local anesthesia with intravenous sedation or general anesthesia, a conjunctival peritomy was performed and sutures were looped around the rectus muscle insertions. The melanoma was localized by transillumination and ophthalmoscopy, and the sclera was marked to position the central meridian of the melanoma and identify the placement of each fixation suture. With the plaque in place and slip knots on the fixation sutures, plaque placement was confirmed by intraoperative ultrasonography to

assure a 3 mm margin of treatment beyond the tumor at 90° intervals around the circumference of the melanoma (Figure 3). After confirmation of plaque placement, fixation sutures were tied and conjunctiva was repositioned to the limbus.

Based on time of enrollment, 1,072 (81%) of the patients have been followed after treatment for 5 years and 416 (32%) for 10 years; 364 patients have died. The unadjusted estimated 5-year survival rates were 81% for enucleation and 82% for brachytherapy; there was no statistical difference in survival rates ($P = .48$). Among COMS patients, survival rates following enucleation and brachytherapy did not differ for up to 12 years after treatment.

In subanalyses and assessment by pathologists, younger age and shorter longest basal diameter of the tumor were significantly associated with longer survival. Five year rate of death with histologically confirmed melanoma metastasis was approximately 10%, with no statistically significant difference between enucleation and brachytherapy.

Important visual acuity data were reported for 623 eyes treated with I-125 brachytherapy and followed for at least one year.¹⁰ At baseline be-

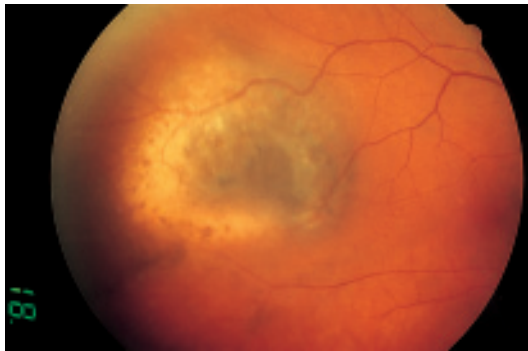


Fig 4. Prior to I-125 brachytherapy. 77-year-old woman with medium choroidal melanoma, right eye, measuring 8 mm × 11 mm × 4 mm. Proximal edge of the tumor is 4 mm from the foveola. Visual acuity: 20/20.

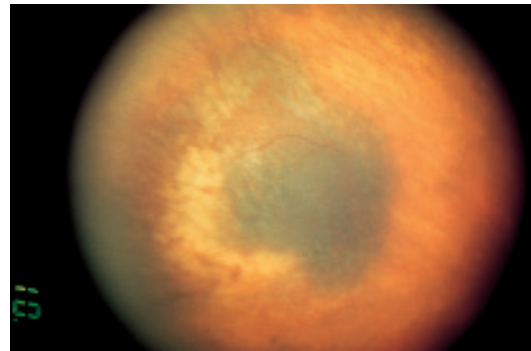


Fig 5. One year after I-125 brachytherapy. Same patient as in Figure 4. Decrease in apical thickness of melanoma. Visual acuity: 20/25.

fore treatment, median protocol visual acuity in the eye with melanoma was 20/32; 70% of eyes had 20/40 or better, and 10% of eyes had 20/200 or worse. Three years after I-125 brachytherapy, median visual acuity was 20/125; 34% of eyes had 20/40 or better and 45% of eyes had 20/200 or worse; the latter included eyes that were enucleated. Life-table estimates of patients who lost six or more lines of visual acuity (a quadrupling of the minimum angle of resolution) from baseline were 18% by 1 year, 34% by 2 years, and 49% by 3 years after treatment. Overall, about half of treated eyes had substantial impairment of visual acuity 3 years after I-125 brachytherapy, defined as loss of six or more lines of acuity (49% of eyes) or 20/200 or worse (45% of eyes).

Impairment of visual acuity after brachytherapy is illustrated in an eye with juxtafoveal melanoma and baseline visual acuity of 20/20 (Figure 4). One year after brachytherapy, the tumor is decreased in thickness and visual acuity is 20/25 (Figure 5). Seven years after brachytherapy, the tumor shows further decrease in thickness, but the peritumor radiation-associated retinopathy and choroidopathy are greater and visual acuity is Count Fingers at 1 foot (Figure 6).

Radiation retinopathy and radiation optic neuropathy are well-recognized consequences of radiation therapy. Radiation choroidopathy is less fully appreciated. Following I-125 brachytherapy, there is a progressive decrease in vascular perfusion of the choroidal melanoma. In addition, during the 2 years after brachytherapy,

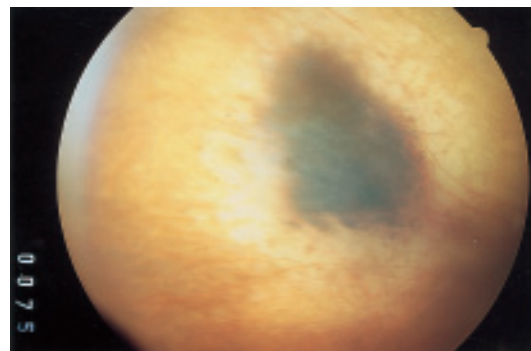


Fig 6. Seven years after I-125 brachytherapy. Same patient as in Figure 4. Further decrease in melanoma thickness, extensive peritumor radiation-associated retinopathy and choroidopathy. No evidence of melanoma metastasis. Visual acuity: Count Fingers at one foot.

there is a general choroidal vasculopathy consisting of choriocapillaris nonperfusion, attenuation and closure of small choroidal vessels, and fluorescein staining of residual choroidal vessels. Late choroidal vasculopathy, usually more than 2 years after brachytherapy, includes closure of large choroidal vessels, extensive retinal pigment epithelial atrophy, paving stone degeneration, and remodeling of the choroidal circulation.¹¹

In broader context, survival results of the I-125 brachytherapy trial should be compared with the COMS trial of pre-enucleation radiation of large choroidal melanoma.^{12, 13, 14} In the pre-enucleation trial for large melanoma, tumors were greater than 10 mm in apical height or greater than 16 mm in longest basal diameter;

there was no statistically significant difference between enucleation with or without pre-enucleation radiation, and 5-year survival was 57 - 62%. In contrast, the brachytherapy trial of medium choroidal melanoma included tumors 2.5 mm to 10 mm in apical height and less than 16 mm in longest basal diameter; there was no difference between enucleation or brachytherapy, and 5-year survival was 81 - 82%. These results emphasize two forward-looking melanoma research goals. First, how does radiation therapy affect melanoma cells? Some effect may be from the attenuation and closure of blood vessels. However, recent research by Brantley, Worley, and Harbour¹⁵, reported in an article currently in press in the American Journal of Ophthalmology and described with the authors' permission, suggests that radiation induces "reproductive cell death." Although the molecular mechanisms of reproductive cell death are incompletely understood, most evidence indicates that it results from irreparable damage to the DNA of the cell. In 3 eyes enucleated for neovascular glaucoma or periocular pain 2 to 26 months after I-125 brachytherapy and satisfactory tumor response, melanoma cells could be established in culture. Nonetheless, the irradiated melanoma cells had flattened cell bodies, minimal capacity to divide, and increased cell death compared to non-irradiated melanoma cells that were plump, divided rapidly, and formed colonies. For example, in one irradiated eye, estimated tumor doubling time in culture was 375 days with few cells surviving three passages, while non-irradiated melanoma cells had a doubling time of 11 days in culture and continued to grow indefinitely. We must continue to study the molecular mechanisms of radiation and the process of reproductive cell death to develop new therapies that are increasingly effective and associated with fewer adverse side effects.

Second, how can we improve survival of patients with choroidal melanoma? Certainly, patients with medium choroidal melanoma have a better prognosis than patients with large melanoma. However, some medium melanoma patients who screen negative for melanoma metastasis at the time of brachytherapy or enucleation develop metastatic melanoma. This probably relates to early onset of melanoma metastasis. In a study of 70 patients by Eske-

lin and co-authors¹⁶, tumor doubling time of uveal melanoma metastases ranged from 34 to 220 days, with two-thirds between 30 and 80 days, and a median of 63 days. Assuming a constant growth rate, some melanoma metastasis, had initiated as much as 5 years prior to primary melanoma treatment. This strengthens the argument for early treatment, but also indicates the best hope for improving survival is to combine primary treatment of the choroidal melanoma with adjuvant systemic therapy to combat micrometastases. Currently in progress are studies of melanoma antigen by Ericsson and co-authors¹⁸, investigations of "tumor killer cells" and randomized clinical trials of Allovectin-7 (a gene therapy product which contains the gene for HLA-B7) immunotherapy for metastatic disease. To date, however, no adjuvant immunotherapy or chemotherapy has been documented as effective.

In summary, a quarter century after the first publication from the Diabetic Retinopathy Study, randomized clinical trials have influenced nearly every major pathologic condition in ophthalmology. In 2001, the Collaborative Ocular Melanoma Study trial of I-125 brachytherapy has demonstrated that there is no statistically significant difference in survival after enucleation or I-125 brachytherapy. Three years after brachytherapy, approximately half of treated eyes had substantial impairment of visual acuity. Five-year survival after the I-125 brachytherapy trial for medium melanoma was 81 - 82% but after the pre-enucleation trial for large melanoma, 5-year survival was 57 - 62%. To improve local tumor control, the molecular mechanisms of radiation-induced reproductive cell death warrant study. To improve survival, the best hope is to combine primary treatment of choroidal melanoma with adjuvant systemic therapy for micrometastasis.

REFERENCES

- (1) FRANÇOIS J. – Genetic aspects of Ophthalmology. Ed. Little and Brown, Boston, 1968.
- (2) FRANÇOIS J., KLUYSKENS J. – Le Glaucome Congénital. Ed. Imprimerie Médicale et Scientifique, Brussels, 1950.
- (3) FRANÇOIS J. – ACTA: XXIV International Congress of Ophthalmology, 1982; 1: CLV-CLVi. J. B. Lippincott, Philadelphia.

- (4) International Council of Ophthalmology and Academia Ophthalmologica Internationalis. International Ophthalmology Strategic Plan to Preserve and Restore Vision - Vision for the Future. Los Angeles, CA: 2001.
- (5) Diabetic Retinopathy Study Research Group. Preliminary report on effects of photocoagulation therapy. *Am J Ophthalmol*, 1976; 81(4): 383-396.
- (6) BRESSLER S.B., BRESSLER N.M. – Randomized Clinical Trials in Ophthalmology in 2001: Twenty-fifth anniversary of the first publication from the Diabetic Retinopathy Study. *Am J Ophthalmol* 2000; 129(4): 503-504.
- (7) BRESSLER S.B., DIENER-WEST M., TAYLOR H.R., STRAATSMA B.R. – Clinical Trials Digest on the Internet at AJO.COM: Entering a new information age. *Am J Ophthalmol*, 2001; 132(4): 566-567.
- (8) Collaborative Ocular Melanoma Study Group. The COMS randomized trial of iodine 125 brachytherapy for choroidal melanoma, II: Characteristics of patients enrolled and not enrolled: COMS report No. 17. *Arch Ophthalmol* 2001; 119(7): 951-965.
- (9) Collaborative Ocular Melanoma Study Group. The COMS randomized trial of iodine 125 brachytherapy for choroidal melanoma, III: Initial mortality findings: COMS report No. 18. *Arch Ophthalmol* 2001; 119(7): 969-982.
- (10) Collaborative Ocular Melanoma Study Ocular Melanoma Study Group. The COMS randomized trial of iodine 125 brachytherapy for medium choroidal melanoma, I: Visual acuity after 3 years: COMS report No. 16. *Ophthalmology* 2001; 108(2): 348-366.
- (11) SCHALTTER U.C., MUELLER A.J., BARTSCH D.U., FREEMAN W.R., KAMPIK A. – Choroidal melanoma microcirculation with confocal indocyanine green angiography before and one year after radiation brachytherapy. *Retina* 2000; 20(6): 627-32.
- (12) Collaborative Ocular Melanoma Study Group. Histopathologic characteristics of uveal melanomas in eyes enucleated from the Collaborative Ocular Melanoma Study: COMS report No. 6. *Am J Ophthalmol* 1998; 125(6): 745-766.
- (13) Collaborative Ocular Melanoma Study Group. The Collaborative Ocular Melanoma Study (COMS) randomized trial of pre-enucleation radiation of large choroidal melanoma, I: Characteristics of patients enrolled and not enrolled. COMS report No. 9. *Am J Ophthalmol* 1998; 125(6): 767-778.
- (14) Collaborative Ocular Melanoma Study Group. The Collaborative Ocular Melanoma Study (COMS) randomized trial of pre-enucleation radiation of large choroidal melanoma, II: Initial mortality findings: COMS report No. 10. *Am J Ophthalmol* 1998; 125(6): 779-796.
- (15) BRANTLEY M., WORLEY L., HARBOUR J.W. – Altered expression of Rb and p53 in uveal melanomas following plaque radiotherapy. *Am J Ophthalmol* (in press).
- (16) ESKLIN S., PHYHONEN S., SUMMANEN P., HAHKA-KEMPPINEN M., KIVELÄ T. – Tumor doubling times in metastatic malignant melanoma of the uvea. *Ophthalmology* 2000; 107(8): 1443-1449.