

IMPROVEMENT OF ACQUIRED PENDULAR NYSTAGMUS BY GABAPENTIN: CASE REPORT

FABRE K. *, SMET - DIELEMAN H. **, ZEYEN T.***

SUMMARY

Acquired Pendular Nystagmus (APN) may cause distressing visual symptoms in patients who are already suffering a severe general disease. Averbuch-Heller et al. conducted the first double-blind controlled study on treatment for APN. They showed that gabapentin substantially reduces pendular nystagmus and significantly increases visual acuity in the majority of patients. We present a patient with APN due to multiple sclerosis who suffered severe oscillopsia and reduction of visual acuity and who substantially benefited from a trial treatment with this agent.

SAMENVATTING

Verworven Pendulaire Nystagmus (APN) kan zeer storende visuele symptomen veroorzaken bij patiënten die meestal reeds tengevolge van de onderliggende aandoening een slechte algemene toestand hebben. Averbuch-Heller et al. waren de eersten om een dubbelblind gecontroleerde studie uit te voeren over een behandeling voor APN. Zij toonden aan dat gabapentin de nystagmus substantieel vermindert en de visus significant verbetert in de meerderheid van de patiënten. We stellen een patiënt voor met APN tengevolge van multiple sclerose, die een duidelijke vermindering van de oscillopsie en een verbetering van de visus ondervond tijdens een proefbehandeling met gabapentin.

.....

* Dienst Oogheelkunde, A.Z. Middelheim, Antwerpen
** Dienst Oogheelkunde, U.Z. Antwerpen
*** Dienst Oogheelkunde, U.Z. St. Rafaël, Leuven

received: 13.04.01
accepted: 05.09.01

RÉSUMÉ

Le nystagmus pendulaire acquis (NPA) peut causer des symptômes visuels très inconfortables chez des patients qui souffrent déjà d'une affection sous-jacente grave. Averbuch-Heller et al. furent les premiers à effectuer une étude contrôlée en double aveugle concernant le traitement du NPA. Ils ont montré que le gabapentin diminue le nystagmus de façon appréciable et améliore l'acuité visuelle dans la majorité des cas. Nous présentons un patient, avec un NPA suite à une sclérose en plaques, qui a également bénéficié de ce traitement.

KEY-WORDS

Gabapentin, Nystagmus

MOTS-CLÉS

Gabapentin, Nystagmus

INTRODUCTION

Various conditions affecting the brainstem and cerebellum, such as vascular diseases (e.g. brainstem stroke), demyelinating diseases (e.g. multiple sclerosis) and degenerative disorders (e.g. spinocerebellar degeneration) may cause acquired nystagmus (1).

Acquired nystagmus can be very disabling for vision, especially when it causes oscillopsya, an illusionary motion of the stationary environment.

Acquired pendular nystagmus (APN) is characterized by a smooth sinusoidal movement. Little is known about its pathogenesis. Until now most treatments for APN have been empirical and were based on individual case reports.

Recent experimental evidence suggests that drugs with gabaergic activity may have an effect on nystagmus. Averbuch-Heller conducted a double-blind controlled study of the effect of two gabaergic drugs, baclofen and gabapentin, on acquired nystagmus both of the pendular and jerk type (3).

In the light of this study we present the following case.

CASE REPORT

A 50 year old female, diagnosed with multiple sclerosis in 1978, became progressively wheelchair bound due to quadriplegia. Since 1991 she presents a mixed pendular nystagmus and complains of progressively more disabling oscillopsya. In order to improve her visual and overall comfort she was given a trial treatment with baclofen first, and gabapentin thereafter.

Before treatment her binocular visual acuity on the Snellen chart was 0.3 at distance and Snellen 7 nearby.

She was first started on baclofen 10 mg three times daily. Because she didn't experience any subjective improvement and suffered from nausea and asthenia, she stopped the treatment spontaneously after one month.

One week later she was started on a trial treatment with oral gabapentin at a single morning dose of 400 mg.

A video recording and oculonystagmographic recording were made before and during treatment with gabapentin. Her visual acuity im-

proved to 0.4 at distance and to Snellen 3 nearby. The nystagmus was clinically substantially reduced. This reflected in an important subjective reduction of the oscillopsya, confirmed on oculonystagmography (Fig. 1). The patient did mention a worsening of imbalance, but the gain of visual comfort outweighed this side effect and she elected to continue the treatment. One year later she is still benefiting from the treatment at a dose of 300 mg taken in the morning.

DISCUSSION

APN is one of the most distressing oculomotor symptoms in multiple sclerosis and, besides blurred vision, often causes oscillopsya that interferes with the ability reading or watching television and even to stabilize posture visually. Patients with MS can present with a nystagmus that is vertical, horizontal or mixed, i.e. with a circular, elliptical or diagonal trajectory (6).

In view of the uncertain pathophysiology and the absence of an animal model, it is not surprising that current therapeutic approaches are mostly based on single-case observations. Previous treatments have included anticholinergic agents (trihexyphenidyl, scopolamine, benzotropine), potassium and/or sodium-channel blocking agents, local administration of botulinum toxin, the use of base-out prisms and even eye muscle surgery (1,5,6). None of these treatments seem to be effective in all patients with APN and some are of limited usefulness because of their short-term effect, side effects or mode of application.

Experimental studies indicated the role of gamma-aminobutyric acid (GABA) in the normal mechanism by which gaze is held steady and this incited Averbuch-Heller et al. to test GABAergic drugs in cases of nystagmus. A pilot study identified gabapentin, an anticonvulsive drug used as add-on therapy in refractory epilepsy, as potential therapy for APN (7). In three patients with APN as soon as two hours following the administration of a single oral dose of 600 mg of gabapentin, the visual acuity improved by a factor of two or more and was associated with a reduction or abolition of the nystagmus (2).

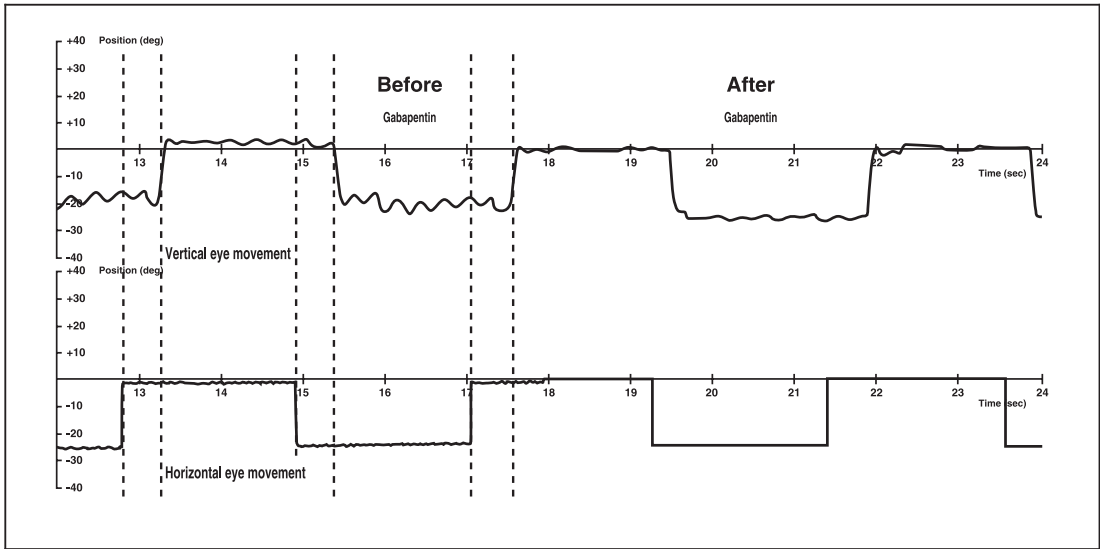


Fig. 1: Oculonystagmography before and after Gabapentin

In a double-blind controlled study the effect of this agent was then studied and compared to baclofen, another GABAergic drug. In this important study of 15 patients with APN, visual acuity increased significantly with gabapentin but not with baclofen while gabapentin reduced all components of the nystagmus. In ten patients the reduction of oscillations was substantial and in two patients nystagmus was completely abolished (3). It is important to notice that this study has also shown that gabapentin is not effective in the treatment of jerk nystagmus.

Our case report confirms the findings of Averbuch-Heller et al. about the effectiveness of gabapentin in relieving ocular symptoms caused by APN.

Gabapentin (Neurontin®, 1-(aminomethyl)-cyclohexanecarboxylic acid), an anti-epileptic agent used since 1992, has been shown to be effective and well tolerated as add-on therapy in patients with epilepsy refractory to standard anti-epileptic treatment (8). The exact mechanism is not yet understood. Although structurally similar to GABA, gabapentin shows no direct activity on common gaba a and gaba b receptors or uptake carriers. However, there is strong evi-

dence that gabapentin influences the metabolism and release of GABA (3).

The recommended dose of gabapentin as treatment for APN is unknown until now. It is generally recommended to titrate the dose until the lowest effective dose with minimal side effects is reached. In Averbuch-Heller's study a dose of 3x300 mg per day was used, starting with 300 mg and increasing with 300 mg every 3 days. Two patients could only tolerate 600 mg due to worsening of imbalance. Our patient had a good result with a single daily dose of 400 mg tapered to 300 mg daily after three months. As an anti-epileptic gabapentin is used in doses of 900 to 1800 mg per day, but doses up to 2400 mg have been well tolerated in clinical trials.

The only side effect mentioned at doses used for APN is worsening of ataxia. Eight patients with APN in the Averbuch-Heller study opted to continue taking the drug and were still benefiting from it when contacted up to 6 months later. Presently there has not been a formal evaluation of the long-term effectiveness of gabapentin in the treatment of APN.

Gabapentin is available in Belgium since December 1999 as Neurontin® (capsules of 300 and 400 mg).

The Averbuch-Heller double-blind study showed that gabapentin is superior to other agents that have been previously reported to help individual patients with APN. Recent reports mention that memantine, a glutamate agonist, is also effective in APN (1).

Starck et al. studied the effect of memantine on APN due to multiple sclerosis. They observed a complete cessation of nystagmus in all patients (7).

It would be interesting to compare the effect of memantine and gabapentin in future studies (4,7).

Drugs that seem to be effective as treatment for APN generally also influence cholinergic and glutaminergic or GABAergic transmission (6).

CONCLUSION

Our case report confirms the findings of Averbuch-Heller et al. that gabapentin is a useful drug for the treatment of acquired pendular nystagmus.

REFERENCES

- (1) AVERBUCH-HELLER L., LEIGH R.J. – Medical treatments for abnormal eye movements: pharmacological, optical and immunological. *Austr New Zealand J Ophthalmol* 1997,25: 7-13
- (2) AVERBUCH-HELLER L., STAHL J.S., ROTTACH K., LEIGH R.J. – Gabapentin as treatment for nystagmus. *Ann Neurol* 1995, 38: 972

- (3) AVERBUCH-HELLER L., TUSA J., FUHRY L., ROTTACH K., GANSER G., HEIDE W., BUTTNER U., LEIGH R. – A double-blind controlled study of Gabapentin and Baclofen as treatment for acquired nystagmus. *Ann Neurol*, 1997, 41: 818-825
- (4) GOTTLÖB I. – Nystagmus. *Curr Opin Ophthalmol*, 1998, 9: 32-38
- (5) LEIGH R.J., AVERBUCH-HELLER I., TOMASK R., REMLER B., YANIGLOS S., DELL'OSSO L. – Treatment of abnormal eye movements that impair vision: strategies based on current concepts of physiology and pharmacology. *Ann Neurol*, 1994, 36: 129-141.
- (6) STAHL J.S., ROTTACH K.G., AVERBUCH-HELLER L., VON MAYDELL R.D., COLLINS S.D., LEIGH R.J. – A pilot study of gabapentin as treatment for acquired nystagmus. *Neuro-Ophthalmol* 1996, 16: 107-113
- (7) STARCK M., ALBRECHT H., POLLMAN W., STRAUBE A., DIETERICH M. – Drug therapy for acquired pendular nystagmus in multiple sclerosis. *J Neurol* 1997, 244:9-16
- (8) The US gabapentin Study group: The long-term safety and efficacy of gabapentin (Neurontin®) as add-on therapy in drug resistant partial epilepsy. *Epilepsy Research* 1994, 18: 67-73.

.....

*T. Zeyen
University Hospital St. Raphaël,
Dept. of Ophthalmology,
Kapucijnenvoer 33,
B-3000 Leuven, Belgium*