

CATARACT WITH MULTIFOCAL AMO ARRAY IMPLANTS

HENRY J-M. *, GARIN PH. **

RÉSUMÉ

Nous avons effectué une étude rétrospective sur trois cent interventions de cataracte effectuées en un an avec pose d'un implant multifoyer AMO ARRAY à vision centrale prédominante de loin. A condition d'effectuer une sélection préopératoire et d'obtenir une quasi emmétropie postopératoire, 80% des patients en postopératoire gagnent la multifocalité sans verres correcteurs.

SUMMARY

We have conducted a retrospective study on three hundred cataract surgeries over one year with insertion of the AMO ARRAY multifocal implant dominant for far vision. Under condition of presurgical selection and postsurgery emmetropia, 80% of patients gains multifocality without glasses.

MOTS-CLÉS

Cataracte, Multifocalité, Implant Intra-oculaire Amo Array.

KEY-WORDS

Cataract, Multifocality, Amo Array Intraocular Lens.

.....

* CH André Vésale, Montigny le Tilleul

** Hôpital St Joseph, Gilly

received: 13.02.01

accepted: 04.09.01

Since Ridley, the gold standard for cataract extraction has been lens extraction and replacement by a monofocal implant.

Cataract extraction developed along the time from intra- to extracapsular initially and phakoemulsification later. Small incisions improved the technique.

But there is still one problem: how to see both at far and near distance after surgery. For bilateral cataracts, one solution is to choose one eye for far distance and the other one for near vision, the strategy called "monovision". The disadvantage of this technique is loss of stereopsis. The ideal solution would be to have an accommodative lens.

Waiting for that modality, an other option is to choose a multifocal IOL optic allowing distance vision and lower spectacle dependence for near vision.

Different bifocal or multifocal implants make this possible (2,5).

Low contrast acuity, complaint of halos and glare have been reported with these lenses.(8) Comparing the 3M diffractive (834LE/815LE) lens, the lolab two zone refractive bifocal(6840M) lens, and the AMO ARRAY, Per-

cival and Setty (5) found that the zonal-progressive refractive IOI AMO ARRAY had the lowest incidence of optical symptoms, with respectively 4,2%(AMO ARRAY), 29,8%(3M), 15%(lolab) of subjects complaining of blur and ghosting.

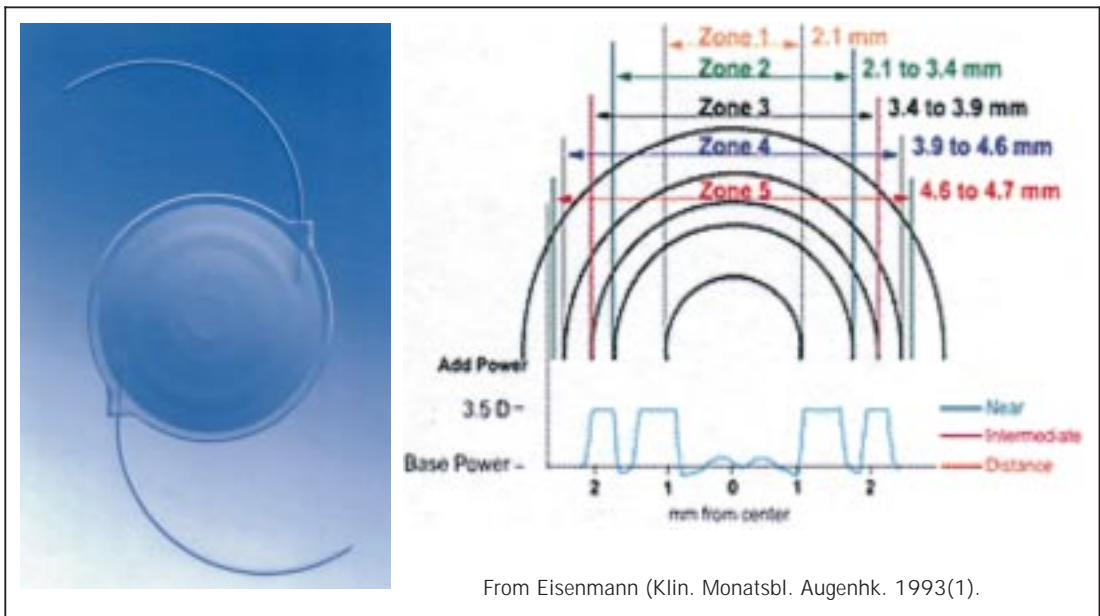
The foldable AMO ARRAY lens (Allergan, Irvine CA) has a series of concentric rings on the front surface with less abrupt transition zones, which can potentially lower glare and halos (fig 1) (1).

The first central zone (2.1 mm in diameter) is designed for distance vision, while the second one (2.1 - 3.4 mm in diameter) is for near vision.

The third one (3.4 - 3.9 mm in diameter) is distance dominant at distance, the fourth one (3.9 to 4.6 in diameter) is also for near vision, and finally the last fifth zone is a transition (4.6 - 4.7 in diameter) zone.

The addition for near vision is 3.5 diopter.

The Array light distribution is divided in 3 parts for pupils larger than 2.0 mm: 50 % for far vision, 13 % for intermediate vision and 37 % for near vision.



From Eisenmann (Klin. Monatsbl. Augenhk. 1993(1)).

Fig 1. Optics of the ARRAY°

This zonal progressive multifocal implant was assessed by several American surgeons comparing monofocal and multifocal implants (4-6).

The objective of our study was to enhance the safety and efficiency of the ARRAY multifocal in our practice. Indications and contraindications before and during surgery, incidence of astigmatism on results, complications and contrast sensitivity studies are described.

MATERIAL AND METHODS

Cataract surgeries were performed over 1 year by Dr J.M. Henry at CH Vésale (Charleroi) and Dr Ph. Garin in St Joseph Hospital (Gilly).

One surgeon (JMH) uses topical anesthesia: 1 hour before surgery 1 drop of Tropicol® and 1 drop of an AINS, followed 10 min before surgery by 3 drops of oxybrufocaine.

During the surgery, 0.1 to 0.2 ml of Lidocaine are instilled intracamerularly if the patient complains at the moment of hydrodissection (10% of cases).

The other surgeon (PhG) uses a classical retrobulbar anaesthesia.

Before performing the corneal procedure, we use a corneal limbic incision for astigmatism in the steep meridian. The size of this incision depends on the astigmatism power.

The cornea is incised with a diamond knife at 10 o'clock or in a temporal position depending of the preop astigmatism. The size of this incision is 3 or 3.2 mm.

A viscoelastic substance is injected into the anterior chamber to allow capsulorexhis with a 21G needle and an Utrata forceps. The ideal capsulorexhis size is 4.5 mm.

The phakoemulsification technique with the Diplomax machine (Allergan) is aspiration or "divide and conquer" for a soft nucleus, chop for a harder nucleus.

Irrigation aspiration is a very important moment with special care for capsular bag cleaning.

At the end of the surgery the implant, either the mono SI40 or the ARRAY multifocal, is injected. We now use the injector for each case, where in the beginning of the study it was not used for all cases.

Incisions are not enlarged at the moment of implantation..

PATIENT SELECTION

Patient selection is very important, as satisfactory results of surgery depend on it.

Selection is important before as well as during surgery.

Before surgery, patients with cataract undergo standard ophthalmic examinations.

This is the best way to avoid macular diseases, distortion and scotoma inducing worse results. In his prospective comparative study of mono and multifocal implant, Steinert (6) expresses the same opinion. According to him, the reduction of the proportion of light from a single focal plane may potentially reduce the performance of the low-vision device useful for macular degeneration.

Glaucoma with field defects is excluded but simple ocular hypertension without field defects can be fitted with multifocal implants.

Severe corneal opacities or haze are not good indications.

Diabetes without retinopathy is implantable with the Array, but diabetic retinopathy needing laser photocoagulation or macular oedema must be avoided.

The pupil size is important. With a pupil smaller than 2 mm, the patient is unable to reach the inner ring for near vision.

Good results depend also on an accurate biometry with a second generation IOL calculation formula. Every change of 0.1 mm in biometry induces 0.3 diopter IOL power and 0.25 diopter in the refraction. According to Javitt and Steinert (4), the multifocal lens is less tolerant of errors in preoperative measurement of ocular biometry and of lens decentration.

At the time of the study, the available IOL power ranged from 15 to 25 diopters. Today, in Bel-

gium, the available power ranges from 10 to 30 diopters.

Preop astigmatism under 3 diopters is a reasonable option. With higher astigmatism, arcuate limbic incision are instable.

Implantation also requires a patient with minimum mental ability.

We must be more careful with professional night drivers due to the risk of glare and halos.

During surgery, some points are important. Capsular bag implantation with good centration is better, as sulcus implantation induces a more important risk of decentration. Capsular bag opacities and wrinkles in the bag induce rapid loss of vision and require rapid YAG capsulotomy. The postop astigmatism is crucial.

POPULATION: PROPORTION OF MULTIFOCAL IMPLANTS

One surgeon (Ph.G) performed 340 cataract surgeries with 100 patients receiving the multifocal array (33 % of cases); the second surgeon (JM.H) adapted 240 multifocal ARRAY for 450 surgeries (47 % of cases).

We implanted a multifocal implant in both eyes in 85 % of selected cases. In 5 % of cases, a monofocal implant was implanted in the first eye, but we nevertheless chose to implant a multifocal in the second eye.

In 10 % of cases, the multifocal implant was inserted in the only operated eye.

It is advisable to operate the second eye rapidly after the first one.

RESULTS

Distance vision acuity

Our results for uncorrected far vision at 3 months are: 78 % of patients with 20/20, 14 % with 20/25 and 8 % with 20/40 or less.

The best corrected acuity was 20/20 for 98 % of patients. Some cases with macular lesion or amblyopia had 20/50 (fig 2).

Near Visual Acuity

At 3 months near vision was measured at 30 cm distance with Jaeger or Parinaud test (Jaeger 1 equal to Parinaud 2).

Jaeger 1 and 2 was obtained in 76 % of cases without optical correction, 98 % of patients obtained J1 with an optical correction.

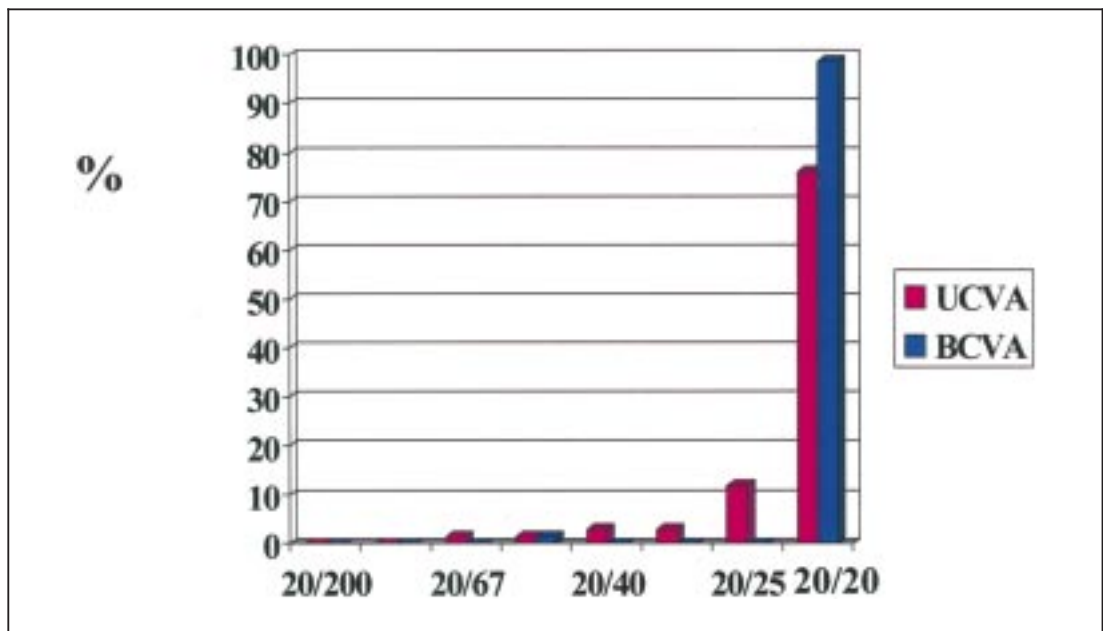


Fig 2. Results: UCVA BCVA for far vision at 3 months

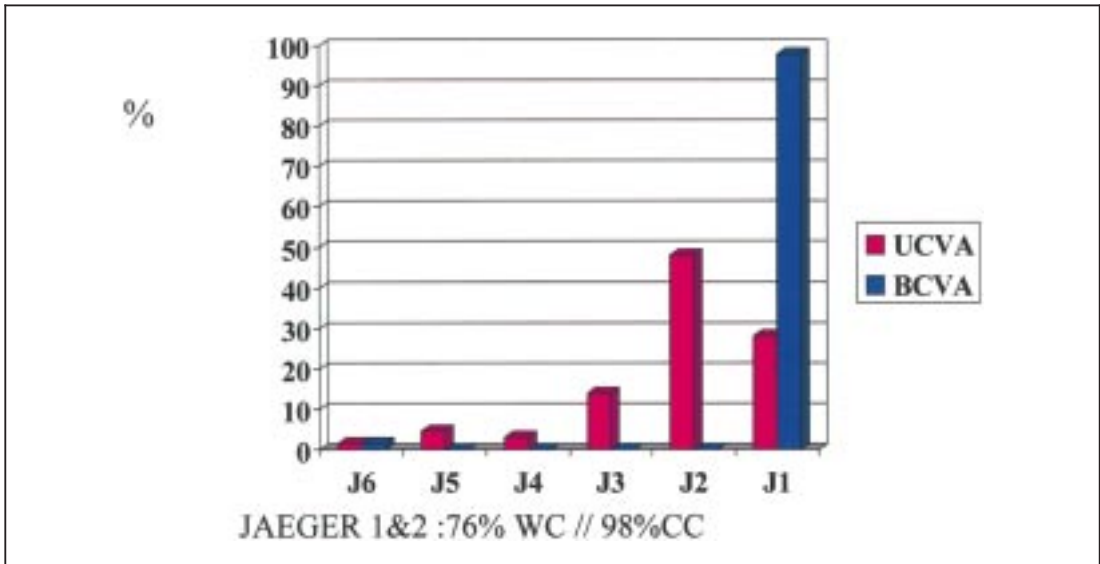


Fig 3. Results: UCVA BCVA for near vision (30 CM) at 3 months

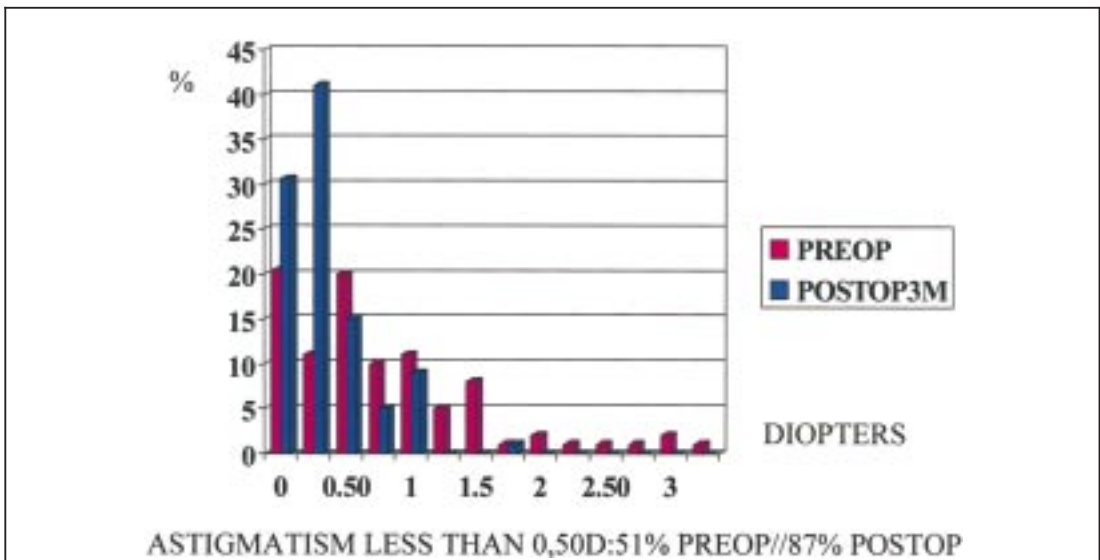


Fig 4. Pre- and post operative astigmatism

The worse Jaeger score corresponds to macular lesion amblyopia or high astigmatism (fig 3).

cases. Only 10 % of cases have 1 diopter of astigmatism, and 2 % have 1.5 D (fig 4).

Pre- and Postoperative Astigmatism

Good results with this implants depend on astigmatism. Preop astigmatism was less than 0.50 D in 51 % of cases. At 3 months, postop astigmatism under 0.50 D was found in 87 % of

Correlation Astigmatism-Near Vision

We found a correlation between astigmatism and near vision. In sixty five cases chosen at random, we observed a sudden drop in near vision acuity from 0.75 diopters of astigmatism or higher (fig 5).

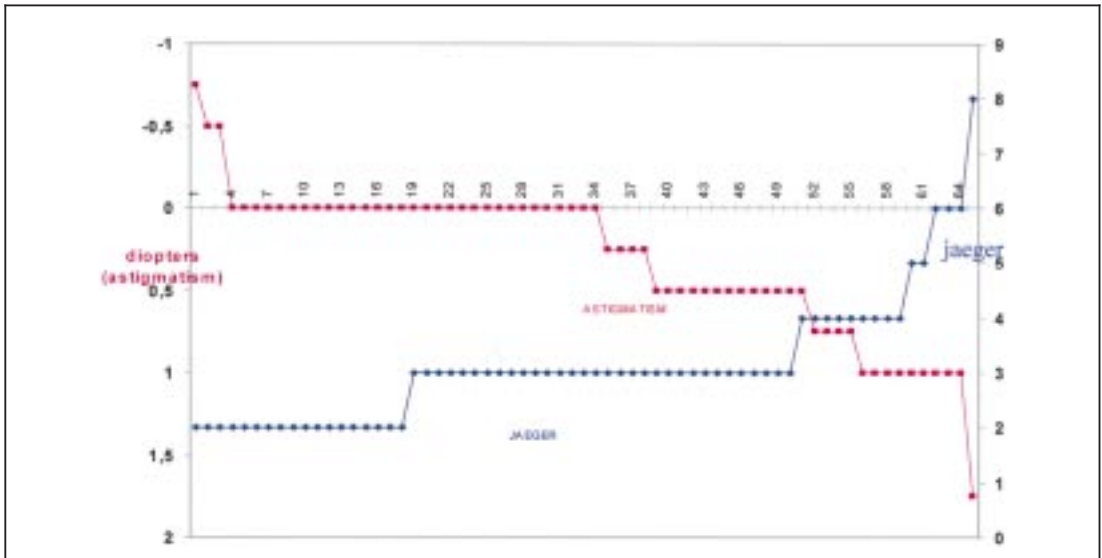


Fig 5. Correlation astigmatism-near vision

COMPLICATIONS

Complications were typically those seen after cataract surgery: iritis in one case (0,2%; 1 of 580), macular oedema in 1 case (0,2%), endophthalmitis in one case, retinal detachment after 6 months in 1 case, implant decentration with repositioning in one case.

The Array refractive error and blur circles.

Slides due to Steinert (7) show that for myopic postop refraction of 0.50 D or more, patients have very large blur circles but faint for near vision and more intense for far distance.

In comparison, for slightly hyperopic zero to 0.50 D, blur circles are fairly reduced for both

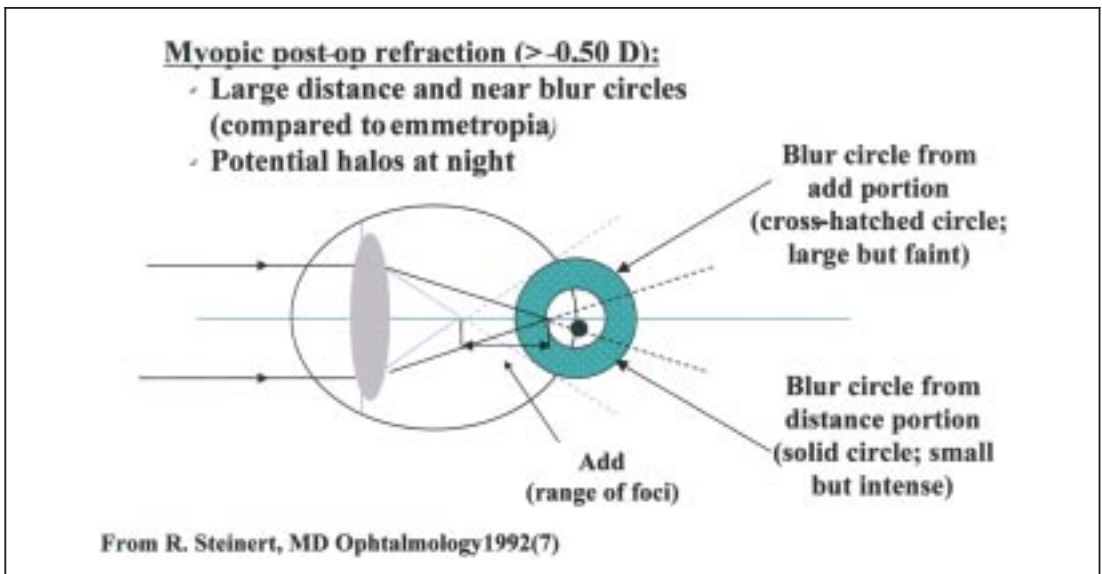


Fig 6. The Array®, refractive error and blur circles.

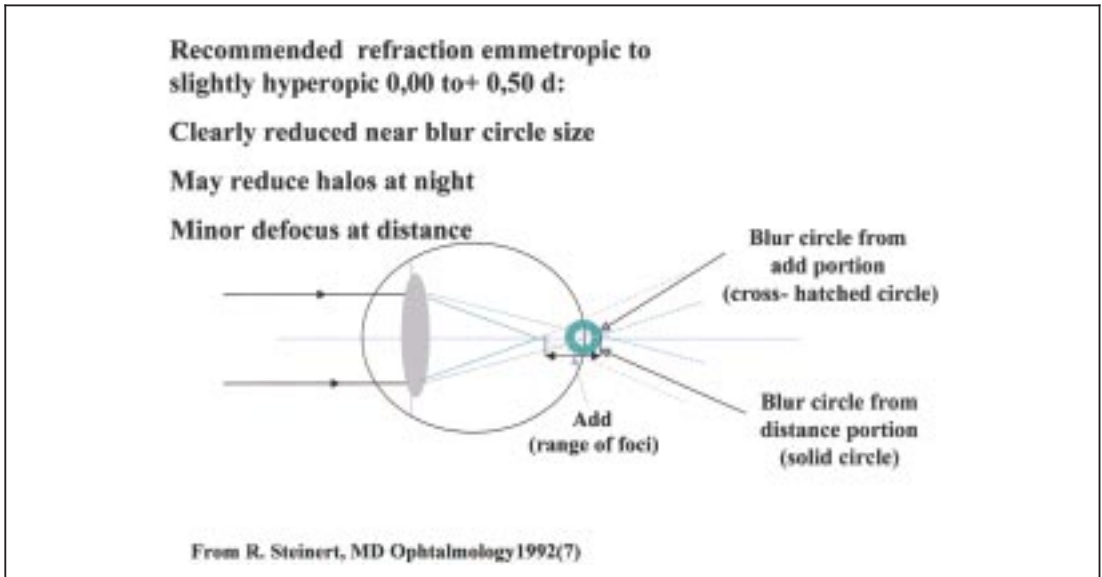


Fig 7. The Array®, refractive error and blur circles.

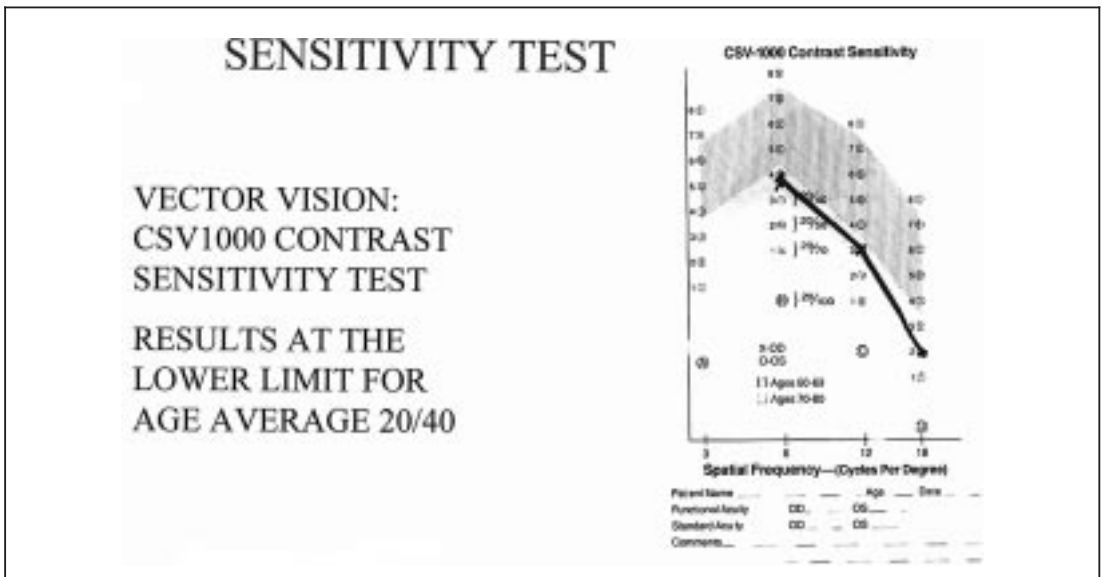


Fig 8. Results: contrast sensitivity test.

near and far vision. So the goal is to aim emmetropia or slight hyperopia less than 0.50 D, which reduces glare (3).

Contrast sensitivity

We studied the contrast sensibility with the CSV-1000 contrast sensitivity test (Vector Vision

USA). This test is composed of four parts. The A test consists in a standart acuity test. The B and the C tests are the contrast sensitivity tests consisting in white and black alternative bars respectively with 6 and 12 cycles per degree regarding the spatial frequency. The D test consists in a driving test. Those tests are lighted at a constant level of 85 cd/mm. They are used

for far distance. Fifty patients were tested with the monofocal an fifty with the multifocal. With the ARRAY°, the results were found at the lower limit for age: average 20/40 for B, C tests. Results were better with the monofocal.

CONCLUSIONS

We found good results for distance and near vision: 80% of preoperatively properly selected patients were postoperatively practically free from glasses in normal daily activity. Results are better for bilateral multifocal implantation.

A good centration is necessary as in case of decentration far and especially near vision falls, with big glare and halos.

Astigmatism smaller than 0.75, emmetropia or slight hyperopia are mandatory in postop for the same reasons.

There is nevertheless a small increase in glare and halos with multifocal in comparison with monofocal but this discomfort strongly diminishes with time.

REFERENCES:

- (1) EISEMAN D., JACOBI KW. – The Array multifocal IOL-concept and clinical results. *Klin Monatsbl Augenhk.* 1993; 203:189-194.
- (2) HOLLADAY JT., VAN DIJK H., LANG A. – Optical performance of multifocal intraocular lenses. *J Cataract Refractive Surgery* 1990 16 413-22

- (3) JAVITT J C., STEINERT R F. – Cataract Extraction with Multifocal Intraocular lens implantation. *Ophthalmology* 2000, 107, 2041-2048
- (4) PERCIVAL P., SETTY SS. – Comparative analysis of three prospective trials of multifocal implants. *Eye* 1991, 5, 712-61
- (5) STEINERT R.F. – Key elements in achieving good clinical outcomes with the Array Multi-focal IOL. ASCRS, Seattle 1999.
- (6) STEINERT R F., AKER B., TRENTACOST DJ. – A prospective comparative study of the AMO ARRAY Zonal progressive Multifocal silicone intraocular lens and a monocular lens. *Ophthalmology* 1999, 106, 1243-55
- (7) STEINERT RF. – A prospective, randomized, double-masked comparison of a zonal-progressive multifocal intraocular lens and a monofocal intraocular lens. *Ophthalmology* 1992, 99:853-860.
- (8) WILLIAMSON W., POIRIER L., COULON P., VERIN P. – Compared optical performances of multifocal and monofocal intraocular lens (contrast sensitivity and dynamic visual acuity). *Br J Ophthalmology* 1994, 78, 249-51

.....

*Request for reprints:
Dr Henry J-M
45, rue St Charles
B-6061 Montignies/s/Sambre*