

REDUCTION IN IOP AFTER CLEAR CORNEAL PHACOEMULSIFICATION IN NORMAL PATIENTS

MANNES K. *, ZEYEN T. **

SUMMARY

A prospective study was performed to evaluate the changes in intraocular pressure (IOP) after clear corneal phacoemulsification in normal patients. The mean preoperative IOP of 30 patients was compared with the IOP at 1, 2, 3, and 5 months postoperatively.

Lens extraction was associated with a reduction of IOP of 3,36 mmHg (SD +/- 2,33 - p = 0,005) after 5 months.

KEY-WORDS

intraocular pressure (IOP),
phacoemulsification.

MOTS-CLÉS

tension intra-oculaire, phaco-émulsification.

SAMENVATTING

Een prospectieve studie werd uitgevoerd om de intraoculaire drukveranderingen te evalueren na fako-emulsificatie. De preoperatieve druk van 30 patiënten werd vergeleken met de postoperatieve druk na 1, 2, 3 en 5 maanden.

Cataractextractie heeft een drukdalend effect van 3,36 mmHg (SD +/- 2,33 - p = 0,005) na 5 maanden.

RÉSUMÉ

Une étude prospective a été réalisée sur 30 yeux normaux afin d'évaluer l'effet d'une phaco-émulsification sur la tension intra-oculaire. En comparant la tension avant l'opération et 1, 2, 3 et 5 mois après la phaco-émulsification, nous constatons une diminution de 3,36 mmHg (SD +/- 2,33 - p = 0,005)

.....

* Middelheim Hospital, Antwerp.

** KUL, Leuven.

received: 20.06.01

accepted: 06.08.01

INTRODUCTION

Many studies examining long-term changes in intraocular pressure (IOP) after cataract surgery using extracapsular extraction (3, 11) phaco-emulsification with scleral tunnel (4) or with clear corneal incision (15) have demonstrated a lowering of the IOP in the operated eye.

In the early postoperative stage, an elevation of the IOP may be noted which is due to retained viscoelastic material (14) or diminished aqueous outflow facility (8).

The IOP often normalizes after a few weeks and has the tendency to decrease afterwards.

The purpose of this prospective study was to examine the changes of IOP after clear corneal phacoemulsification (CCP) in normal patients after 5 months.

METHODS

A prospective study including 30 eyes of normal patients was performed. Eyes were included in the study if they had no history of ocular surgery, laser traumatism, preoperative IOP greater than 22 mmHg and were not on ocular medication.

The same surgeon performed temporal clear corneal phacoemulsification with IOL implantation. One eye per patient was included in the analysis, 15 right- and 15 left eyes.

Most of the patients underwent surgery under retrobulbar anaesthesia using marcaine.

All patients received topical combination of dexamethasone and neomycine during 6 weeks after surgery.

The IOP was measured by applanation, mostly by the same examiner. A mean of 2 IOP's was recorded within 6 months before surgery.

The IOP was recorded 1,2,3 and 5 months after surgery.

RESULTS

Thirty patients (22 women and 8 men) were followed-up for a period of 5 months. The mean age was 76.5 ± 8 years.

The mean IOP before surgery was 14,65 mmHg (SD: 2,13 mmHg). The maximum IOP was 18,5 mmHg and the minimum 9 mmHg.

The evolution of IOP in mmHg is shown in Figure 1.

After 1 month the mean IOP was 12.97 ± 2.83 mmHg ($p = 0.011$), after 2 months 11.85

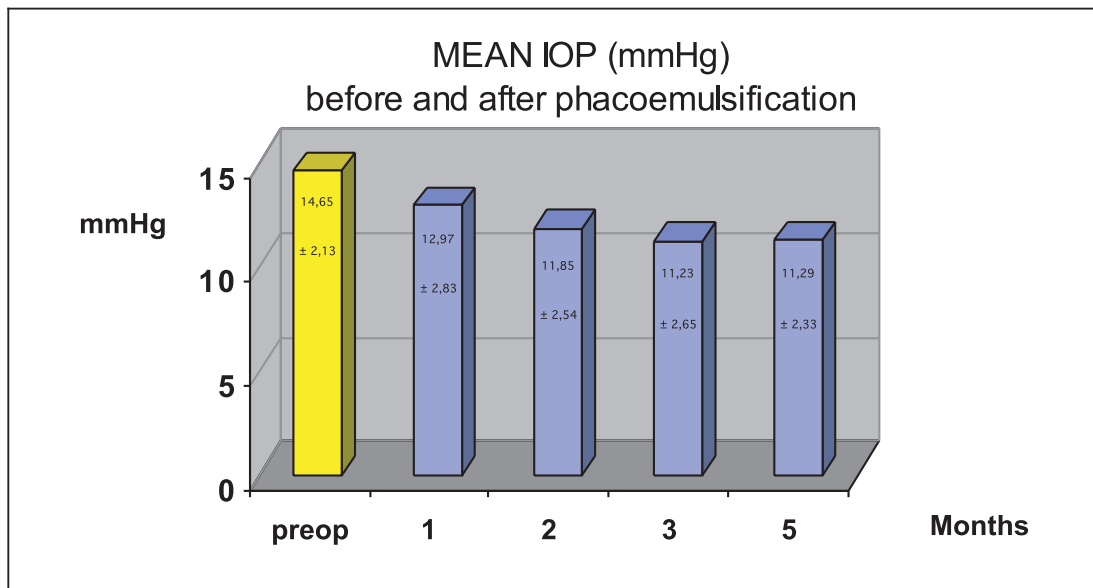


Fig 1.

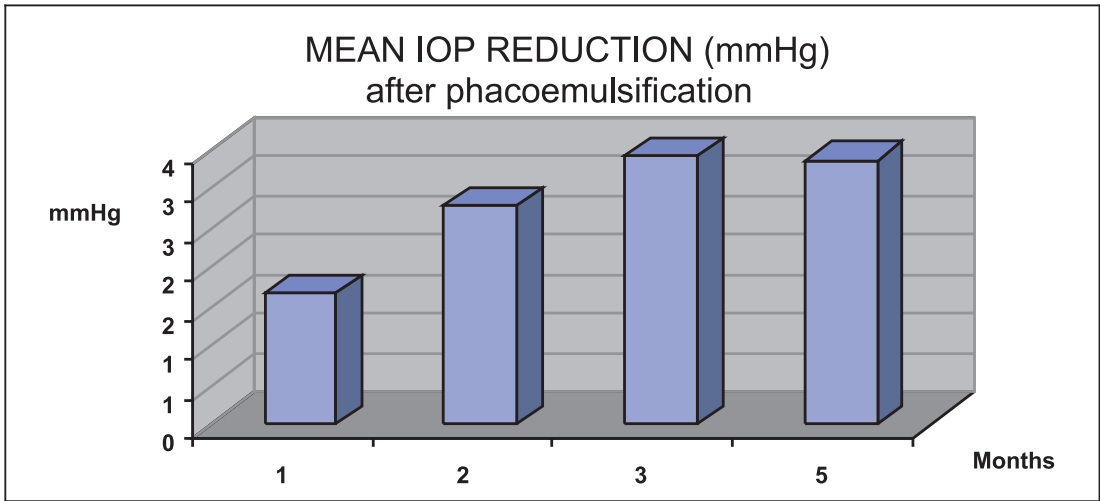


Fig 2.

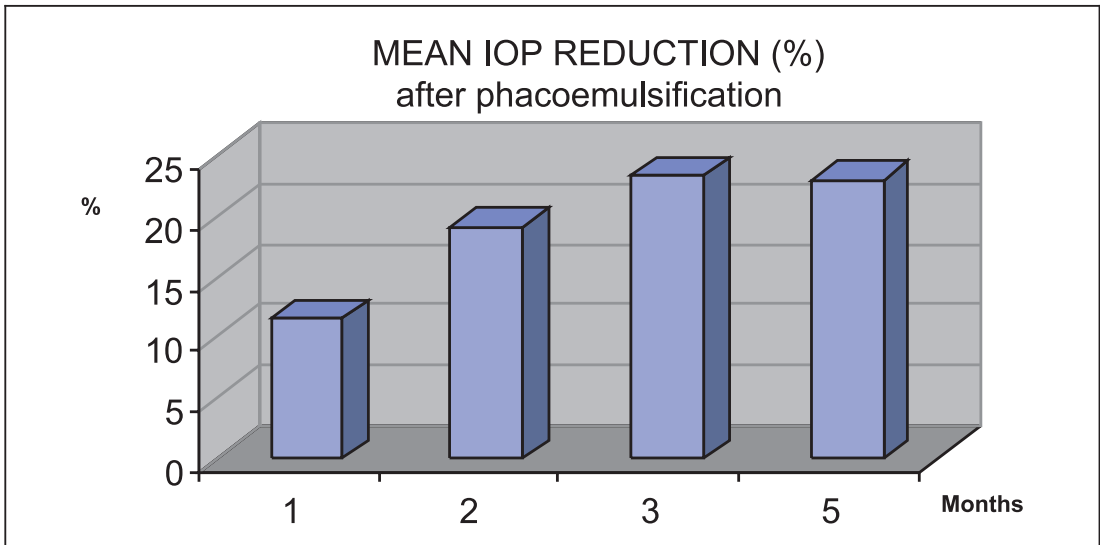


Fig 3.

± 2.54 mmHg ($p = 0.017$), after 3 months 11.23 ± 2.65 mmHg ($p = 0.015$), and after 5 months 11.29 ± 2.33 mmHg ($p = 0.005$). The reduction of IOP in mmHg and in % is shown in Figures 2 and 3.

The reduction of IOP measured after one month was 1.68 mmHg (11.49 %), after 2 months 2.80 mmHg (19.11 %), after 3 months 3.42 mmHg (23.34 %), and after 5 months 3.36 mmHg (22.94 %).

The most important IOP reduction was 8.5 mmHg and 3 patients had no reduction of IOP. No patients had an increased IOP after 5 months.

DISCUSSION

Increased IOP has been described after extracapsular cataract extraction (ECCE) with implantation of posterior chamber lenses (1, 3, 5, 10, 11).

Postoperative IOP control has been improved by advances in cataract surgery such as phacoemulsification.

IOP decrease after clear corneal phacoemulsification in normal patients has been demonstrated by Jahn, Meyer et al and Tanaka (4, 8, 14). They showed a reduction in IOP varying from 0.5 to 3 mmHg. This is slightly less than in our study which shows a mean reduction of 3.4 mmHg (23%) after 5 months. A recent study shows that the IOP reduction is more important after clear corneal phacoemulsification than after sclerocorneal tunnel phacoemulsification (12).

It is not clear by which mechanism CCP decreases the IOP. The size of the capsulorhexis seems to have an effect on the IOP after phacoemulsification: it has been shown that a capsulorhexis of 4 mm gives more traction on the zonulae and thus more reduction of the IOP than a capsulorhexis of 6 mm (2). Another explanation for the short-term decrease of IOP after cataract extraction (ECCE or phacoemulsification) is the improvement of aqueous outflow due to the increased anterior chamber depth postoperatively which opens the angle, especially in patients with a low aqueous outflow facility (5, 6, 8). Wang et al showed that ultrasound stimulates the production of interleukine 1 α by the trabecular meshwork, increasing outflow facility (16). It may also be that the irrigation during phacoemulsification flushes the trabeculum, thereby decreasing outflow resistance.

Several studies suggest that CCP has a pressure lowering effect in patients with open-angle glaucoma (7, 9, 13). Our study was performed in a population of normal patients but showed a similar effect. If the pressure lowering effect of CCP is confirmed in the long term, this may modify our treatment strategy in patients with concomitant cataract and glaucoma, and favour staging instead of combining procedures.

REFERENCES

(1) CALISSENDORF B.M., HAMBERG-NYSTROM H. – Intraocular pressure after extracapsular cataract extraction with implantation of posterior chamber lenses. *Acta Ophthalmol* (Copenh) 1993; 71: 377-81.

(2) CEKIC O., BATMAN C. – Effect of capsulorhexis size on postoperative intraocular pressure. *J Cataract Refract Surg* 1999; 25: 416-9.

(3) HANSEN TE. – A prospective study of intraocular pressure for months after extracapsular cataract extraction with implantation of posterior chamber lenses. *J Cataract Refract Surg* 1987; 13: 35-8.

(4) JAHN CE. – Reduced intraocular pressure after phacoemulsification and posterior chamber intraocular lens implantation. *J Cataract Refract Surg* 1997; 23: 1260-1264.

(5) KOONER K.S., DULANEY D.D., ZIMMERMAN T.J. – Intraocular pressure following extracapsular cataract extraction and posterior chamber intraocular lens implantation. *Ophthalmic Surg* 1988; 19: 471-4.

(6) LEE K.W. – Intraocular pressure following peritomy and wet field coagulation. *Korean J Ophthalmol* 1990; 4: 92-102.

(7) LINK S., HARING G., HEDDERICH J. – Effect of phacoemulsification and posterior chamber lens implantation on intraocular pressure in patients with and without open-angle glaucoma. *Ophthalmologie* 2000; 97: 402-6.

(8) MEYER M.A., SAVITT M.L., KOPITAS E. – The effect of phacoemulsification on aqueous outflow facility. *Ophthalmology* 1997; 104: 1221-1227.

(9) PILLUNAT L.E., KAMMAN J., KOHLHAAS M. – Clear cornea phacoemulsification as an intraocular pressure lowering procedure in glaucoma. [ARVO Abstract]. *Invest Ophthalmol Vis Sci*. 2001; 42: S106. Abstract nr. 579.

(10) RADIUS R.L., SCHULTZ K., SOBOCINSKI K. – Pseudofakia and intraocular pressure. *Am J Ophthalmol* 1984; 97: 738-742.

(11) SACCA S., MARLETTA A., PASCOTTO A., BARABINO S., ROLANDO M., GIANNETTI R., CALABRIA G. – Daily tonometric curves after cataract surgery. *Br J Ophthalmol* 2001; 85: 24-9.

(12) SCHWENN O., DICK H.B., KRUMMENAUER F., KRIST R., PFEIFFER N. – Intraocular pressure after small incision cataract surgery: temporal sclerocorneal versus clear corneal incision. *J Cataract Refract Surg* 2001; 27: 421-5.

(13) SHINGLETON B.J., GAMELL L.S., O'DONOGHUE M.W., BAYLUS S.L., KING R. – Long-term changes in intraocular pressure after clear corneal phacoemulsification: Normal patients versus glaucoma suspect and glaucoma patients. *J Cataract Refract Surg*. 1999, 25, 885-90.

- (14) TANAKA T., INOUE H., KUDO S., OGAWA T. – Relationship between postoperative intraocular pressure elevation and residual sodium hyaluronate following phacoemulsification and aspiration. *J Cataract Refract Surg* 1997; 23: 284-288.
- (15) TENEN D.G., MASKET S. – Short- and long-term effect of clear corneal incisions on intraocular pressure. *J Cataract Refract Surgery* 1996; 22: 568-570.
- (16) WANG N., CHINTALA S.K., PAGE M.A., FINI M.E., SCHUMAN J.S. – Interleukin-1 alpha is produced by cultured trabecular meshwork cells after phacoemulsification ultrasound exposure. [ARVO Abstract]. *Invest Ophthalmol Vis Sci*. 2001;42: S315. Abstract 1703.

Address for correspondence:
Dr Karine Mannes
AZ Middelheim
Lindendreef 1
B-2020 Antwerpen
03/280.31.05.