

COMBINED FOURTH AND SIXTH CRANIAL NERVE PALSY AFTER LUMBAR PUNCTURE: A RARE COMPLICATION. A CASE REPORT.

FOLLENS I. *, GODTS D. *, EVENS P.A. *,
TASSIGNON M.J. *

ABSTRACT

Palsies of cranial nerves are well-known complications after lumbar puncture. Sixth nerve palsies are the most common. They normally occur 4 to 14 days after the lumbar puncture and spontaneously recover in a few weeks or months. The occurrence of a fourth nerve palsy following lumbar puncture however is extremely rare.

We report on a patient who developed a combined contralateral fourth and sixth nerve palsy after lumbar puncture (Syndrome of Intracranial Hypotension), requiring surgical correction for secondary diplopia.

RÉSUMÉ

Une des complications connues après ponction lombaire est la paralysie d'un ou plusieurs nerfs crâniens. Le nerf le plus souvent atteint est le sixième. En général ces paralysies se développent 4 à 14 jours après la ponction lombaire et récupèrent spontanément après quelques semaines ou quelques mois. D'autre part, l'apparition d'une paralysie du quatrième nerf crânien est extrêmement rare.

Nous décrivons ici le cas d'un patient qui a développé une paralysie combinée contralatérale du quatrième et sixième nerf crânien après une ponction lombaire, se situant dans le cadre d'un Syndrome

d'Hypotension Intracranienne et nécessitant une intervention chirurgicale de la diplopie secondaire.

KEY-WORDS

Fourth nerve palsy - Sixth nerve palsy - lumbar puncture - Syndrome of Intracranial Hypotension - Diplopia

MOTS-CLÉS

Paralysie du sixième nerf crânien - paralysie du quatrième nerf crânien - ponction lombaire - Syndrome d'Hypotension Intracranienne - Diplopie

.....

* *Department of Ophthalmology, University Hospital Antwerp, Belgium*

received: 15.03.01

accepted: 12.06.01

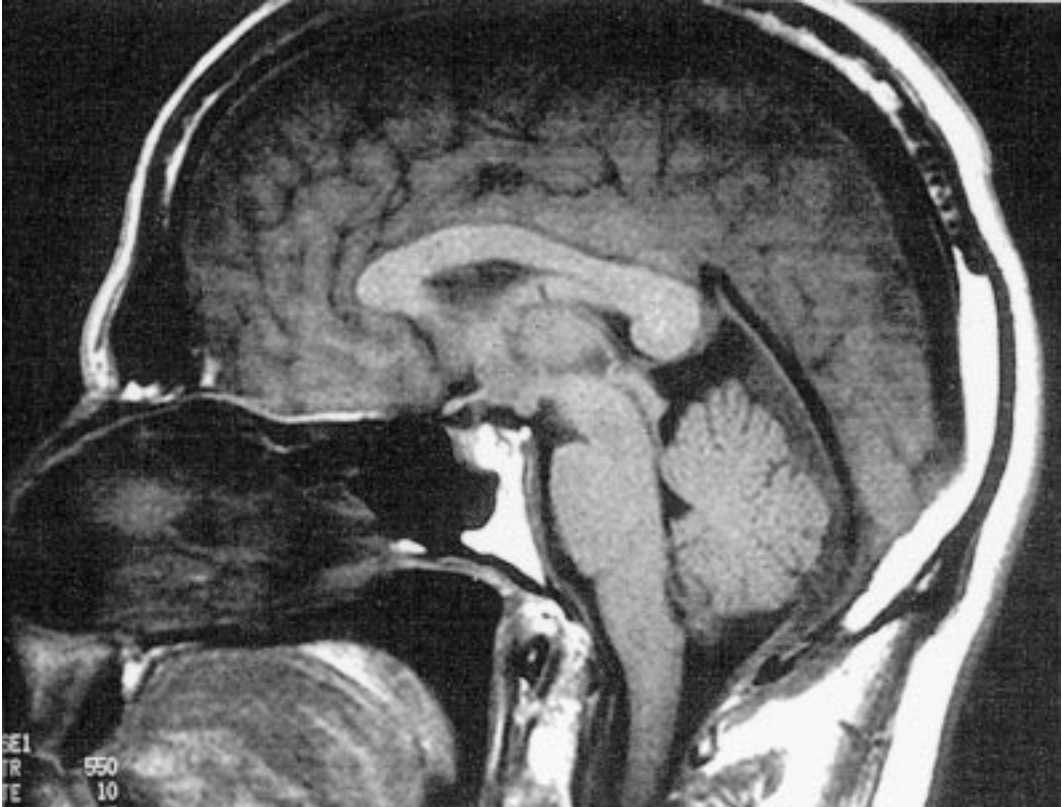

Fig 1. MRI of the brain shows a downwards displacement of the brainstem.

CASE REPORT

A 37 year old man noted a left-sided hypoesthesia for several months. After neurological investigation showing subnormal electrophysiological findings, a trial with anti-epileptics was started. There was no improvement and the patient was referred for MRI of the brain and lumbar spine. This test was normal as was the lumbar puncture performed during a short hospitalisation.

The patient developed suddenly a severe headache and complained of diplopia, necessitating a re-admission to the hospital 5 days after his first discharge. Neurological examination revealed palsy of the left Abducens nerve. MRI of the brain showed bilateral subdural hemorrhages and a downward displacement of the brainstem (fig.1). Because of the severity of the patients' complaints, a treatment with blood-patch was proposed by the neurologist. Following this treatment, the headache decreased but

the diplopia however did not improve. One month later, MRI of the brain showed a residual subdural hemorrhage. Because of the persisting diplopia, lasting for 3 months now, a neuro-ophthalmological advice was asked. The orthoptic examination revealed a sixth cranial nerve palsy of the left eye and a fourth cranial nerve palsy of the right eye (fig.2). Electrophysiological examination (visual evoked potentials) was normal and no visual field defects were detected.

Since spontaneous recovery is often the rule in case of cranial nerve palsies after lumbar puncture, a wait-and-see policy was followed. The 2-monthly orthoptic examinations showed some clinical improvement but diplopia in the horizontal and the vertical direction persisted and unabled the patient to work (fig.3). Eighteen months later, a first strabological intervention was performed consisting in a desinsertion of the right Inferior Oblique Muscle and resulting

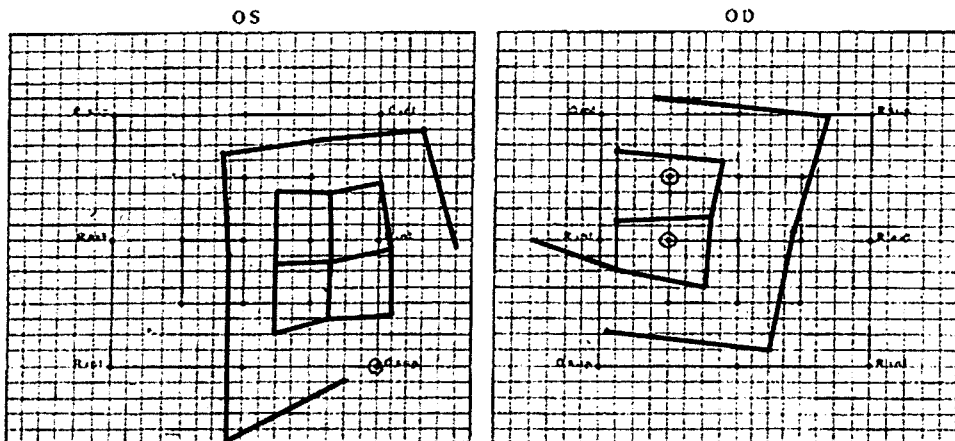


Fig 2. First orthoptic examination, revealing a sixth cranial nerve palsy of the left eye and a fourth cranial nerve palsy of the right eye.

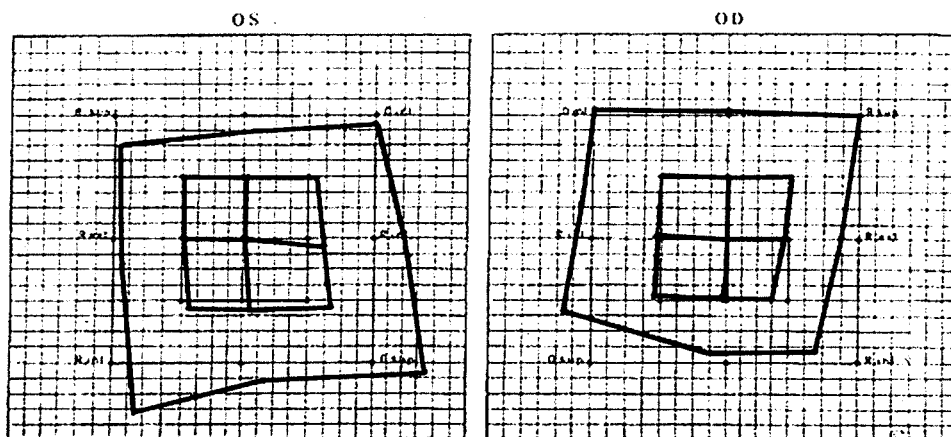


Fig 3. After eighteen months, the orthoptic examination showed improvement, but there was still an underaction of the left M. Abducens and the right M. Obliquus Superior.

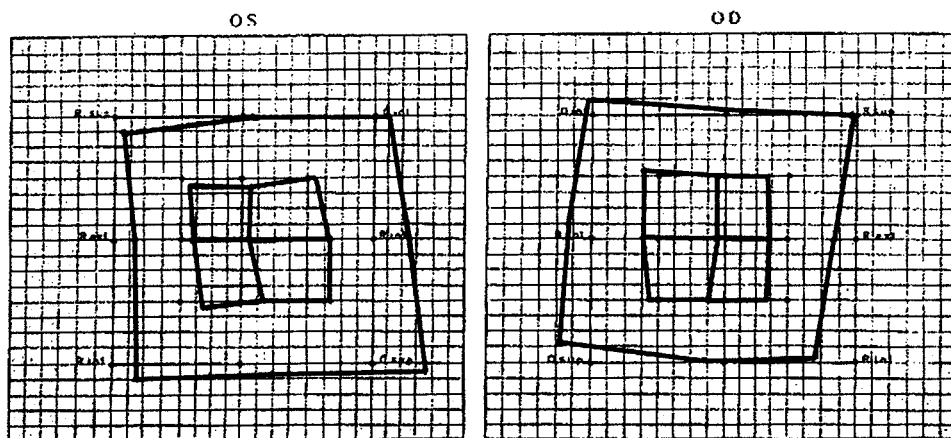


Fig 4. Orthoptic examination after desinsertion of the right M. Obliquus Superior and an additional recession of the left M. Abducens, still shows an underaction of the right M. Obliquus Superior, causing a small vertical diplopia.

in a diminished vertical diplopia, although the horizontal diplopia at distance remained unchanged. Therefore an additional recession of the Medial Rectus Muscle was carried out 2 months later (fig 4)

The patient was able to resume his social activities, although with a small remaining vertical diplopia.

DISCUSSION

The Syndrome of Intracranial Hypotension (SIH) (1,13) is due to **leakage** of cerebrovascular fluid (CSF) to the epidural space as a result of a lumbar puncture. Subsequently, the CSF-pressure drops. The 'cushion-effect' of the CSF is lost and the brain sags, leading to traction on the intracranial sensitive structures, namely the bloodvessels, nerves and tentoria. Compensatory **cerebral vasodilation** is an additional effect, as a result of the decreased CSF volume.. This leads to an increased weight of the brain, which causes further sagging in upright position.

SIH encompasses a triade of symptoms: **headache**, probably as a result of traction on pain sensitive structures (in particular the fifth cranial nerve and the upper three cervical nerves) and dilation of painsensitive bloodvessels (3), **ear problems** probably due by reduced intralabyrinthine pressure and secondary failure of transmission of high frequency sound (3,6,13) and **ocular symptoms** due to cranial nerve palsy (2,4,5,8-14).

Palsies of every cranial nerve (except cranial nerve I, IX and X) have been described following lumbar puncture. Unilateral and bilateral sixth nerve palsies are the most common, but combined nerve palsies may occur and even a complete unilateral ophthalmoplegia has been reported. The overall incidence of the sixth nerve palsy is 1 in 400. The onset is usually 7 to 8 days after lumbar puncture and occurs more frequently in young persons and men. The palsy generally recovers within days to months, but can persist. One explanation for the particular liability of the sixth nerve to palsy, results from its anatomical course. Emerging from the lower border of the pons, the nerve steeply ascends between pons and clivus. It crosses branches of the basilar artery and penetrates

the dura while still on the clivus. At the sharp of the rim of the pyramidal apex, it changes to an almost horizontal and sagittal direction before entering the sinus cavernosus.

As a result of a downward displacement of the brain, the anterior cerebellar artery may compress the nerve. Stretching at the bony ridge of the petrous bone may also contribute to the nerve palsy. Although bilateral palsy can follow lumbar puncture, there is an overwhelming incidence of unilateral palsies due to anatomic asymmetry.

The cause of the fourth cranial nerve palsy is probably compression of the nerve between brainstem and vessel or bone. A fourth nerve palsy following lumbar puncture or spinal anesthesia is extremely rare.

Most authors refer to *Thorsen* (13), who reviewed 324 cases of cranial nerve palsies after lumbar puncture and spinal anesthesia. Among these 324 cases, 299 presented an isolated sixth nerve palsy. In 8 cases, a simultaneous injury to another cranial nerve was found. There were 2 cases of a solitary fourth nerve palsy, and 3 cases of a combined fourth and sixth nerve palsy with a palsy of an additional nerve.

Mansour and Reinecke (7) described a case of a Trochlear nerve palsy after spinal anesthesia.

Rucker (10), who described 1000 cases with palsies of the nerves of the extra-ocular muscles found a combined fourth and sixth nerve palsy in one patient who suffered head injury in a motorcycle accident. All other cases presenting an ipsilateral fourth and sixth nerve palsy had additionally a third cranial nerve involvement.

Vandam and Dripps (14) reporting on a long term follow-up of 9277 patients who underwent spinal anesthesia didn't mention any case of fourth nerve palsies.

King and Calhoun (5) reported on one patient who developed an ipsilateral combined sixth and fourth nerve palsy following spinal anesthesia, of which the sixth nerve palsy resolved spontaneously and the right fourth nerve palsy needed to be treated by prism. The fourth nerve palsy was diagnosed only after the recovery of the sixth nerve palsy. In our case, the sixth and fourth nerve palsy did not occur in the same

eye, and both the sixth and fourth nerve palsy did not recover spontaneously.

The question can be raised whether the fourth nerve palsy in our case was acquired rather than a decompensation of a congenital form. The differential diagnosis is often difficult. Our patient presented an incomitant hypertropia that was more pronounced in adducted down-gaze. In congenital palsies however, the amount of vertical deviation is more pronounced and maximal in upgaze. On the other hand, congenital palsies have larger fusion amplitudes compared to the traumatic ones. Our patient had more than 4 prism diopters of vertical fusion amplitude, a finding that is more common in the congenital group. Additional evidence in favour of the acquired nature of the fourth nerve palsy is that there was no cyclodeviation on direct fundoscopy. We therefore presume that the fourth nerve palsy was acquired. The possible role of the Epidural Blood Patch (EBP) in the development of the cranial nerve palsy is also questionable. This treatment was first introduced by James Gormley in 1960. He reasoned that if a patch or sealing material could be placed adjacent to the arachnoid puncture, a permanent closure would follow. Since then, blood has been injected epidurally in patients suffering from severe cephalgia after lumbar puncture. The occurrence of cranial nerve palsies after EBP has been described but a causal relation still needs to be established (15,16). In our case we are sure that the sixth cranial palsy was present before administration of the EBP.

BIBLIOGRAPHY

- (1) APTE R., BARTEK W., MELLO A. – Spontaneous Intracranial Hypotension. *Am. J. Ophthalmology*, 1999, 127, 482-484
- (2) DE VEUSTER I., SMET H., VERCAUTEREN M. – The time course of a Sixth nerve Paresis following Epidural Anesthesia. *Bull. Soc. belge Ophthalmol.*, 1994, 252, 45-47
- (3) GIELEN M. – Post Dural Puncture Headache. *Regional Anesthesia*, 1989, 14, 10-105
- (4) INSEL T., KALIN N. – Abducens Palsy after Lumbar Puncture. *N. Engl. J. Med.*, 1980, 303(12), 703-703
- (5) KING R., CALHOUN J. – Fourth Cranial nerve Palsy Following Spinal Anesthesia. *J. of Clinical Neuro-Ophthalmol.*, 1987, 7, 20-27
- (6) LEE CH., PEACHMAN A. – Unilateral Hearing Loss after Spinal Anesthesia Treated with Epidural Blood Patch. *Anesth. Analg.*, 1986, 65, 312-313
- (7) MANSOUR AM., REINECKE RD. – Central Trochlear Palsy. *Survey Ophthalmol.*, 1986, 30, 279-297
- (8) MILLER E., SAVINO P., SCHATZ N. – Bilateral Sixth Nerve Palsy: a Rare Complication of Water-Soluble Contrast Myelography. *Arch. Ophthalmol.*, 1982, 100, 603-604
- (9) MOSTER M., SAVINO P., SERGOTT R., BOSLEY T., SCHATZ N. – Isolated Sixth Nerve Palsies in Younger Adults. *Arch. Ophthalmol.*, 1984, 102, 1328-1330
- (10) RUCKER CW. – The Causes of Paralysis of the Third, Fourth and Sixth cranial nerves. *Am. J. Ophthalmol.*, 1966, 61, 1293-1298
- (11) RUSH JA., YOUNG BR. – Paralysis of Cranial nerves III, IV and VI: Cause and Prognosis in 1000 Cases. *Arch. Ophthalmol.*, 1981, 99, 76-79
- (12) SEYFERT S., MAGER J. – Abducens Palsy after Lumbar Myelography with Watersoluble Contrast Media. *J. Neurol.*, 1978, 219, 213-220
- (13) THORSEN G. – Neurological Complications after Spinal Anesthesia. *Acta Chir. Scand.*, 1947, 95 Suppl. 121, 1-272
- (14) VANDAM L., DRIPPS R. – Long-Term Follow-up of Patients who received 10 098 Spinal Anesthetics: Syndrome of Decreased Intracranial Pressure. *J.A.M.A.*, 1956, 161, 586-591
- (15) VERCAUTEREN M., VUNDELINCKX G. – Postpartum Headache, Seizures and bloodstained CSF: a Possible Complication of Dural Puncture? *Intensive Care Med.*, 1988, 14, 176-177
- (16) VERCAUTEREN M., HOFFMANN V., MERTENS E. – Seven-Year Review of Request for epidural Blood Patch for Headache after dural puncture: Referral Patterns and Effectiveness of Blood patches. *Eur. J. Anesthesiology*, 1999, 16, 298-303

.....

*Correspondence and requests for reprints:
Dr. Ingrid Follens
Dienst Oogheelkunde UZ Antwerpen
Wilrijkstraat 10
B-2650 Edegem.
e-mail: Ingridfollens@yahoo.com*