

ELIGIBILITY CRITERIA FOR ND-YAG LASER TREATMENT OF HIGHLY SYMPTOMATIC VITREOUS FLOATERS

VANDORSELAER T*, VAN DE VELDE F*,
TASSIGNON M.J.*

ABSTRACT

Ten eyes of nine patients were treated for very disturbing vitreous floaters with the technique of Nd-YAG laser vitreolysis. The Scanning Laser Ophthalmoscope (SLO) was used to objectivate the position, the size and the motility of the vitreous floaters with respect to the patient's visual axis, which can be precisely located with the SLO.

With this technique it was possible to define more precisely some eligibility criteria for Nd-YAG laser treatment of vitreous floaters and to classify the vitreous floaters in ill-suspended and well-suspended floaters in the vitreous body, the well-suspended floaters responding better to treatment compared to the ill-suspended vitreous floaters.

The treatment was performed using the Q-Switched Nd-YAG Laser type Nanolas 15S of Alcon.

SAMENVATTING.

Tien ogen van 9 patiënten werden voor storende vitreumopaciteiten behandeld met de Q-switched Nd-Yag laser. The Scanning Laser Ophthalmoscope (SLO) werd gebruikt om de plaats, de grootte en de mobiliteit van de vitreumtroebelingen te bepalen ten opzichte van de visuele as van de patiënt, die hiermee precies kan gelokaliseerd worden.

Met deze techniek was het mogelijk de vitreumopaciteiten in te delen in "ill-suspended" en "well-suspended" en tevens het indicatiegebied voor de YAG laser vitreolyse te bepalen. De well-suspended opaciteiten reageren beter op de behandeling dan de ill-suspended opaciteiten.

.....

* *University Hospital Antwerp, Department of Ophthalmology, Wilrijkstraat 10, B-2650 Edegem*

received: 27.11.00

accepted: 27.03.01

De behandeling gebeurde met de Q-switched Nd-YAG laser type Nanolas 15S van Alcon.

RÉSUMÉ

La technique de vitréolyse au laser YAG a été utilisée pour le traitement de 10 yeux (9 patients) présentant des corps flottants gênants. Le Scanning Laser Ophthalmoscope (SLO) a été employé afin d'évaluer la position, la taille et la mobilité du ou des corps flottants par rapport au point de fixation qui peut être déterminé avec précision grâce au SLO.

Cette technique a permis de définir avec plus de précision des critères d'éligibilité pour le traitement au laser YAG de corps flottants et de classer les corps flottants vitréens en corps flottants "bien suspendus" et "mal suspendus". Les corps flottants "bien suspendus" répondent mieux au traitement que les mal suspendus.

Le traitement a été réalisé à l'aide du Q-Switched Nd-YAG Laser type Nanolas 15S d'Alcon.

KEY-WORDS

vitreous floaters, SLO, Nd-YAG laser

MOTS-CLÉS

corps flottants, vitré, SLO, Laser Nd-YAG.

INTRODUCTION

Floater are commonly found in daily ophthalmological practice (14). The etiology of these floaters may be physiological with or without posterior vitreous detachment or secondary to vitreoretinal disorders (5,14,21). They usually do not need treatment because of spontaneous sedimentation. However, in some cases, they may be important and disturb visual function significantly (22). A non-invasive therapeutic approach, the Q-switched Nd-YAG laser vitreolysis, was used to treat 10 eyes of 9 patients.

MATERIAL AND METHODS

Between October 1996 and December 1998, 9 patients (10 eyes) presenting severe visual impairment due to vitreous floaters, underwent a Q-Switched Nd-YAG Laser vitreolysis. The inclusion criteria were symptoms present for months without evidence of regression, severe floaters impairing the patient's daily life comfort and patients expecting a solution for their problems. A decreased visual acuity was not an obligatory inclusion criterium. Pre-operative visual acuity was 10/10 in 2 eyes, 9/10 in 1 eye (because of lens opacities), 8/10 in 1 eye (because of high myopia and lens opacities), 4/10 in 2 eyes (because of ARMD in one eye and because of the floater itself in the other eye), 3/10 in 2 eyes (because of the floater itself in one eye and a vascular occlusion in the second one) and 1/10 in 2 eyes (because of retinal detachment and macular pucker in the past). Before treatment, each patient underwent a full ophthalmological examination comprising a retinal examination with a Goldmann three-mirror contact lens and a dynamic examination of the vitreous floater with the SLO.

The SLO allows the evaluation of the size, the position and the motility of the floater with respect to the patient's point of fixation or visual axis.

Using the SLO, it was possible to objectivate the vitreous condensation and to define its suspension characteristics within the vitreous body. In case the vitreous floater was suspended with several well-defined (tiny) vitreous strands, which

Fig 1. Example of a "well-suspended" vitreous floater. The white arrows follow the tiny vitreous strands on which the floater is suspended. The black arrows show the location where the Nd-YAG laser treatment is performed.

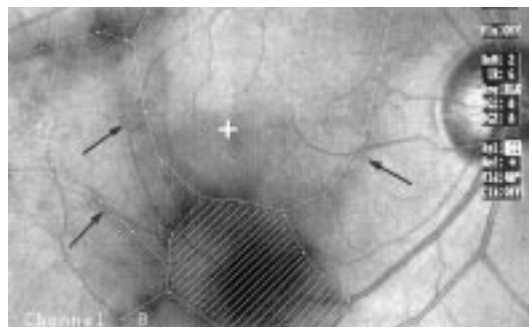
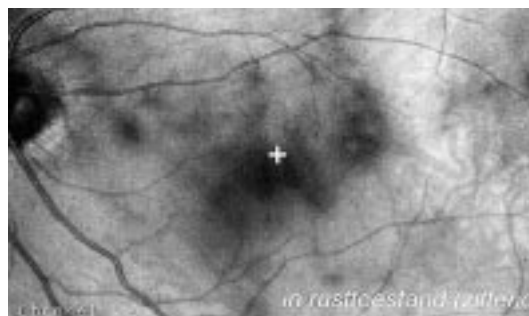


Fig 2a: Example of an "ill-suspended" vitreous floater. The vitreous floater is loosely located within the vitreous body



often appear under tension, it was classified as well-suspended (fig 1). In case the dense vitreous floater was not suspended as such, but rather loosely located within the vitreous body, it was classified as ill-suspended (fig 2).

The treatment was performed under topical anaesthesia. The patient's pupil was dilated with a mixture of Tropicol® 0,5% (1/3) and Phenylephrine® 5% (2/3).

The Nd-YAG Laser used was the Q-Switched Nd-YAG Laser type NANOLAS 15S ALCON. The aim of the treatment was to destroy or to reduce the volume of the vitreous floater in case of ill-suspended floaters. In case the vitreous floater was well-suspended, the aim was to cut the tiny little strands on which the floater was attached till the floater fell downwards and the optical axis became clear. The energy per burst was 7 to 8 mJ and the number of bursts varied between 118 and 191 per session with an average of 152 bursts per session. The numbers of sessions varied from 1 to 5. The laser beam

angulation was 13°. The contact lens used was the three-mirror glass of Goldmann when the vitreous floater was located posteriorly. When the vitreous floater was located anteriorly or in the mid-vitreous the CGV lens of Rol was used. Six of the 9 patients were males and 3 were females. Their ages ranged from 46 to 72 years (average of 61 years). The vitreous floaters were idiopathic in 5 cases, secondary to a vitreous hemorrhage in 2 cases, secondary to vitreous changes after retinal detachment in two cases and secondary to a posterior hyaloid detachment in one case.

With each burst, fragmentation and dispersion could be observed immediately. Each session lasted about 5 minutes. As a result of this treatment, the floaters moved progressively downwards or upwards, thereby clearing the optical axis.

The postoperative treatment consisted of the instillation of a non-steroidal anti-inflammatory drug, 3 times per day during one week.

The SLO was repeated one month post-operatively in order to evaluate the benefit of the treatment by looking at the changes in positions of the vitreous floaters with respect to the visual axis.

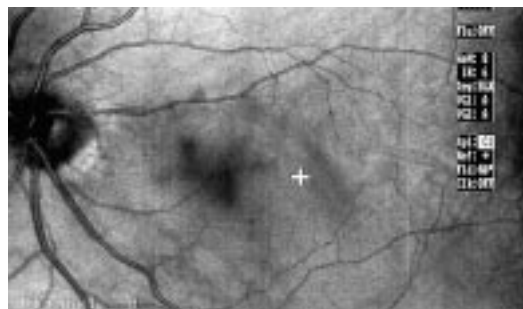
At the same time, the retina was examined to exclude any side effects due to the treatment. Follow-up period was at least one year for each patient.

RESULTS

Four patients (4 eyes) were treated for a single and well-suspended vitreous condensation. These patients were very satisfied after treatment. Three of the 4 patients did not show any signs of recurrence within the follow-up period of 12 months. Although the fourth patient had no complaints initially, he developed a recurrence of his subjective complaints 7 months later. His initially well-suspended floater had transformed into an ill-suspended type after treatment. Two additional laser treatments were performed, without success.

The other 6 eyes of this series were treated for ill-suspended floaters. The results in this group were clearly less satisfactory (fig 2b). Full efficacy of the treatment was observed in only one eye. It was the only patient from this study who

Fig 2b: Example of an unsuccessfully treated "ill-suspended" vitreous floater. Same case as fig 2a but after 2 sessions of YAG laser vitreolysis. The floater is smaller but still present in the visual axis.



had both eyes treated. The right eye had an ill-suspended floater which needed 2 sessions and the left eye had a well-suspended floaters which needed only one session. Three patients who did not respond well after treatment, underwent a vitrectomy. One of them had a macular pucker besides the vitreous condensations and had an initial visual acuity of 1/10. The other 3 patients did not ask for further treatment. No decrease of visual acuity was observed in any case.

In the 3 post-vitrectomy cases, visual acuity remained unchanged in one eye (10/10), improved by two lines in one eye, and improved by 4 lines in the pucker case.

No retinal complications were observed during this study period, no pressure rise was recorded.

DISCUSSION

Nd-YAG Laser has been frequently used in the anterior segment for different pathologies but only sporadically in the posterior segment. Results on animal (2,17) models or on human eyes have been published for the following diseases: diabetic retinopathy (7), occlusion of the central retinal vein or branch vein (7), neovascular membranes under the retinal pigment epithelium (7), vitreoretinal traction in diabetic retinopathy (3,9,13,21) or sickle cell retinopathy (8,10), vitreal cysts (19), cystoid macular edema (11), early stages of preretinal macular fibrosis, retropupillary membranes, ochre membranes (20,21), retinal breaks (7) or peripheral retinal degeneration, choroidal melanomas

(7), vitreous strands with attached retina or localized retinal detachment (3,6,9,12,13,17,21) and retinal detachment (3,12).

The use of Nd-YAG Laser for treatment of floaters was already described by Tsai et al (22) and Van der Veken et al (24). The treatment is non-invasive, performed on an outpatient basis and considered by several authors as effective, safe and innocuous (3,6,7,8,11,17,19,20,21,24) even in case vitrectomy is needed consecutively (7,12,20).

A few complications due to the use of the Nd-YAG Laser in the posterior segment of the eye have been reported: damage to the corneal endothelium, the lens (7,9,17), the artificial lens and the retina (2,10) causing retinal hemorrhage (7,9,13,23), rupture of retinal vessels (10), retinal breaks (9,23) or retinal detachment (13,21).

The ND-YAG Laser disruption is generated by two different physical mechanisms: the thermal effect causing tissue evaporation and the mechanical effect (25) causing shock waves. The shock waves (4,13) may cause complications such as retinal damage and even retinal detachment. The control of these complications depends on the energy levels used and on the distance from the target tissue and the neighbouring ocular structures.

If the energy levels used are too high, cavitation bubbles will be generated. These bubbles move into the vitreous cavity with a speed of 100 m/sec (17) and may cause microscopic retinal damage. The behaviour of the irradiance of these acoustic waves has been studied by Puliafito (17).

A safe distance between the target tissue and the neighbouring tissues has been estimated to be 2 to 5 mm (1,17,21). Because of their location, most often in the anterior vitreous or mid-vitreous, vitreous floaters can be treated with the Nd-YAG Laser while keeping a safe distance from the lens and from the retina. To enhance a better focusing of the Nd-YAG laser beam it is important to use a Goldmann three mirror contact lens for the floaters located in the posterior vitreous or the CGV contact lens of Rol for the vitreous floaters located in the anterior or mid-vitreous (7,16,18). The Goldmann three mirror contact lens has the disadvantage of a small convergence angle but offers the advantage of a high magnification allowing a good

visualisation of the vitreous structures to be treated (21,22).

When all previously mentioned precautions are kept in mind, the risk for complications is very low. In our series, no complications were recorded. This was also the case in the publication of Tsai et al. (22).

According to the Committee on Ophthalmic Procedures Assessment (15), considerations on risk versus benefit ratio must be kept in mind. The risk versus benefit ratio is low for Nd-YAG laser vitreolysis as compared to vitrectomy. Vitreous floaters causing severe visual impairment are few. In our practice, of more than 22.000 consultations per year, 10 cases occurred over a 2 year period. With scanning laser ophthalmoscopy, we were able to objectivate the degree of patient's discomfort in case the vitreous floaters were located very close to the fixation point or visual axis.

Different methods have been proposed to objectivate vitreous floaters including direct ophthalmoscopy (22) and images made through an El Bayadi-Kajiura lens (14). We propose the SLO to objectivate the size, the motility and the relation of the floaters with respect to the visual axis.

In our series, the overall success rate was only 50%, which even decreased to 40% in function of time. If we consider the well-suspended floaters only, the success rate is 84%. The success rate for ill-suspended floaters is only 16%. Tsai et al achieved a success rate of 100% (22).

A vitrectomy was asked by three patients after failure of the YAG-Laser treatment. Subjective and objective results were very good in all three cases.

CONCLUSION

Vitreous floaters are frequently found in daily practice and may occasionally cause important visual and psychological impairment. The Nd-YAG Laser is currently the most innocuous and least invasive technique for treating highly symptomatic floaters. Vitreolysis is successful in case of well-suspended condensations (84%). Ill-suspended floaters are associated with a low success rate (16%). If one or two laser sessions are unsuccessful, vitrectomy remains the only alternative.

REFERENCES

- (1) BENHAMOU N., GLACET-BERNARD A., LEMER Y., QUENTEL G., PERRENOUD T., COSCAS G., SOUBRANE G. – Décollement de rétine après tentative de section de brides vitréennes au laser YAG. *J Fr Ophtalmol* 1998; 21, 495-500.
- (2) BONNER R.F., MEYERS S.M., GAASTERLAND D.E. – Threshold for retinal damage associated with the use of high-power neodymium-YAG lasers in the vitreous. *Am J Ophthalmol* 1983; 96: 153-159.
- (3) BROWN G.C., BENSON W.E. – Treatment of diabetic traction retinal detachment with the pulsed neodymium-YAG Laser. *Am J Ophthalmol* 1985; 99: 258-262.
- (4) FASTENBERG D.M., SCHWARTZ P.L. – Retinal detachment following neodymium: YAG laser capsulotomy. *Am J Ophthalmol* 1984; 97: 288-291.
- (5) FOOS R.Y., WHEELER N.C. – Vitreoretinal junction. Synchysis senilis and posterior vitreous detachment. *Ophthalmology* 1982; 89: 1502-1512.
- (6) FRANKHAUSER F., KWASNIEWSKA S., VAN DER ZYPEN E. – Irradiation of the posterior ocular segment with the Neodymium-YAG Laser in its free-running mode. *Arch Ophthalmol* 1985; 103: 1406-1412.
- (7) FRANKHAUSER F., KWASNIEWSKA S., VAN DER ZYPEN E. – Vitreolysis with the Q-switched laser. *Arch Ophthalmol* 1985; 103: 1166-1171.
- (8) HRISOMALOS N.F., JAMPOL L.M., MORIARTY B.J., SERJEANT G., ACHESON R., GOLDBERG M.F. – Neodymium-YAG Laser Vitreolysis in Sickle Cell retinopathy. *Arch Ophthalmol* 1987; 105: 1087-1091.
- (9) JAGGER J.D., HAMILITO P., POLKINGHORNE P. – Q-switched neodymium YAG laser vitreolysis in the therapy of posterior segment disease. *Graef Arch Clin Exp Ophthalmol* 1990; 228: 222-225.
- (10) JAMPOL L.M., GOLDBERG M.F., JEDNOCK N. – Retinal damage from a Q-Switched YAG laser. *Am J Ophthalmol* 1983; 96: 326-329.
- (11) KATZEN L.E., FLEISCHMAN J.A., TROKEL S. – YAG laser treatment of cystoid macular edema. *Am J Ophthalmol* 1983; 95: 589-592.
- (12) KREISIG I., KUCK H., HAUSTRAETE F., FAHLE M. – Le laser YAG a t'il une place dans la chirurgie du segment postérieur de l'oeil? *Bull Soc belge Ophtalmol* 1987; 220: 23-41.
- (13) LITTLE H.L., JACK R.L. – YAG laser surgery of the vitreous. *Graef Arch Clin Exp Ophthalmol* 1986; 224: 240-246.
- (14) MURAKAMI K., JALKH A.E., AVILA M.P., TREMPPE C.L., SCHEPENS C.L. – Vitreous Floaters. *Ophthalmology* 1983; 90: 1271-1276.
- (15) Ophthalmic Procedures Assessment. – Nd: YAG-photodisruptors. *Ophthalmology*, 1993; 100: 1736-1741.
- (16) PEYMAN G.A. – Contact lenses for Nd:YAG application in the vitreous. *Retina* 1984; 4: 129-131.
- (17) PULIAFITO C.A., WASSON P.J., STEINERT R.F., GRADOUDAS E.S. – Neodymium-YAG laser surgery on experimental vitreous membranes. *Arch Ophthalmol* 1984; 102: 843-847.
- (18) ROL P., FRANKHAUSER F., KWASNIEWSKA S. – A new contact lens for posterior vitreous photodisruption. *Invest Ophthalmol Vis Sci* 1986; 27: 946-950.
- (19) RUBY A.J., JAMPOL L.M. – Nd: YAG treatment of a posterior vitreous cyst. *Am J Ophthalmol* 1990; 110: 428-429.
- (20) STEMPELS N., TASSIGNON M.J., BRIHAYE M. – Nd: YAG laser treatment of ochre membranes. *Bull Soc belge Ophtalmol* 1987; 223 (II): 47-52.
- (21) TASSIGNON M.J., KREISSIG I., STEMPELS N., BRIHAYE M. – Indication for Q-switched and mode-locked ND: YAG Laser in vitreoretinal pathology. *Eur J Ophthalmol*, 1991; 1: 123-130.
- (22) TSAI W.F., CHEN Y.C., SU C.Y. – Treatment of vitreous floaters with neodymium YAG laser. *Br J Ophthalmol* 1993; 77: 485-488.
- (23) TURUT P., MALTHIEU D., BRYSELBOUT E., BEGO B. – Section des brides vitréennes postérieures au laser YAG. *Bull Soc Ophtalmol Fr* 1987; 6-7: 815-818.
- (24) VAN DER VEKEN A., VAN DE VELDE F., SMEETS B., TASSIGNON M.J. – Nd: YAG laser posterior hyaloidotomy for the treatment of a premacular vitreous floater. *Bull Soc belge Ophtalmol* 1997; 265, 39-43.
- (25) VOGEL A., HENTSCHEL W., HOLZFUSS J., LAUTERBORN W. – Cavitation bubble dynamics and acoustic transient generation in ocular surgery with pulsed Neodymium: YAG-Laser. *Ophthalmology*, 1996; 93: 1259-1269.

.....

Corresponding address:
 Prof.dr.Marie-José Tassignon
 Dept.of Ophthalmology
 University Hospital Antwerp
 Wilrijkstraat 10
 B -2650 Edegem, Belgium
 tel. 00 32 3 821 33 77
 fax 00 32 3 825 19 26
 e-mail: oftalmo@uia.ua.ac.be

d414

d221

d874