
PRESUMED OPTIC NERVE SHEATH MENINGIOMA DIAGNOSED AFTER COMPLICATED RETROBULBAR ANESTHESIA

NOË P.*, **, BAARSMA G.S.**,
PARIDAENS D.**

SUMMARY

We present a patient who developed acute visual loss and light flashes at retrobulbar anesthesia for cataract extraction. Vision improved only slightly after cataract surgery. Although traumatic optic neuropathy was suspected, the patient was diagnosed one year later with an optic nerve sheath meningioma (ONSM).

ONSM is a rare, slow growing, benign tumour with highly variable clinical features. Diagnosis is often delayed. This case report demonstrates the diagnostic difficulty of this tumour.

SAMENVATTING

We stellen een patiënt voor die een acute visusdaling en lichtflitsen ondervond bij retrobulbare anesthesie bij cataractoperatie. De visus verbeterde slechts weinig na de cataractoperatie. Aanvankelijk werd een traumatische opticus neuropathie vermoed. Een jaar later werd de diagnose van nervus opticus meningioom gesteld. Dit is een zeldzame, traag groeiende, goedaardige tumor met zeer variabele klinische verschijningsvormen. Deze casus illustreert dat de - vaak laatgestelde - diagnose van deze tumor problematisch kan zijn.

RÉSUMÉ

Nous rapportons le cas d'un patient qui présentait une baisse de la vision et des photopsies lors d'une anesthésie rétrobulbaire pour opération de cataracte. Il y avait seulement une faible amélioration de la vision après l'opération de la cataracte. Contrairement au diagnostic initial de neuropathie optique traumatique, un méningiome des gaines du nerf optique (MGNO) a été diagnostiqué après un an. Le MGNO est une tumeur bénigne, rare, d'évolution lente, dont les signes cliniques sont aspécifiques et dont le diagnostic est rarement précoce. Notre cas démontre les difficultés diagnostiques que pose cette tumeur.

KEY WORDS:

Retrobulbar anesthesia, optic nerve sheath meningioma, stereotactic radiotherapy.

MOTS-CLÉS:

Anesthésie rétrobulbaire, méningiome des gaines du nerf optique, radiothérapie stéréotactique.

.....

* Dept of Ophthalmology, Ghent University Hospital, Belgium.

** The Rotterdam Eye Hospital, The Netherlands.

received: 08.02.04

accepted: 08.05.04

CASE REPORT

A 65-years-old healthy man presented to his ophthalmologist in February 2000 with complaints of blurred vision of the right eye. His best corrected visual acuity (VA) was 0.6 at the right and 0.9 at the left eye. Automatic static perimetry (Humphrey Field Analyzer program 30-2) showed a temporal scotoma (figure 1). The visual loss of the right eye was attributed to cataract. The best-corrected VA of the right eye deteriorated to 0.2 and a cataract extraction by phaco-emulsification was performed in June 2001. Two retrobulbar xylocaine 2% injections were required to obtain adequate anesthesia. At the second retrobulbar injection, a periocular haemorrhage developed and the patient experienced flashes and acute visual loss of the right eye. The subsequent phaco-emulsification was uneventful. The postoperative best-corrected VA was 0.4, the optic nerve head was mildly swollen and the temporal visual field defect was still present (figure 1). From these findings the ophthalmologist concluded that the retrobulbar injection had induced an ischemic optic neuropathy.

The patient was referred to us in July 2002 for a second opinion. Examination revealed a right relative afferent pupillary defect, 4 mm of proptosis of the right eye, but no oculomotor disturbances. Fundus examination and fluorescein angiography of the right eye showed still a mildly swollen optic nerve head, but no cho-

roidal folds nor optociliary shunt vessels. Visual evoked potentials (VEP) showed decreased amplitudes and increased latency at the right eye. Orbital color-doppler ultrasound imaging demonstrated a normal blood-flow in the right central retinal and ophthalmic artery and a slight prominence of the optic disc. An orbital computed tomographic scan (CT) with infusion of contrast-medium showed a 13 mm long tumour arising from the optic nerve sheath, localized in the orbital apex, around and medially of the optic nerve. A tram-track-sign was seen in the homogeneously staining lesion. No tumour extension into the optic canal or intracranially nor bone involvement was noted (figure 2). Magnetic resonance imaging (MRI) with gadolinium confirmed CT-findings. The tumour had an isointense appearance to the optic nerve and brain tissue on T1-weighted and T2-weighted MR images. The patient was diagnosed clinically with a presumed primary ONSM. Because of further progression of the visual field defects (figure 1) and development of mild orbital pain, the patient underwent stereotactic radiotherapy (SRT) in December 2002 and January 2003. Four months later, best corrected visual acuity of the right eye was 0.5 and there was a marked regression of the visual field defects (figure 1).

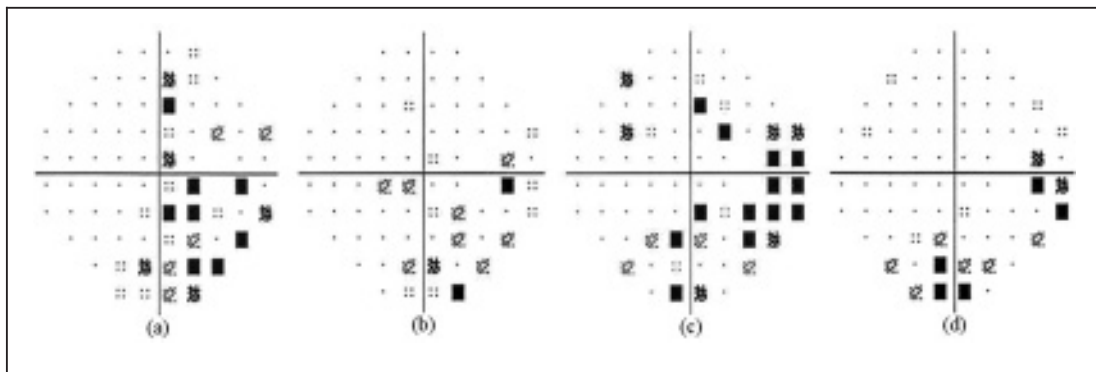


Fig 1. Automated static perimetry (Humphrey Field Analyzer program 30-2, pattern deviation) of the right eye, (a) at presentation in February 2000, (b) postoperatively in August 2001, (c) in October 2002 and (d) after SRT in May 2003. (a), (b) and (c) show evolution of the general sensitivity reduction and the temporal scotoma. (d) shows a marked regression of these visual field defects after SRT. Mean deviation was respectively -5.94dB, -6.45dB, -9.65dB and -5.55dB.

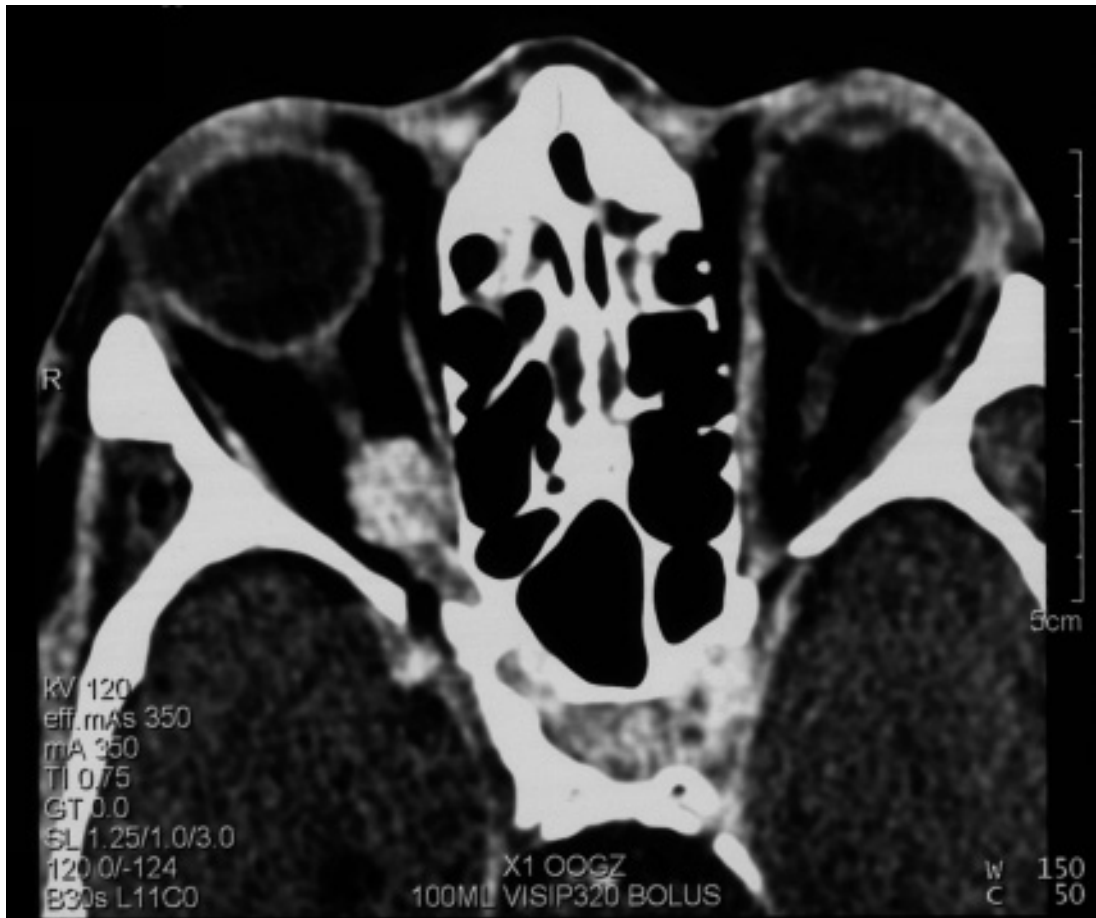


Fig 2. Axial orbital CT scan of September 2002 showing the ONSM, localized in the orbital apex, around and medially of the optic nerve. Note the typical tram-track sign. There is no intracranial extension of the tumour nor bone involvement.

DISCUSSION

This case illustrates that ONSM and other retrobulbar tumours should be considered in the differential diagnosis of unilateral blurred vision, also in patients with cataracts. Clinical features of ONSM are highly variable. They comprise gradual visual acuity loss, transient visual obscurations, mild proptosis, oculomotor disturbances and peri- and retro-orbital pain. A relative afferent pupillary defect (RAPD), optic disc edema or atrophy, optociliary shunt vessels, choroidal folds, dyschromatopsia and visual field defects should rise suspicion (3). Retrospectively, the temporal scotoma in the right visual field, the RAPD, the optic disc oedema

and the proptosis should have alarmed the patient's ophthalmologist for the possibility of an optic nerve tumour. In our case, the diagnosis was primarily based upon the CT imaging findings. ONSM often shows homogeneous and well-defined contrast enhancement and appears as a well-defined, tubular thickening of the optic nerve, often at the orbital apex. Because the ONSM surrounds the optic nerve, the caliber of the nerve itself is attenuated (figure 2). This is in contrast to optic nerve gliomas, where the nerve itself appears expanded. The tram-track-sign, which is the lucency of the optic nerve in the center of an enlarged and enhanced tumour, is very suggestive of an ONSM, although it has also been seen in CT scans of

pseudo-tumours, optic nerve lymphoma and optic neuritis (6). A biopsy, which is hazardous in this region, has not been performed as there was enough clinical evidence for an ONSM. The flashes and sudden visual loss at the retrolubar anesthesia were most probably due to a pressure effect on compromised optic nerve vessels and fibers.

Although ONSM does not cause death nor significant neurological morbidity, it can cause complete blindness of the affected eye. Preservation of visual function is the main therapeutic goal (7). Because some patients may have a stable course for many years, observation is a reasonable option until visual function declines (4). Because of frequent postoperative blindness, surgery has been abandoned as treatment option except for late-stage-ONSM-patients who have developed blindness, severe ptosis or intracranial involvement (3). On the basis of recent publications, stereotactic radiotherapy (SRT) may prove to be the treatment of choice for both early and late stages of ONSM (1, 2, 5, 7, 8 - 10).

REFERENCES

- (1) ANDREWS D.W., FAROOZAN R., YANG B.P., HUDES R.S., WERNER-WASIK M., KIM S.M., SERGOTT R.C., SAVINO P.J., SHIELDS C., DOWNES M.B., SIMEONE F.A., GOLDMAN H.W., CURRAN W.J. Jr. – Fractionated stereotactic radiotherapy for the treatment of optic nerve sheath meningiomas: preliminary observations of 33 optic nerves in 30 patients with historical comparison to observation with or without prior surgery. *Neurosurgery* 2002; 51: 890-920.
- (2) BECKER G., JEREMIC B., PITZ S., BUCHGEISTER M., WILHELM H., SCHIEFER U., PAULSEN F., ZRENNER E., BAMBERG M. – Stereotactic fractionated radiotherapy in patients with optic nerve sheath meningioma. *Int J Radiat Oncol Biol Phys* 2002; 54: 1422-1429.
- (3) DUTTON J.J. – Optic nerve sheath meningiomas. *Surv Ophthalmol* 1992; 37: 167-183.
- (4) EGAN R.A., LESSELL S. – A contribution to the natural history of optic nerve sheath meningiomas. *Arch Ophthalmol* 2002; 120: 1505-1508.
- (5) LIU J.K., FORMAN S., HERSHEWE G.L., MOORTHY C.R., BENZIL D.L. – Optic nerve sheath meningiomas: visual improvement after stereotactic radiotherapy. *Neurosurgery* 2002; 50: 950-955.
- (6) MAFEE M.F., GOODWIN J., DORODI S. – Optic nerve sheath meningiomas, role of MR imaging. *Radiol Clin North Am* 1999; 37:37-58.
- (7) MILLER N.R. – Radiation for optic nerve meningiomas: is this the answer? *Ophthalmology* 2002; 109: 833-834.
- (8) PARIDAENS A.D., VAN RUYVEN R.L., EIJKENBOOM W.M., MOOY C.M., VAN DEN BOSCH W.A. – Stereotactic irradiation of biopsy proven optic nerve sheath meningioma. *Br J Ophthalmol* 2003; 87: 246-247.
- (9) PITZ S., BECKER G., SHIEFER U., WILHELM H., JEREMIC B., BAMBERG M., ZRENNER E. – Stereotactic fractionated irradiation of optic nerve sheath meningioma: a new treatment alternative. *Br J Ophthalmol* 2002; 86: 1265-1268.
- (10) TURBIN R.E., THOMPSON C.R., KENNERDELL J.S., COCKERHAM K.P., KUPERSMITH M.J. – A long-term visual outcome comparison in patients with optic nerve sheath meningioma managed with observation, surgery, radiation, or surgery and radiotherapy. *Ophthalmology* 2002; 109: 890-900.

.....

Correspondence to:
Dr. P. Noë
Universitair Ziekenhuis
Dienst Oogheelkunde
De Pintelaan 185
B-9000 Gent
Belgium